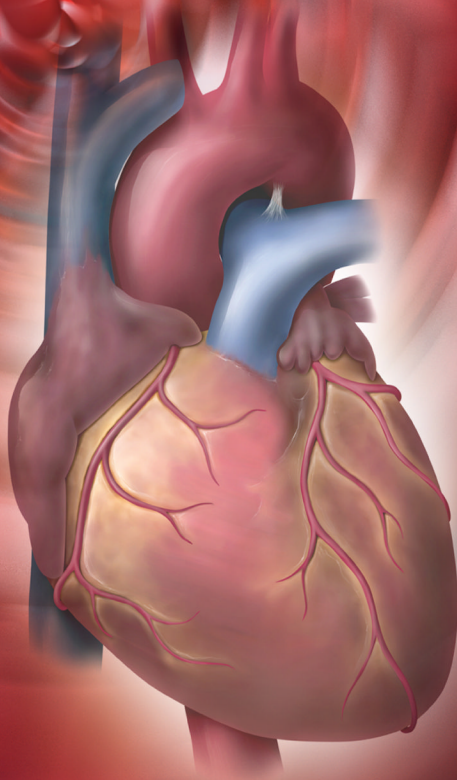




ECG Made Easy[®]

4th Edition

Atul Luthra



JAYPEE

ECG Made Easy

ECG Made Easy

Fourth Edition

Atul Luthra

MBBS MD DNB

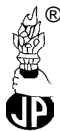Diplomate

National Board of Medicine

Physician and Cardiologist

Delhi, India

www.atulluthra.in



**JAYPEE BROTHERS MEDICAL
PUBLISHERS (P) LTD**

New Delhi • Panama City • London



Jaypee Brothers Medical Publishers (P) Ltd.

Headquarter

Jaypee Brothers Medical Publishers (P) Ltd
4838/24, Ansari Road, Daryaganj
New Delhi 110 002, India
Phone: +91-11-43574357
Fax: +91-11-43574314
Email: jaypee@jaypeebrothers.com

Overseas Offices

J.P. Medical Ltd.,
83 Victoria Street London
SW1H 0HW (UK)
Phone: +44-2031708910
Fax: +02-03-0086180
Email: info@jpmedpub.com

Jaypee-Highlights Medical Publishers Inc.
City of Knowledge, Bld. 237, Clayton
Panama City, Panama
Phone: 507-317-0160
Fax: +50-73-010499
Email: cservice@jphmedical.com

Website: www.jaypeebrothers.com

Website: www.jaypeedigital.com

© 2012, Jaypee Brothers Medical Publishers

All rights reserved. No part of this book may be reproduced in any form or by any means without the prior permission of the publisher.

Inquiries for bulk sales may be solicited at: jaypee@jaypeebrothers.com

This book has been published in good faith that the contents provided by the author contained herein are original, and is intended for educational purposes only. While every effort is made to ensure accuracy of information, the publisher and the author specifically disclaim any damage, liability, or loss incurred, directly or indirectly, from the use or application of any of the contents of this work. If not specifically stated, all figures and tables are courtesy of the author. Where appropriate, the readers should consult with a specialist or contact the manufacturer of the drug or device.

ECG Made Easy®

First Edition : 1998
Second Edition : 2004
Third Edition : 2007
Fourth Edition : **2012**

ISBN 978-93-5025-591-9

Printed at

To
My Parents
Ms Prem Luthra
and
Mr Prem Luthra
Who guide and bless me
from heaven

PREFACE

The imaging techniques of contemporary 'high-tech' cardiology have failed to eclipse the primacy of the 12-lead ECG in the initial evaluation of heart disease. This simple, cost-effective and readily available diagnostic modality continues to intrigue and baffle the clinician as much as it confuses the student. A colossal volume of literature on understanding ECG bears testimony to this fact.

This book is yet another humble attempt to bring the subject of ECG closer to the hearts of students and clinicians in a simple and concise form. As the chapters unfold, the subject gradually evolves from basics to therapeutics. Although emphasis is on ECG diagnosis, causation of abnormalities and their clinical relevance are briefly mentioned too. This should help students preparing for their examinations without having to search through voluminous textbooks.

While some arrhythmias are harmless, others are ominous and life-threatening. The clinical challenge lies in knowing the cause of an arrhythmia, its significance, differential diagnosis and practical aspects of management. Therefore, seemingly similar cardiac rhythms are discussed together under individual chapter headings. Medical students, resident doctors, nurses and technicians will find this format particularly useful.

I have thoroughly enjoyed the experience of writing this book and found teaching as pleasurable as learning. Since the scope for further refinement always remains, it is a privilege to bring out the vastly improved 4th edition of *ECG Made Easy*. Your appreciation, comments and criticisms are bound to spur me on even further.

Atul Luthra

ACKNOWLEDGMENTS

I am extremely grateful to:

- My school teachers who helped me to acquire good command over the English language.
- My professors at medical college who taught me the science and art of clinical medicine.
- My heart patients whose cardiograms stimulated my grey matter to make me wiser.
- Authors of books on electrocardiography to which I referred liberally, while preparing the manuscript.
- My readers whose generous appreciation, candid comments and constructive criticism spur me on.
- M/s Jaypee Brothers Medical Publishers (P) Ltd who repose their unflinching faith in me and provide moral encouragement along with expert editorial assistance.

CONTENTS

1. Nomenclature of ECG Deflections	1
The Electrocardiogram	1
The Electrophysiology	5
The Deflections	9
The Intervals	12
The Segments	13
2. Electrocardiographic Leads	15
The Electrocardiographic Leads	15
The Limb Leads	15
The Chest Leads	19
The Lead Orientation	20
The Einthoven Triangle	21
3. ECG Grid and Normal Values	23
The ECG Grid	23
The Normal ECG Values	24
4. Determination of Electrical Axis	33
The Electrical Axis	33
The Hexaxial System	33
The QRS Axis	34
Determination of QRS Axis	36
Abnormalities of QRS Axis	38
5. Determination of the Heart Rate	40
The Heart Rate	40
The Heart Rhythm	43

xii ECG Made Easy

6. Abnormalities of the P Wave	53
Normal P Wave	53
Absent P Wave	53
Inverted P Wave	54
Changing P Wave Morphology	54
Tall P Wave	55
Broad P Wave	56
7. Abnormalities of QRS Complex	59
Normal QRS Complex	59
Low-Voltage QRS Complex	60
Alternating QRS Voltage	61
Abnormal QRS Axis	62
Fascicular Block or Hemiblock	65
Non-Progression of R Wave	67
Abnormal Q Waves	69
Abnormally Tall R Waves	71
Abnormally Deep S Waves	77
Abnormally Wide QRS Complexes	78
8. Abnormalities of the T Wave	87
Normal T Wave	87
Inverted T Wave	87
Tall T Wave	96
9. Abnormalities of the U Wave	100
Normal U Wave	100
Prominent U Wave	100
Inverted U Wave	101
10. Abnormalities of P-R Segment	103
P-R Segment Depression	103
11. Abnormalities of S-T Segment	105
S-T Segment Depression	105
S-T Segment Elevation	111
12. Abnormalities of P-R Interval	118
Normal P-R Interval	118
Prolonged P-R Interval	119
Shortened P-R Interval	120

13. Abnormalities of Q-T Interval	124
Normal Q-T Interval	124
Shortened Q-T Interval	125
Prolonged Q-T Interval	126
14. Premature Beats in Regular Rhythm	129
Premature Beats	129
Atrial Premature Complex	129
Junctional Premature Complex	131
Ventricular Premature Complex	131
15. Pauses During Regular Rhythm	142
Pauses During Rhythm	142
Pause After Premature Beat	142
Pause After Blocked Premature Beat	143
Pause Due to Sinoatrial Block	143
Pause Due to Atrioventricular Block	145
16. Fast Regular Rhythm with Narrow QRS	153
Regular Fast Rhythm	153
Sinus Tachycardia	153
Atrial Tachycardia	154
Atrial Flutter	158
17. Normal Regular Rhythm with Narrow QRS	168
Regular Normal Rhythm	168
Normal Sinus Rhythm	168
Atrial Tachycardia with 2:1 A-V Block	168
Atrial Flutter with 4:1 A-V Block	169
Junctional Tachycardia	169
18. Fast Irregular Rhythm with Narrow QRS	174
Irregular Fast Rhythm	174
Atrial Tachycardia with A-V Block	174
Atrial Flutter with Varying A-V Block	175
Multifocal Atrial Tachycardia	175
Atrial Fibrillation	176

xiv ECG Made Easy

- 19. Fast Regular Rhythm with Wide QRS** **184**
Fast Wide QRS Rhythm 184
Ventricular Tachycardia 184
Supraventricular Tachycardia with Aberrant
Ventricular Conduction 187
Supraventricular Tachycardia with Pre-existing
QRS Abnormality 188
- 20. Normal Regular Rhythm with Wide QRS** **195**
Normal Wide QRS Rhythm 195
Accelerated Idioventricular Rhythm 195
- 21. Fast Irregular Rhythm with Bizarre QRS** **199**
Irregular Wide QRS Rhythm 199
Ventricular Flutter 199
Ventricular Fibrillation 200
- 22. Slow Regular Rhythm with Narrow QRS** **206**
Regular Slow Rhythm 206
Sinus Bradycardia 207
Junctional Escape Rhythm 208
Sinus Rhythm with 2:1 S-A Block 209
Sinus Rhythm with 2:1 A-V Block 210
Blocked Atrial Ectopics in Bigeminy 210
- 23. Slow Irregular Rhythm with Narrow QRS** **214**
Irregular Slow Rhythm 214
Sinus Arrhythmia 214
Wandering Pacemaker Rhythm 215
Sinus Rhythm with Varying S-A Block 216
Sinus Rhythm with Varying A-V Block 217
- 24. Slow Regular Rhythm with Wide QRS** **220**
Slow Wide QRS Rhythm 220
Complete A-V Block 220
Complete S-A Block 222
External Pacemaker Rhythm 223
Slow Rhythm with Existing Wide QRS 224

1

Nomenclature of ECG Deflections

THE ELECTROCARDIOGRAM

The electrocardiogram (ECG) provides a graphic depiction of the electrical forces generated by the heart. The ECG graph appears as a series of deflections and waves produced by each cardiac cycle.

Before going on to the genesis of individual deflections and their terminology, it would be worthwhile mentioning certain important facts about the direction and magnitude of ECG waves and the activation pattern of myocardium.

Direction

- ❖ By convention, a deflection above the baseline or isoelectric (neutral) line is a positive deflection while one below the isoelectric line is a negative deflection (**Fig. 1.1A**).

The direction of a deflection depends upon two factors namely, the direction of spread of the electrical force and the location of the recording electrode.

In other words, an electrical impulse moving towards an electrode creates a positive deflection while an impulse moving away from an electrode creates a negative deflection (**Fig. 1.1B**). Let us see this example.

We know that the sequence of electrical activation is such that the interventricular septum is first activated from left to right followed by activation of the left ventricular free wall from the endocardial to epicardial surface.

2 ECG Made Easy

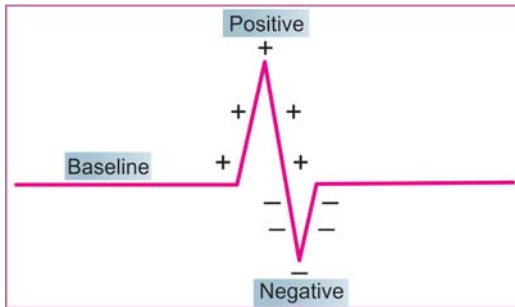


Fig. 1.1A: Direction of the deflection on ECG:
A. Above the baseline: positive deflection
B. Below the baseline: negative deflection

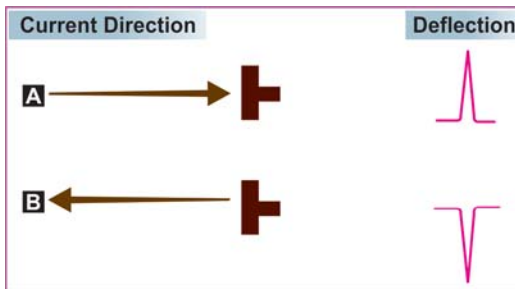


Fig. 1.1B: Effect of current direction on polarity of deflection:
A. Towards the electrode—upright deflection
B. Away from electrode—inverted deflection

If an electrode is placed over the right ventricle, it records an initial positive deflection representing septal activation towards it, followed by a major negative deflection that denotes free wall activation away from it (**Fig. 1.2**).

If, however, the electrode is placed over the left ventricle, it records an initial negative deflection representing septal

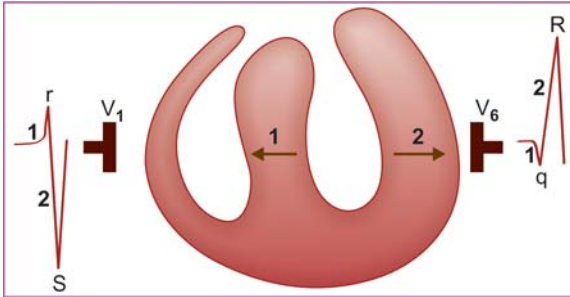


Fig. 1.2: Septal (1) and left ventricular (2) activation viewed from:
 lead V_1 (rS pattern)
 lead V_6 (qR pattern)

activation away from it, followed by a major positive deflection that denotes free wall activation towards it (**Fig. 1.2**).

Magnitude

- ❖ The height of a positive deflection and the depth of a negative deflection are measured vertically from the baseline. This vertical amplitude of the deflection is a measure of its voltage in millimeters (**Fig. 1.3A**).
- ❖ The magnitude of a deflection depends upon the quantum of the electrical forces generated by the heart and the extent to which they are transmitted to the recording electrode on the body surface. Let us see these examples:

Since the ventricle has a far greater muscle mass than the atrium, ventricular complexes are larger than atrial complexes.

When the ventricular wall undergoes thickening (hypertrophy), the ventricular complexes are larger than normal.

If the chest wall is thick, the ventricular complexes are smaller than normal since the fat or muscle intervenes between the myocardium and the recording electrode (**Fig. 1.3B**).

4 ECG Made Easy

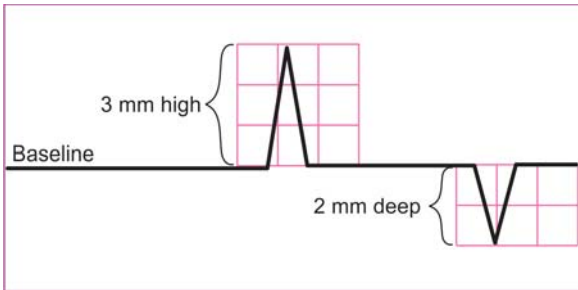


Fig. 1.3A: Magnitude of the deflection on ECG:
A. Positive deflection: height
B. Negative deflection: depth

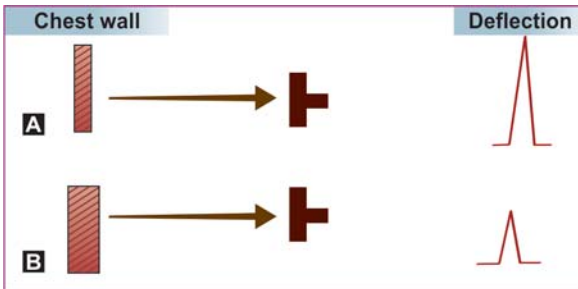


Fig. 1.3B: Effect of chest wall on magnitude of deflection:
A. Thin chest—tall deflection
B. Thick chest—small deflection

Activation

- ❖ Activation of the atria occurs longitudinally by contiguous spread of electrical forces from one myocyte to the other. On the other hand, activation of the ventricles occurs transversely by spread of electrical forces from the endocardial surface (surface facing ventricular cavity) to the epicardial surface (outer surface) (**Fig. 1.4**).

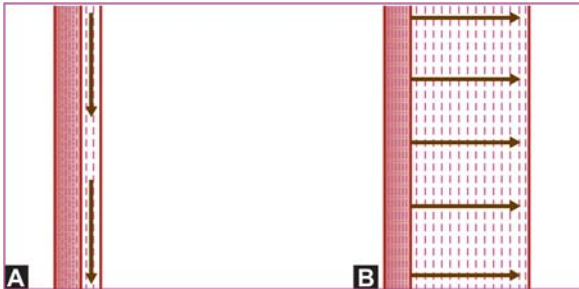


Fig. 1.4: Direction of myocardial activation in atrium and ventricle:
 A. Atrial muscle: longitudinal, from one myocyte to other
 B. Ventricular: transverse, endocardium to epicardium

Therefore, atrial activation can reflect atrial enlargement (and not atrial hypertrophy) while ventricular activation can reflect ventricular hypertrophy (and not ventricular enlargement).

THE ELECTROPHYSIOLOGY

The ECG graph consists of a series of deflections or waves. The distances between sequential waves on the time axis are termed as intervals. Portions of the isoelectric line (base-line) between successive waves are termed as segments.

In order to understand the genesis of deflections and the significance of intervals and segments, it would be worthwhile understanding certain basic electrophysiological principles.

- ❖ Anatomically speaking, the heart is a four-chambered organ. But in the electrophysiological sense, it is actually two-chambered. As per the “dual-chamber” concept, the chambers of the heart are the bi-atrial chamber and the bi-ventricular chamber (**Fig. 1.5**).

This is because the atria are activated together and the ventricles too contract synchronously. Therefore, on the ECG,

6 ECG Made Easy

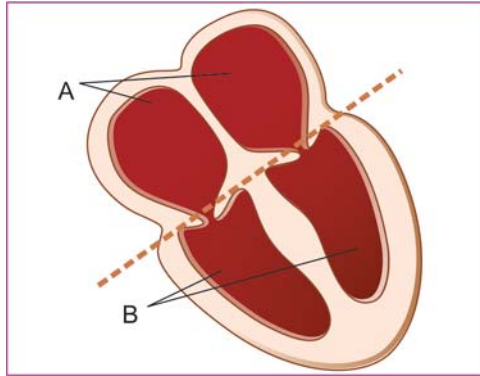


Fig. 1.5: The “dual-chamber” concept:
A. Biatrial chamber
B. Biventricular chamber

atrial activation is represented by a single wave and ventricular activation by a single wave-complex.

- ❖ In the resting state, the myocyte membrane bears a negative charge on the inner side. When stimulated by an electrical impulse, the charge is altered by an influx of calcium ions across the cell membrane.

This results in coupling of actin and myosin filaments and muscle contraction. The spread of electrical impulse through the myocardium is known as depolarization (**Fig. 1.6**).

Once the muscle contraction is completed, there is efflux of potassium ions, in order to restore the resting state of the cell membrane. This results in uncoupling of actin and myosin filaments and muscle relaxation. The return of the myocardium to its resting electrical state is known as repolarization (**Fig. 1.6**).

Depolarization and repolarization occur in the atrial muscle as well as in the ventricular myocardium. The wave of excitation is synchronized so that the atria and the ventricles contract and relax in a rhythmic sequence.

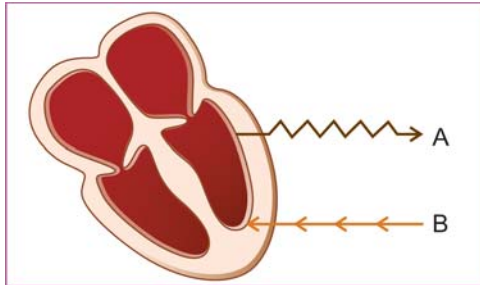


Fig. 1.6: The spread of impulse:
 A. Depolarization
 B. Repolarization

Atrial depolarization is followed by atrial repolarization which is nearly synchronous with ventricular depolarization and finally ventricular repolarization occurs.

We must appreciate that depolarization and repolarization of the heart muscle are electrical events, while cardiac contraction (systole) and relaxation (diastole) constitute mechanical events.

However, it is true that depolarization just precedes systole and repolarization is immediately followed by diastole.

- ❖ The electrical impulse that initiates myocardial depolarization and contraction originates from a group of cells that comprise the pacemaker of the heart.

The normal pacemaker is the sinoatrial (SA) node, situated in the upper portion of the right atrium (**Fig. 1.7**).

From the SA node, the electrical impulse spreads to the right atrium through three intra-atrial pathways while the Bachmann's bundle carries the impulse to the left atrium.

Having activated the atria, the impulse enters the atrioventricular (AV) node situated at the AV junction, on the lower part of the inter-atrial septum. The brief delay of the impulse at the AV node allows time for the atria to empty the blood they contain into their respective ventricles.

8 ECG Made Easy

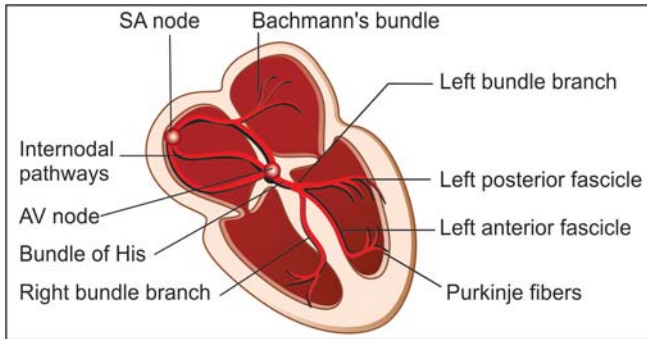


Fig. 1.7: The electrical 'wiring' network of the heart

After the AV nodal delay, the impulse travels to the ventricles through a specialized conduction system called the bundle of His. The His bundle primarily divides into two bundle branches, a right bundle branch (RBB) which traverses the right ventricle and a left bundle branch (LBB) that traverses the left ventricle (**Fig. 1.7**).

A small septal branch originates from the left bundle branch to activate the interventricular septum from left to right. The left bundle branch further divides into a left posterior fascicle and a left anterior fascicle.

The posterior fascicle is a broad band of fibers which spreads over the posterior and inferior surfaces of the left ventricle. The anterior fascicle is a narrow band of fibers which spreads over the anterior and superior surfaces of the left ventricle (**Fig. 1.7**).

Having traversed the bundle branches, the impulse finally passes into their terminal ramifications called Purkinje fibers. These Purkinje fibres traverse the thickness of the myocardium to activate the entire myocardial mass from the endocardial surface to the epicardial surface.

THE DEFLECTIONS

The ECG graph consists of a series of deflections or waves. Each electrocardiographic deflection has been arbitrarily assigned a letter of the alphabet. Accordingly, a sequence of wave that represents a single cardiac cycle is sequentially termed as P Q R S T and U (**Fig. 1.8A**).

By convention, P, T and U waves are always denoted by capital letters while the Q, R and S waves can be represented by either a capital letter or a small letter depending upon their relative or absolute magnitude. Large waves (over 5 mm) are assigned capital letters Q, R and S while small waves (under 5 mm) are assigned small letters q, r and s.

The entire QRS complex is viewed as one unit, since it represents ventricular depolarization. The positive deflection is always called the R wave. The negative deflection before the R wave is the Q wave while the negative deflection after the R wave is the S wave (**Fig. 1.8B**).

Relatively speaking, a small q followed by a tall R is labelled as qR complex while a large Q followed by a small r is labelled as

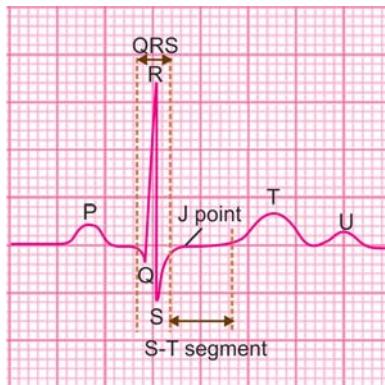


Fig. 1.8A: The normal ECG deflections

10 ECG Made Easy

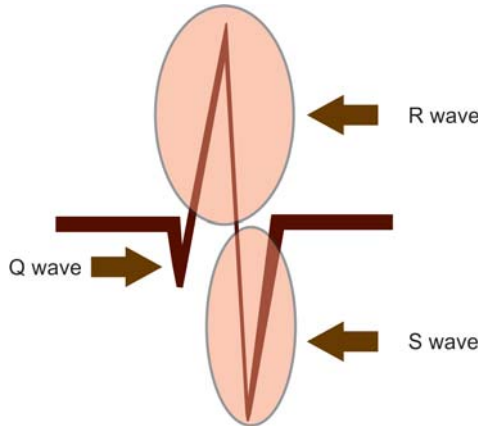


Fig. 1.8B: The QRS complex is one unit
Q wave: before R wave
S wave: after R wave

Qr complex. Similarly, a small r followed by a deep S is termed as rS complex while a tall R followed by a small s is termed as Rs complex (**Fig. 1.9**).

Two other situations are worth mentioning. If a QRS deflection is totally negative without an ensuing positivity, it is termed as a QS complex.

Secondly, if the QRS complex reflects two positive waves, the second positive wave is termed as R' and accordingly, the complex is termed as rSR' or RsR' depending upon magnitude of the positive (r or R) wave and the negative (s or S) wave (**Fig. 1.9**).

Significance of ECG Deflections

P wave : Produced by atrial depolarization.

QRS complex : Produced by ventricular depolarization.
It consists of:

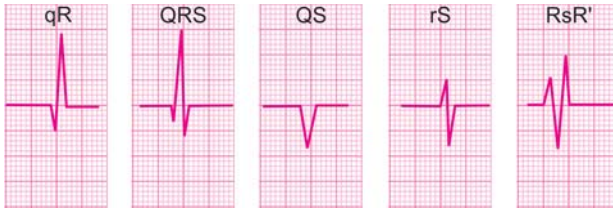

Fig. 1.9: Various configurations of the QRS complex

- Q wave : First negative deflection before R wave.
 - R wave : First positive deflection after Q wave.
 - S wave : First negative deflection after R wave.
 - T wave : Produced by ventricular repolarization.
 - U wave : Produced by Purkinje repolarization (**Fig. 1.10**).
- Within ventricular repolarization, the S-T segment is the plateau phase and the T wave is the rapid phase.

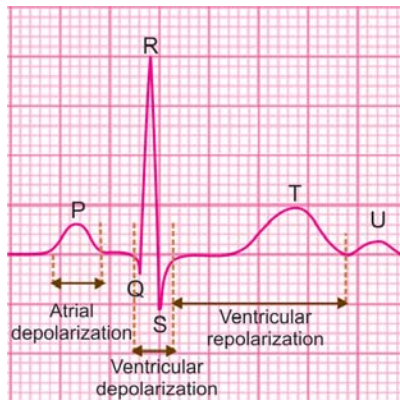


Fig. 1.10: Depolarization and repolarization depicted as deflections. (Note: Atrial repolarization is buried in the QRS complex)

12 ECG Made Easy

You would be wondering where is atrial repolarization. Well, it is represented by the Ta wave which occurs just after the P wave. The Ta wave is generally not seen on the ECG as it coincides with (lies buried in) the larger QRS complex.

THE INTERVALS

During analysis of an ECG graph, the distances between certain waves are relevant in order to establish a temporal relationship between sequential events during a cardiac cycle. Since the distance between waves is expressed on a time axis, these distances are termed as ECG intervals. The following ECG intervals are clinically important.

P-R Interval

The P-R interval is measured from the onset of the P wave to the beginning of the QRS complex (**Fig. 1.11**). Although the term P-R interval is in vogue, actually, P-Q interval would be more appropriate. Note that the duration of the P wave is included in the measurement.

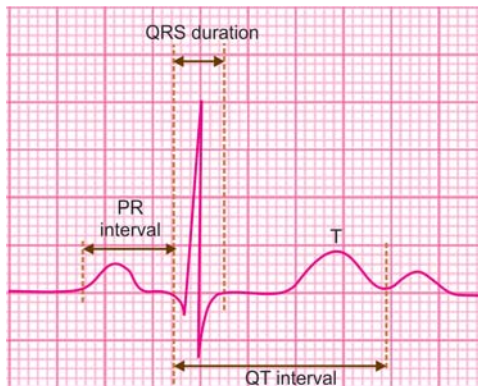


Fig. 1.11: The normal ECG intervals

We know that the P wave represents atrial depolarization while the QRS complex represents ventricular depolarization. Therefore, it is easy to comprehend that the P-R interval is an expression of atrioventricular conduction time.

This includes the time for atrial depolarization, conduction delay in the AV node and the time required for the impulse to traverse the ventricular conduction system before ventricular depolarization ensues.

Q-T Interval

The Q-T interval is measured from the onset of the Q wave to the end of the T wave (**Fig. 1.11**). If it is measured to the end of the U wave, it is termed Q-U interval. Note that the duration of the QRS complex, the length of the ST segment and the duration of the T wave are included in the measurement.

We know that the QRS complex represents ventricular depolarization while the T wave represents ventricular repolarization. Therefore, it is easy to comprehend that the Q-T interval is an expression of total duration of ventricular systole.

Since the U wave represents Purkinje system repolarization, the Q-U interval in addition, takes into account the time taken for the ventricular Purkinje system to repolarize.

THE SEGMENTS

The magnitude and direction of an ECG deflection is expressed in relation to a base-line which is referred to as the isoelectric line. The main isoelectric line is the period of electrical inactivity that intervenes between successive cardiac cycles during which no deflections are observed.

It lies between the termination of the T wave (or U wave if seen) of one cardiac cycle and onset of the P wave of the next cardiac cycle. However, two other segments of the isoelectric line, that occur between the waves of a single cardiac cycle, are clinically important.

14 ECG Made Easy

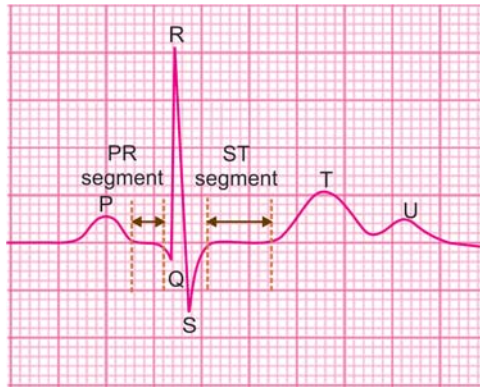


Fig. 1.12: The normal ECG segments

P-R Segment

The P-R segment is that portion of the isoelectric line which intervenes between the termination of the P wave and the onset of the QRS complex (**Fig. 1.12**). It represents conduction delay in the atrioventricular node. Note carefully that the length of the P-R segment does not include the width of the P wave while the duration of the P-R interval does include the P wave width.

S-T Segment

The S-T segment is that portion of the isoelectric line which intervenes between the termination of the S wave and the onset of the T wave (**Fig. 1.12**). It represents the plateau phase of ventricular repolarization. The point at which the QRS complex ends and the ST segment begins is termed the junction point or J point.

2

Electrocardiographic Leads

THE ELECTROCARDIOGRAPHIC LEADS

During activation of the myocardium, electrical forces or action potentials are propagated in various directions. These electrical forces can be picked up from the surface of the body by means of electrodes and recorded in the form of an electrocardiogram.

A pair of electrodes, that consists of a positive and a negative electrode constitutes an electrocardiographic lead. Each lead is oriented to record electrical forces as viewed from one aspect of the heart.

The position of these electrodes can be changed so that different leads are obtained. The angle of electrical activity recorded changes with each lead. Several angles of recording provide a detailed perspective the heart.

There are twelve conventional ECG lead placements that constitute the routine 12-lead ECG (**Fig. 2.1**).

The 12 ECG leads are:

- ❖ Limb leads or extremity leads—six in number.
- ❖ Chest leads or precordial leads—six in number.

THE LIMB LEADS

The limb leads are derived from electrodes placed on the limbs. An electrode is placed on each of the three limbs namely right

16 ECG Made Easy

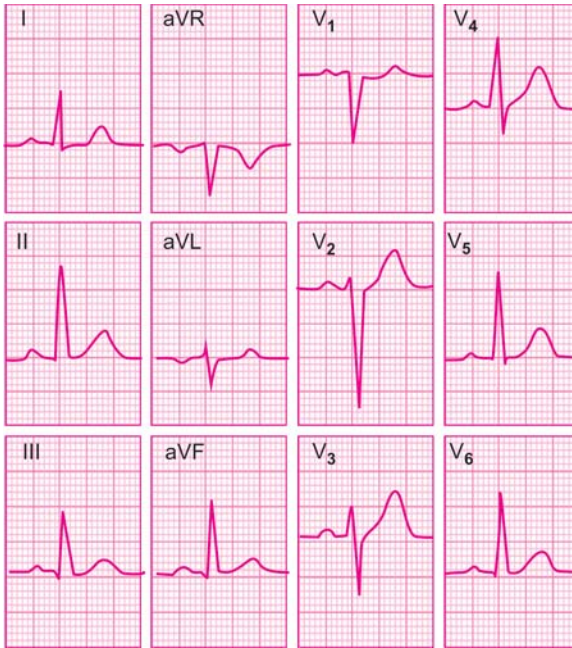


Fig. 2.1: The conventional 12-lead electrocardiogram

arm, left arm and left leg. The right leg electrode acts as the grounding electrode (**Fig. 2.2A**).

- ❖ Standard limb leads—three in number.
- ❖ Augmented limb leads—three in number.

Standard Limb Leads

The standard limb leads obtain a graph of the electrical forces as recorded between two limbs at a time. Therefore, the standard limb leads are also called bipolar leads. In these leads, on limb

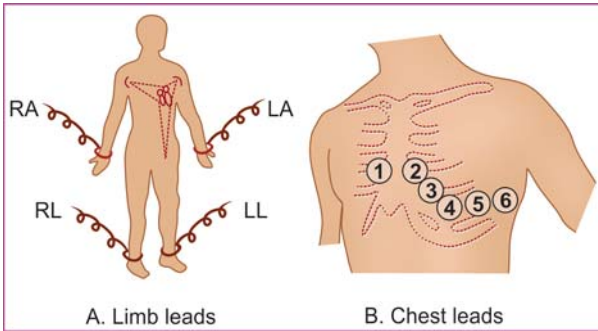


Fig. 2.2: Electrode placement for ECG recording

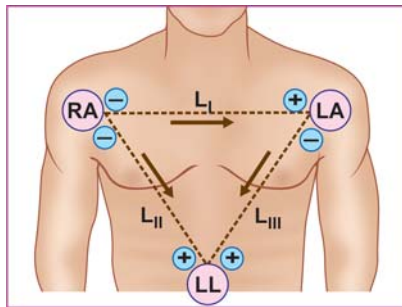


Fig. 2.3: The three standard limb leads: L_I, L_{II} and L_{III}

carries a positive electrode and the other limb carries a negative electrode. There are three standard limb leads (Fig. 2.3):

- ❖ Lead L_I
- ❖ Lead L_{II}
- ❖ Lead L_{III}

18 ECG Made Easy

Lead	Positive electrode	Negative electrode
I	LA	RA
II	LL	RA
III	LL	LA

Augmented Limb Leads

The augmented limb leads obtain a graph of the electrical forces as recorded from one limb at a time. Therefore, the augmented limb leads are also called unipolar leads. In these leads, one limb carries a positive electrode, while a central terminal represents the negative pole which is actually at zero potential. There are three augmented limb leads (**Fig. 2.4**):

- ❖ Lead aVR (Right arm)
- ❖ Lead aVL (Left arm)
- ❖ Lead aVF (Foot left).

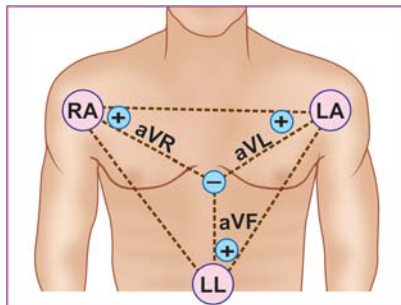


Fig. 2.4: The three unipolar limb leads: aVR, aVL and aVF

<i>Lead</i>	<i>Positive electrode</i>
aVR	RA
aVL	LA
aVF	LL

Note:

Inadvertent swapping of the leads for left and right arms (reversed arm electrodes) produces what is known as “technical” dextrocardia. The effects of arm electrode reversal on the limb leads are:

- ❖ Mirror-image inversion of L_I
- ❖ aVR exchanged with aVL
- ❖ L_{II} exchanged with L_{III}
- ❖ No change in lead aVF.

This is distinguished from true mirror-image dextrocardia by the fact that chest leads are normal.

THE CHEST LEADS

The chest leads are obtained from electrodes placed on the precordium in designated areas. An electrode can be placed on six different positions on the left side of the chest, each position representing one lead (**Fig. 2.2B**). Accordingly, there are six chest leads namely:

- ❖ Lead V_1 : Over the fourth intercostal space, just to the right of sternal border.
- ❖ Lead V_2 : Over the fourth intercostal space, just to the left of sternal border.
- ❖ Lead V_3 : Over a point midway between V_2 and V_4 (see V_4 below).

20 ECG Made Easy

- ❖ Lead V_4 : Over the fifth intercostal space in the midclavicular line.
- ❖ Lead V_5 : Over the anterior axillary line, at the same level as lead V_4 .
- ❖ Lead V_6 : Over the midaxillary line, at the same level as leads V_4 and V_5 .

Note:

Sometimes, the chest leads are obtained from electrodes placed on the right side of the chest. The right-sided chest leads are V_{1R} , V_{2R} , V_{3R} , V_{4R} , V_{5R} and V_{6R} . These leads are mirror-images of the standard left-sided chest leads.

V_{1R} : 4th intercostal space to left of sternum.

V_{2R} : 4th intercostal space to right of sternum.

V_{3R} : Point mid-way between V_{2R} and V_{4R} .

V_{4R} : 5th intercostal space in midclavicular line, and so on.

The right-sided chest leads are useful in cases of:

- ❖ True mirror-image dextrocardia.
- ❖ Acute inferior wall myocardial infarction (to diagnose right ventricular infarction).

THE LEAD ORIENTATION

We have thus seen that the 12-lead ECG consists of the following 12 leads recorded in succession:

L_I L_{II} L_{III} aVR aVL aVF V_1 V_2 V_3 V_4 V_5 V_6

Since the left ventricle is the dominant and clinically the most important chamber of the heart, it needs to be assessed in detail. The left ventricle can be viewed from different angles, each with a specific set of leads. The leads with respect to different regions of the left ventricle, are shown in **Table 2.1**.

Table 2.1: Region of left ventricle represented on ECG

ECG leads	Region of left ventricle
V ₁ , V ₂	Septal
V ₃ , V ₄	Anterior
V ₅ , V ₆	Lateral
V ₁ to V ₄	Antero-septal
V ₃ to V ₆	Antero-lateral
L _I , aVL	High lateral
L _{II} , L _{III} , aVF	Inferior

THE EINTHOVEN TRIANGLE

We have seen that the standard limb leads are recorded from two limbs at a time, one carrying the positive electrode and the other, the negative electrode. The three standard limb leads (L_I, L_{II}, L_{III}) can be seen to form an equilateral triangle with the heart at the center. This triangle is called the *Einthoven triangle* (Fig. 2.5A).

To facilitate the graphic representation of electrical forces, the three limbs of the Einthoven triangle can be redrawn in such a

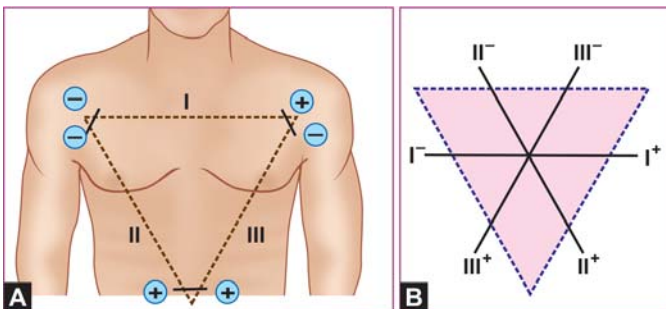


Fig. 2.5: A. The Einthoven triangle of limb leads
 B. The triaxial reference system

22 ECG Made Easy

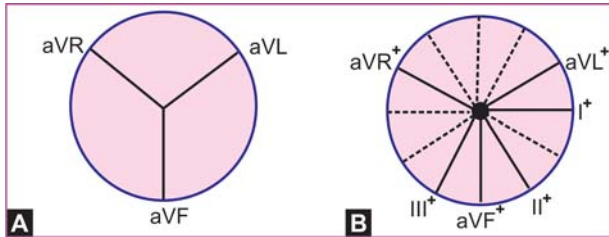


Fig. 2.6: A. The triaxial reference system from unipolar leads
B. The hexaxial system from unipolar and limb leads

way that the three leads they represent bisect each other and pass through a common central point. This produces a triaxial reference system with each axis separated by 60° from the other, the lead polarity (+ or -) and direction remaining the same (**Fig. 2.5B**).

We have also seen that the augmented limb leads are recorded from one limb at a time, the limb carrying the positive electrode and the negative pole being represented by the central point. The three augmented limb leads (aVR, aVL, aVF) can be seen to form another triaxial reference system with each axis being separated by 60° from one other (**Fig. 2.6A**).

When this triaxial system of unipolar leads is superimposed on the triaxial system of limb leads, we can derive a hexaxial reference system with each axis being separated by 30° from the other (**Fig. 2.6B**).

Note carefully that each of the six leads retains its polarity (positive and negative poles) and orientation (lead direction).

The hexaxial reference system concept is important in determining the major direction of the heart's electrical forces. As we shall see later, this is what we call the electrical axis of the QRS complex.

3

ECG Grid and Normal Values

THE ECG GRID

The electrocardiography paper is made in such a way that it is thermosensitive. Therefore, the ECG is recorded by movement of the tip of a heated stylus over the moving paper.

The ECG paper is available as a roll of 20 or 30 meters which when loaded into the ECG machine moves at a predetermined speed of 25 mm per second.

The ECG paper is marked like a graph, consisting of horizontal and vertical lines. There are fine lines marked 1 mm apart while every fifth line is marked boldly. Therefore, the bold lines are placed 5 mm apart (**Fig. 3.1**).

Time is measured along the horizontal axis in seconds while voltage is measured along the vertical axis in millivolts.

During ECG recording, the usual paper speed is 25 mm per second. This means that 25 small squares are covered in one second. In other words, the width of 1 small square is $1/25$ or 0.04 seconds and the width of 1 large square is 0.04×5 or 0.2 seconds.

Therefore, the width of an ECG deflection or the duration of an ECG interval is the number of small squares it occupies on the horizontal axis multiplied by 0.04 (**Fig. 3.1**). Accordingly, 2 small squares represent 0.08 sec., 3 small squares represent 0.12 sec. and 6 small squares represent 0.24 sec.

Normally, the ECG machine is standardized in such a way that a 1 millivolt signal from the machine produces a 10 millimeter

24 ECG Made Easy

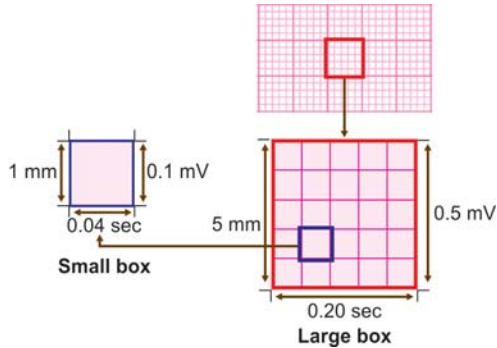


Fig. 3.1: The enlarged illustration of the electrocardiography paper
1 small square = 1 mm. 5 small squares = 1 big square
Vertically, 1 small square = 0.1 mV. 5 of them = 0.5 mV
Horizontally, 1 small square = 0.04 sec. 5 of them = 0.2 sec

vertical deflection. In other words, each small square on the vertical axis represents 0.1 mV and each large square represents 0.5 mV.

Therefore, the height of a positive deflection (above the baseline) or the depth of a negative deflection (below the baseline) is the number of small squares it occupies on the vertical axis multiplied by 0.1 mV (**Fig. 3.1**). Accordingly, 3 small squares represent 0.3 mV, 1 large square represents 0.5 mV and 6 small squares represent 0.6 mV.

Similarly, the degree of elevation (above the baseline) or depression (below the baseline) of segment is expressed in number of small squares (millimeters) of segment elevation or segment depression, in relation to the isoelectric line.

THE NORMAL ECG VALUES

Normal P Wave

The P wave is a small rounded wave produced by atrial depolarization. In fact, it reflects the sum of right and left atrial

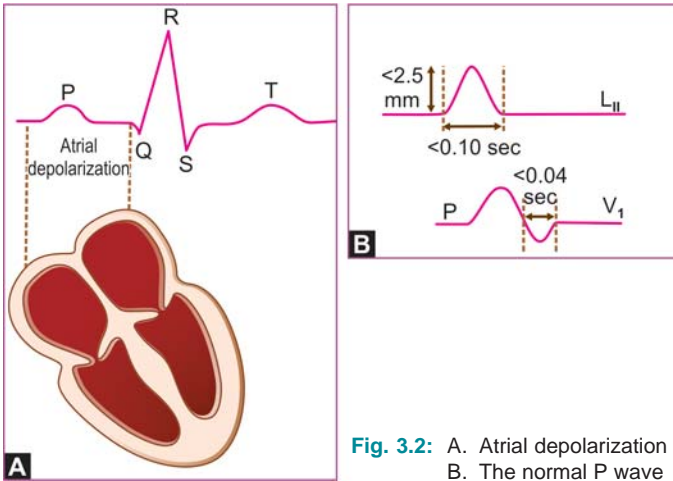


Fig. 3.2: A. Atrial depolarization
B. The normal P wave

activation, the right preceding the left since the pacemaker is located in the right atrium (**Fig. 3.2A**).

The P wave is normally upright in most of the ECG leads with two exceptions. In lead aVR, it is inverted along with inversion of the QRS complex and the T wave, since the direction of atrial activation is away from this lead.

In lead V₁, it is generally biphasic that is, upright but with a small terminal negative deflection, representing left atrial activation in a reverse direction.

Normally, the P wave has a single peak without a gap or notch between the right and left atrial components. A normal P wave meets the following criteria:

- ❖ Less than 2.5 mm (0.25 mV) in height.
- ❖ Less than 2.5 mm (0.10 sec) in width (**Fig. 3.2B**).

26 ECG Made Easy

Normal QRS Complex

The QRS complex is the major positive deflection on the ECG produced by ventricular depolarization. In fact, it represents the timing and sequence of synchronized depolarization of the right and left ventricles.

The Q wave is not visible in all ECG leads. Physiological Q waves may be observed in leads L_1 , aVL , V_5 and V_6 where they represent initial activation of the interventricular septum in a direction opposite to the direction of activation of the main left ventricular mass.

A physiological Q wave meets the following criteria:

- ❖ Less than 0.04 sec in width.
- ❖ Less than 25 percent of R wave (**Fig. 3.3A**).

The leads in which physiological Q waves appear depends upon the direction towards which the main mass of the left ventricle is oriented.

If the left ventricle is directed towards the lateral leads (horizontal heart), Q waves appear in leads L_1 , aVL , V_5 and V_6 (**Fig. 3.3B**). If it is directed towards the inferior leads (vertical heart), Q waves appear in leads L_{II} , L_{III} and aVF .

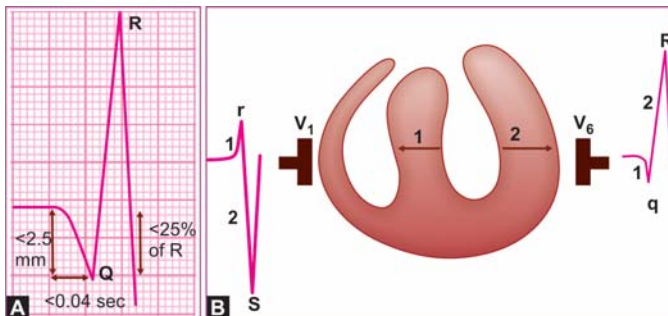


Fig. 3.3: A. The normal Q wave
B. Septal depolarization (1)

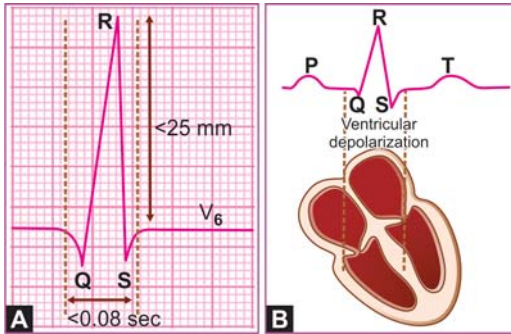


Fig. 3.4: A. The normal QRS complex
B. Ventricular depolarization

The R wave is the major positive deflection of the QRS complex. It is upright in most leads except in lead aVR where the P wave and T wave are also inverted.

In the limb leads, R wave voltage is normally at least 5 mm while in the precordial leads, R wave voltage exceeds 10 mm.

Under normal circumstances, the R wave voltage gradually increases as we move from lead V_1 to lead V_6 . This is known as normal R wave progression in precordial leads.

Normally, the R wave amplitude does not exceed 0.4 mV (4 mm) in lead V_1 where it reflects septal activation and does not exceed 2.5 mV (25 mm) in lead V_6 where it reflects left ventricular activation (**Fig. 3.4A**).

The r wave is smaller than the S wave in lead V_1 and the R wave is taller than the s wave in lead V_6 .

The S wave is the negative deflection that follows the R wave, representing the terminal portion of ventricular depolarization.

In lead V_1 , the S wave reflects left ventricular activation while in lead V_6 the s wave reflects right ventricular activation.

Normally, the S wave magnitude is greater than the r wave height in lead V_1 and the s wave is smaller than the R wave in

28 ECG Made Easy

lead V_6 . The normal s wave voltage in lead V_6 does not exceed 0.7 mV.

The QRS complex represents depolarization of the total ventricular muscle. The relative amplitude of the R wave and S wave in a particular lead reflects the relative contributions of the right and left ventricles.

For instance in lead V_1 , the r wave is smaller than the S wave while in lead V_6 the s wave is smaller than the R wave.

The duration of the QRS complex is the total time taken for both ventricles to be depolarized. Since the right and left ventricles are depolarized in a synchronous fashion, the normal QRS complex is narrow, has a sharp peak and measures less than 0.08 sec (2 mm) on the horizontal axis (**Fig. 3.4B**).

Normal T Wave

The T wave is a large rounded wave produced by the rapid phase of ventricular repolarization (**Fig. 3.5**). The T wave is normally upright in most leads with certain exceptions.

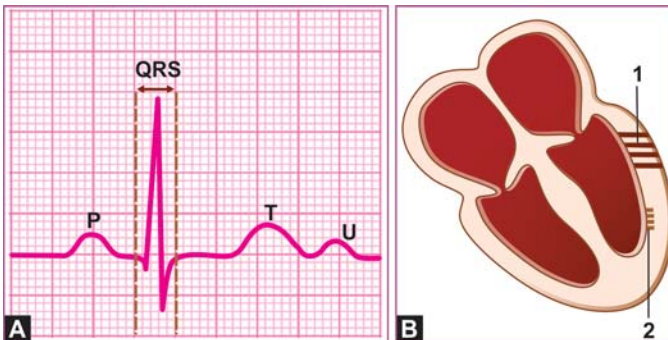


Fig. 3.5: A. The normal T and U waves as seen on the ECG
B. (1) T wave: ventricular mass repolarization
(2) U wave: Purkinje system repolarization

It is invariably inverted in lead aVR along with inversion of the P wave and QRS complex. It is often inverted in lead V₁, occasionally in lead V₂ V₃ and sometimes in lead L_{III}.

The normal T wave is taller in lead V₆ than in lead V₁. The amplitude of the normal T wave does not generally exceed 5 mm in the limb leads and 10 mm in the precordial leads.

Normal U Wave

The U wave is a small rounded wave produced by slow and late repolarization of the intraventricular Purkinje system, after the main ventricular mass has been repolarized (**Fig. 3.5**).

It is often difficult to notice the U wave but when seen, it is best appreciated in the precordial leads V₂ to V₄. The U wave is more easy to recognize when the Q-T interval is short or the heart rate is slow, in which conditions it is clearly separated from the preceding T wave and the P wave of the following beat, respectively.

The normal U wave is upright and it is normally much smaller than the T wave which it follows.

Normal P-R Interval

The P-R interval is measured on the horizontal axis from the onset of the P wave to the beginning of the QRS complex, irrespective of whether it begins with a Q wave or a R wave (**Fig. 3.6**).

Since the P wave represents atrial depolarization and the QRS complex represents ventricular depolarization, the P-R interval is a measure of the atrioventricular (AV) conduction time.

The A-V conduction time includes time for atrial depolarization, conduction delay in the AV node and time required for the impulse to traverse the conduction system before ventricular depolarization begins.

The normal P-R interval is in the range of 0.12 to 0.20 sec, depending upon the heart rate. It is prolonged at slow heart

30 ECG Made Easy

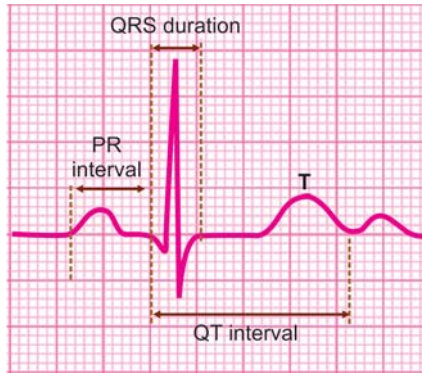


Fig. 3.6: The normal ECG intervals

rates and shortened at fast heart rates. The P-R interval tends to be slightly shorter in children (upper limit 0.18 sec) and slightly longer in elderly persons (upper limit 0.22 sec).

Normal Q-T Interval

The Q-T interval is measured on the horizontal axis from the onset of the Q wave to the end of the T wave (**Fig. 3.6**).

Since the QRS complex represents ventricular depolarization and the T wave represents ventricular repolarization, Q-T interval denotes the total duration of ventricular systole.

The Q-T interval includes the duration of QRS complex, the length of S-T segment and the width of the T wave.

The normal Q-T interval is in the range of 0.35 to 0.43 sec or 0.39 ± 0.04 sec. The Q-T interval depends upon three variables namely age, sex and heart rate.

The Q-T interval tends to be shorter in young individuals and longer in the elderly. It is normally, slightly shorter in females, the upper limit being 0.42 sec. The Q-T interval shortens at fast heart rates and lengthens at slow heart rates.

Therefore, for proper interpretation, the Q-T interval must be corrected for the heart rate. The corrected Q-T interval is known as the Q-T_c interval. The Q-T_c interval is determined using the formula:

$$Q - T_c = \frac{Q - T}{\sqrt{R - R}}$$

where, Q-T is the measured Q-T interval, and

$\sqrt{R - R}$ is the square-root of the measured R-R interval.

Since, the R-R interval at a heart rate of 60 is 25 mm or 1 second ($25 \times 0.04 \text{ sec} = 1 \text{ sec}$), the Q-T_c interval is equal to the Q-T interval at a heart rate of 60 per minute.

Normal P-R Segment

The portion of the baseline (isoelectric line), which intervenes between the termination of the P wave and the onset of the QRS complex, is the P-R segment (**Fig. 3.7**).

Normally, it is at the same level as the main segment of the isoelectric line which intervenes between the T wave of one cycle and the P wave of the next cycle.

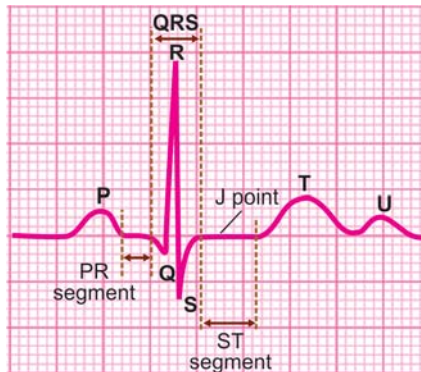


Fig. 3.7: The normal ECG segments

32 ECG Made Easy

Normal S-T Segment

The portion of the baseline (isoelectric line), which intervenes between the termination of the S wave and the onset of the T wave, is the S-T segment (**Fig. 3.7**).

The beginning of the S-T segment is the junction point (J point). Normally, the S-T segment and the J point are in level with the main segment of the isoelectric line which intervenes between the T wave of one cycle and the P wave of the next cycle.

4

Determination of Electrical Axis

THE ELECTRICAL AXIS

During activation of the heart, the electrical forces or action potentials which have been generated, are propagated in various directions. These electrical forces can be picked up from the surface of the body by means of electrodes.

Normally, over 80 percent of these forces are cancelled out by equal and opposing forces, and only the net forces remaining are recorded. The dominant direction of these forces, which is the mean of all recorded forces, constitutes the electrical axis of an electrocardiographic deflection.

Since the QRS complex is the major deflection on the ECG, we shall confine ourselves to the QRS electrical axis.

THE HEXAXIAL SYSTEM

We have already seen that the three standard limb leads L_I , L_{II} and L_{III} form an equilateral triangle with the heart at its center, which is called the Einthoven triangle.

The Einthoven triangle can be redrawn in such a way that the three leads pass through a common central point. This constitutes a triaxial reference system with each axis separated from the other by 60° .

Similarly, the three augmented limb leads can constitute another triaxial reference system (**Fig. 4.1A**). When these two triaxial

34 ECG Made Easy

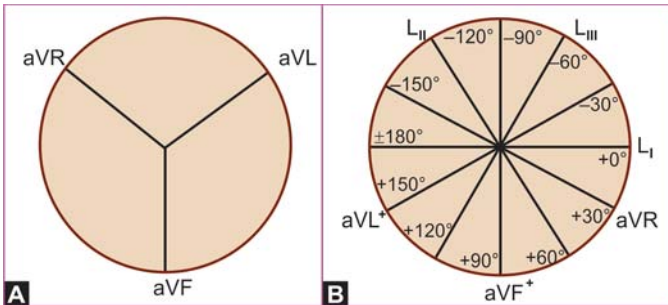


Fig. 4.1: A. The triaxial reference system from unipolar leads
B. The hexaxial system from unipolar and limb leads

systems are superimposed on each other, we can derive a hexaxial reference system in a 360° circle, with each axis separated from the other by 30° (**Fig. 4.1B**).

In the hexaxial system, each of the six leads maintains its own polarity and direction. The hexaxial reference system is the basis of understanding the concept of electrical axis and its determination.

THE QRS AXIS

Before going on to the actual determination of the QRS axis, certain basic principles have to be understood.

- ❖ The QRS axis is expressed as a degree on the hexaxial system and represents the direction of electrical forces in the frontal plane (**Fig. 4.2**).
- ❖ The net deflection in any lead is the algebraic sum of the positive and negative deflections. For instance, if in any lead the positive deflection (R) is +6 and the negative deflection (S) is -2, the net deflection is +4.

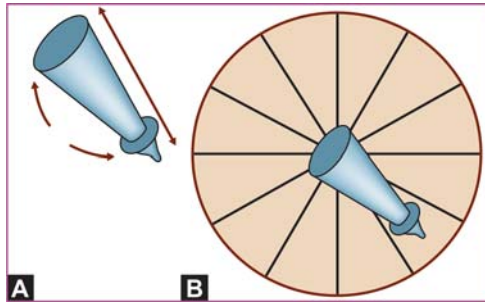


Fig. 4.2: A. The direction and magnitude of the QRS vector
 B. The QRS vector projected on the hexaxial system

- ❖ An electrical force that runs parallel to any lead, records the maximum deflection in that lead. An electrical force that runs obliquely to any lead, records a small deflection in that lead. An electrical force that runs perpendicular to any lead records a nil or equiphasic (positive and negative deflections equal) deflection in that lead.
- ❖ As an example, if the axis is $+90^\circ$, lead aVF records the maximum deflection. Lead L_1 records the least deflection and the deflections in all other leads are intermediate.
- ❖ If in the lead showing the maximum deflection, the major deflection is positive, the axis points towards the positive pole of that lead. Conversely, if the major deflection is negative, the axis points towards the negative pole of that particular lead.
- ❖ As an example, lead L_{II} is showing the maximum deflection say 7 mm. If it is +7, the axis is $+60^\circ$ while if it is -7, the axis is -120° .

DETERMINATION OF QRS AXIS

The QRS axis can be determined by several methods.

Method 1

- ❖ Find the lead with smallest or equiphase deflection.
- ❖ Determine the lead at right angles to the first lead.
- ❖ See the net deflection in the second lead.
- ❖ The axis is directed towards the positive or negative pole of the second lead.

Example A

- ❖ Lead with smallest deflection is aVL
- ❖ Lead at right angles to aVL is L_{II}
- ❖ Major deflection in lead L_{II} is positive AXIS is + 60°

Example B

- ❖ Lead with smallest deflection is aVR
- ❖ Lead at right angles to aVR is L_{III}
- ❖ Major deflection in lead L_{III} is negative AXIS is -60°

Method 2

- ❖ Find the net deflection in leads L_I and aVF, which are perpendicular to each other.
- ❖ Plot the net deflection in these leads onto their respective axes, on a scale of 0 to 10.
- ❖ Drop perpendicular lines from these points and plot a point where these lines intersect.
- ❖ Join the center of the circle to the intersection point and extend it to the circumference.
- ❖ The point on the circumference where this line intersects is the QRS axis.

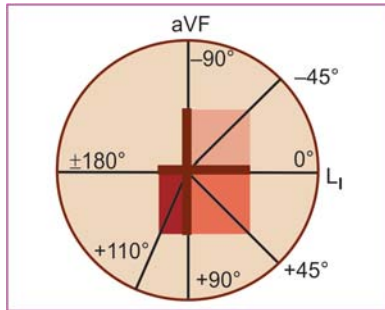


Fig. 4.3: QRS axis determined from leads L_1 and aVF

Example A

- ❖ Net deflection in L_1 is +5
- ❖ Net deflection in aVF is 0 AXIS is 0°

Example B

- ❖ Net deflection in L_1 is +5
- ❖ Net deflection in aVF is -5 AXIS is -45° (Fig. 4.3)

Example C

- ❖ Net deflection in L_1 is +6
- ❖ Net deflection in aVF is + 3 AXIS is + 30°

Method 3

For rapid and easy estimation of QRS axis, just scan the direction of the dominant deflection in leads L_1 and aVF whether positive or negative. This gives us the quadrant in which the QRS axis is located (Table 4.1).

38 ECG Made Easy

Table 4.1: QRS axis quadrant determined from leads L_1 and aVF

<i>Main QRS deflection</i>		<i>QRS axis quadrant</i>
L_1	aVF	
+ve	+ve	0 to $+90^\circ$
+ve	-ve	0 to -90°
-ve	+ve	$+90$ to $+180^\circ$
-ve	-ve	-90 to -180°

ABNORMALITIES OF QRS AXIS

- ❖ Normal QRS axis
 -30° to $+90^\circ$
- ❖ Right axis deviation
 $+90^\circ$ to $+180^\circ$

Causes

- Thin tall built
- Chronic lung disease
- Pulmonary embolism
- Ostium secundum ASD
- Right ventricular hypertrophy
- Left posterior hemiblock
- Lateral wall infarction

- ❖ Left axis deviation
 -30° to -90°

Causes

- Obese stocky built
- WPW syndrome

- Cardiac pacing
- Ostium primum ASD
- Left ventricular hypertrophy
- Left anterior hemiblock
- Inferior wall infarction

❖ North-West QRS axis

-90° to -180°

Causes

- Congenital heart disease
- Left ventricular aneurysm

Synonyms

- Indeterminate QRS axis
- Extreme right axis deviation
- NO MAN'S LAND (Fig. 4.4).

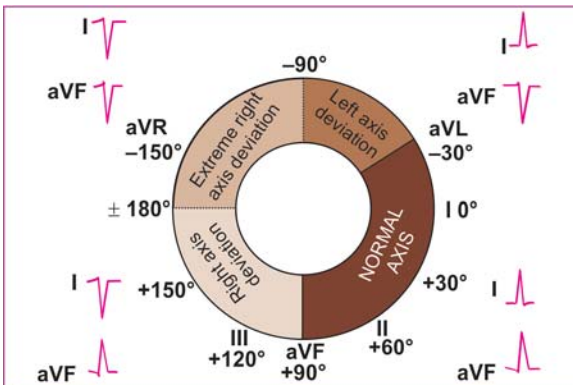


Fig. 4.4: The normal QRS axis and axis deviation



Determination of the Heart Rate

THE HEART RATE

The heart rate is simply the number of heart beats per minute. In electrocardiographic terms, the heart rate is the number of cardiac cycles that occur during a 60 second (1 minute) continuous recording of the ECG.

In order to calculate the heart rate from a given ECG strip all that we have to remember is that the ECG paper moves at a speed of 25 mm per second. The rest is all deductive mathematics. Let us see how the heart rate is actually calculated.

Method 1

The ECG paper moves by 25 small squares (each small square = $1/25 = 0.04$ seconds), or by 5 large squares (each large square = 5 small squares = $0.04 \times 5 = 0.2$ seconds) in one second.

If one notes carefully, the vertical line of every fifth large square extends slightly beyond the edge of the graph paper. Therefore, the distance between two such extended lines is one second and the distance between one such line and the sixth line after it is six seconds.

We can count the number of QRS complexes in one such six second interval. Multiplying this number by ten will give us the number of QRS complexes in sixty seconds (one minute), which is the approximate heart rate.

Examples

- ❖ There are 8 QRS complexes in a 6 second interval. Heart rate is around $8 \times 10 = 80$ beats/minute.
- ❖ There are 11 QRS complexes in a 6 second interval. Heart rate is around $11 \times 10 = 110$ beats/minute.

Method 2

The ECG paper moves by 25 small squares in one second. In other words it moves by $25 \times 60 = 1500$ small squares in 60 seconds or one minute. If the distance between two successive ECG complexes in number of small squares is measured, the number of ECG complexes in one minute will be 1500 divided by that number. This will give us the heart rate in beats per minute (**Fig. 5.1**).

The interval between two successive P waves (P-P interval) determines the atrial rate and the interval between two successive R waves (R-R interval) determines the ventricular rate. During normal rhythm, the P waves and the QRS complexes track together and therefore, the heart rate calculated by using either the P-P interval or R-R interval will be the same.

To measure the P-P or R-R interval, it is preferable to begin with a P or R wave that is superimposed on a heavy line

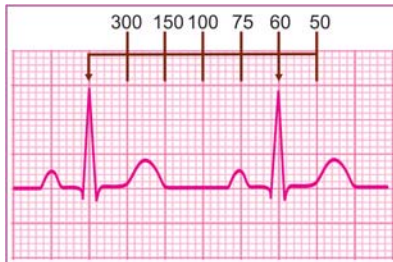

Fig. 5.1: Calculation of the heart rate from R-R interval, if R-R interval = 25 mm; Heart rate = 60/min

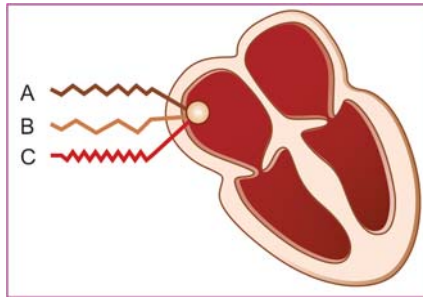


Fig. 5.2: Variation of heart rate:
 A. Normal rate
 B. Bradycardia
 C. Tachycardia

marking of a large square. This facilitates the measurement of the interval between it and the next wave, in multiples of 5 mm (one large square = 5 small squares).

A single P-P or R-R interval measurement generally suffices for heart rate determination if the heart beating is regular (equally spaced complexes). If however, the heart beating is irregular (unequally spaced complexes), a mean of 5 or 10 P-P or R-R intervals is taken into account.

Examples

- ❖ The R-R interval is 20 mm. Therefore, the heart rate is $1500/20 = 75$ beats per minute.
- ❖ The R-R interval is 12 mm. Therefore, the heart rate is $1500/12 = 125$ beats per minute.

For rapid heart rate determination, certain standard R-R intervals can be memorized (**Table 5.1A**).

We see that the normal R-R interval ranges from 15 to 25 mm, representing a heart rate of 60 to 100 beats per minute. A short R-R interval (less than 15 mm) denotes tachycardia (heart rate

Table 5.1A: Determining the heart rate from R-R interval

<i>R-R interval</i>	<i>Heart rate</i>
10 mm	$1500/10 = 150$
12 mm	$1500/12 = 125$
15 mm	$1500/15 = 100$
20 mm	$1500/20 = 75$
25 mm	$1500/25 = 60$
30 mm	$1500/30 = 50$

> 100) and a long R-R interval (more than 25 mm) denotes bradycardia (heart rate < 60).

The heart rate range can also be rapidly assessed from the range of R-R interval. For instance:

- ❖ If the R-R interval is 10 to 15 mm, the heart rate is 100 to 150 per minute.
- ❖ If the R-R interval is 15 to 20 mm, the heart rate is 75 to 100 per minute.
- ❖ If the R-R interval is 20 to 25 mm, the heart rate is 60 to 75 per minute.

For a more precise determination of the heart rate, we can use a reference like the one given below (**Table 5.1B**).

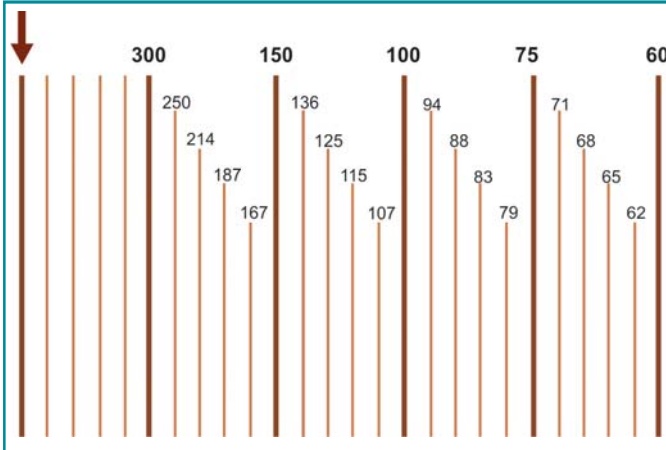
THE HEART RHYTHM

The rhythm of the heart can be classified on the basis of the following criteria:

- ❖ Rate of impulse origin
- ❖ Focus of impulse origin
- ❖ Pattern of rhythm regularity
- ❖ Atrioventricular relationship.

44 ECG Made Easy

Table 5.1B: Precise determination of the heart rate



Heart Rate

The normal heart rate varies from 60 to 100 beats per minute. A cardiac rhythm at a rate less than 60 beats per minute constitutes bradycardia. A cardiac rhythm at a rate exceeding 100 beats per minute constitutes tachycardia.

We have seen that the P-P interval determines the atrial rate and the R-R interval determines the ventricular rate. Normally, the P-P and R-R intervals are identical and the atrial rate is the same as the ventricular rate. However, under certain circumstances, the atrial and ventricular rates are different and have to be determined separately.

Under normal circumstances when the cardiac rhythm is regular, the measurement of a single R-R interval suffices for heart rate determination as the QRS complexes are equally spaced. If the cardiac rhythm is irregular, that is, the QRS complexes are not equally spaced, a mean of 5 or 10 R-R intervals has to be taken.

On the basis of heart rate, any cardiac rhythm can thus be classified as:

- ❖ Normal rate (HR 60-100)
- ❖ Bradycardia (HR < 60)
- ❖ Tachycardia (HR > 100)

Focus of Origin

The cardiac pacemaker possesses the property of automatic generation of impulses or automaticity. The normal pacemaker is the sinoatrial node (SA node) located in the right atrium.

A cardiac rhythm originating from the SA node is called sinus rhythm. The SA node normally discharges at a rate of 60 to 100 beats per minute. A sinus rhythm at this rate is called normal sinus rhythm.

Besides the SA node, there are other potential pacemakers in the heart such as in the atria, atrioventricular junction and the ventricles. They are known as ectopic or subsidiary pacemakers. The subsidiary pacemakers can discharge at a slower rate than the SA node.

For instance, an atrial or junctional pacemaker can fire 40 to 60 impulses per minute while a ventricular pacemaker can fire 20 to 40 impulses per minute. It is for this reason that the SA node governs the cardiac rhythm by silencing these subsidiary pacemakers. In other words, the subsidiary pacemakers are unable to express their inherent automaticity.

However, under two situations, a subsidiary pacemaker can govern the rhythm of the heart. The first is when impulses generated from the SA node are either insufficient (sinus bradycardia) or they get blocked (SA block) and a subsidiary pacemaker is called upon to take over the cardiac rhythm. The second is when the inherent automaticity of a subsidiary pacemaker is enhanced and it over-rides the SA node to take over the cardiac rhythm.

46 ECG Made Easy

The former situation, in which a subsidiary automaticity focus is called upon to take over the cardiac rhythm, is called an escape rhythm. The subsidiary pacemaker, so to say, escapes overdrive suppression by the SA node and expresses its inherent automaticity. The escape rhythm is triggered when intrinsic rhythm ceases or slows down and is inhibited when patient's own rhythm resumes at a reasonable rate. The subsidiary pacemaker of an escape rhythm may be junctional or ventricular. Accordingly, an escape rhythm may be classified as:

- ❖ Junctional escape rhythm or idiojunctional rhythm.
- ❖ Ventricular escape rhythm or idioventricular rhythm.

The latter situation, in which a subsidiary pacemaker undergoes enhancement of its inherent automaticity so as to over rule the SA node and take over the cardiac rhythm, is called idiofocal tachycardia. The subsidiary pacemaker of an idiofocal tachycardia may be atrial, junctional or ventricular. Accordingly, an idiofocal tachycardia may be classified as:

- ❖ Atrial tachycardia
- ❖ Junctional tachycardia
- ❖ Ventricular tachycardia.

On the basis of focus of origin, any cardiac rhythm can thus be classified as shown in **Figure 5.3**:

- ❖ Sinus rhythm
- ❖ Atrial rhythm
- ❖ Junctional rhythm
- ❖ Ventricular rhythm.

Electrocardiographically speaking, the focus of origin of a cardiac rhythm can be reasonably predicted from the morphology of and relationship between P waves and QRS complexes.

In sinus rhythm, the P waves and QRS complexes are of normal morphology and normally related to each other. In other words,

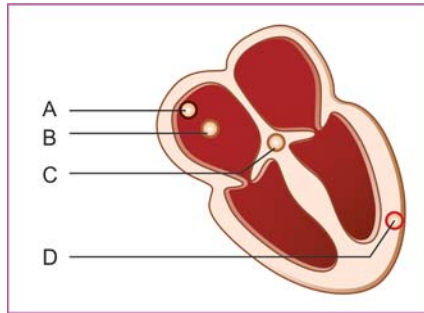


Fig. 5.3: Origin of cardiac rhythm:

- A. Sinus rhythm
- B. Atrial rhythm
- C. Junctional rhythm
- D. Ventricular rhythm

the P wave is upright, the P-R interval is normal and the QRS complex is narrow.

In atrial rhythm, the P wave is different in morphology from the sinus wave and may be inverted due to abnormal sequence of atrial activation. The P-R interval may be short reflecting a shortened atrioventricular conduction time. However, the QRS complex retains its normal narrow configuration as intraventricular conduction of the atrial impulse proceeds as usual.

In junctional rhythm, the P wave is generally inverted and may just precede, just follow or be merged in the QRS complex. This is because the atria are activated retrogradely (from below upwards) from the junctional pacemaker and almost simultaneously with the ventricles. The QRS complexes retain their normal narrow configuration as intraventricular conduction of junctional impulses proceeds as usual.

In ventricular rhythm, either the SA node continues to activate the atria producing upright sinus P waves or the atria are activated by retrograde conduction of ventricular impulses

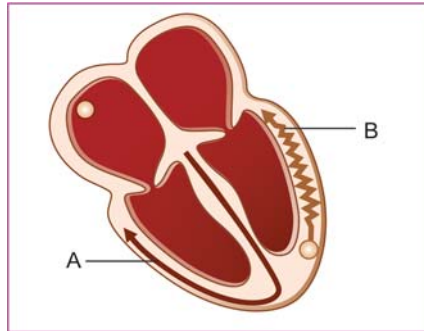


Fig. 5.4: Ventricular activation pattern:
A. Supraventricular rhythm
B. Ventricular rhythm

producing inverted P waves. In both cases, the P waves are difficult to discern as the hallmark of a ventricular rhythm is wide QRS complexes in which the P waves are usually buried.

The QRS complex is wide and bizarre in a ventricular rhythm since ventricular activation occurs in a slow, random fashion through the myocardium and not in a rapid, organized fashion through the specialized conduction system (**Fig. 5.4**).

Pattern of Regularity

The normal cardiac rhythm is regular that is, the interval between the different beats is the same (equally spaced QRS complexes). At times, however, the cardiac rhythm may be irregular that is, the QRS complexes are not equally spaced. Irregularity of cardiac rhythm is further of two types, regular irregularity and irregular irregularity.

On the basis of pattern of regularity, any cardiac rhythm can thus be classified as:

- ❖ Regular rhythm
- ❖ Irregular rhythm
 - regularly irregular rhythm
 - irregularly irregular rhythm

Almost all sinus rhythms including sinus bradycardia and sinus tachycardia as well as fast rhythms such as atrial, junctional and ventricular tachycardias are regular rhythms.

Examples of regularly irregular rhythms are:

- ❖ Premature beats during any rhythm
- ❖ Regular pauses during any rhythm
- ❖ Beats in pairs; bigeminal rhythm.

Fibrillation is the prototype of an irregularly irregular rhythm. Fibrillation is characterized by the functional fragmentation of the atrial or ventricular myocardium into numerous tissue islets in various stages of excitation and recovery (**Fig. 5.5**). Myocardial depolarization is thus chaotic and ineffectual in pumping.

In atrial fibrillation, the discrete P waves of sinus rhythm are replaced by numerous, small irregularly occurring fibrillatory

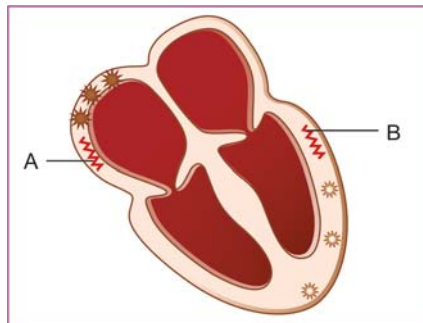


Fig. 5.5: Myocardial activation during fibrillation:
A. Atrial fibrillation
B. Ventricular fibrillation

50 ECG Made Easy

waves of variable morphology. These fibrillatory waves produce a ragged baseline or a straight line with minimal undulations between QRS complexes.

The R-R interval is highly variable and the heart rate grossly irregular as out of the numerous fibrillatory waves, only a few can activate the ventricles and that too at random. The QRS complexes are normal in morphology as the intraventricular conduction proceeds as usual.

Ventricular fibrillation manifests itself with rapid, irregularly occurring, small deformed deflections, grossly variable in shape, height and width. The regular waveforms of P waves, QRS complexes and T waves are distorted beyond recognition and the baseline seems to waver unevenly.

Atrioventricular Relationship

The normal cardiac activation sequence is such that the electrical impulse from the SA node first activates the atria and then travels downwards through the conducting system to activate the ventricles. We know that atrial depolarization is represented by the P wave and ventricular depolarization is represented by the QRS complex. Therefore, the P wave is followed by the QRS complex and the two are related to each other.

Imagine, a situation in which the atria are governed by the SA node while the ventricles are governed by a subsidiary pacemaker located in the A-V junction or the ventricle. In that case, the atria and ventricles will beat independent of each other (**Fig. 5.6**), and the P waves will be unrelated to the QRS complexes. This is precisely what is meant by atrioventricular dissociation (A-V dissociation).

There are various electrocardiographic conditions that produce A-V dissociation. The first situation is one in which a junctional/ventricular pacemaker undergoes an enhancement of automaticity and activates the ventricles at a rate faster than the rate at which the SA node activates the atria.

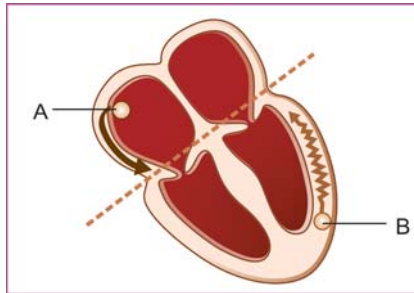


Fig. 5.6: Atrioventricular dissociation:
 A. Atrial rhythm
 B. Ventricular rhythm

In that case, the P waves will either be unrelated to the QRS complexes or alternatively, they will be buried in the wide QRS complexes. The R-R intervals may be slightly shorter than the P-P intervals (ventricular rate slightly more than atrial rate). This allows the P-R interval to progressively shorten till the P wave merges into the QRS complex.

Secondly, if there is complete A-V nodal block, no atrial beat is followed by or related to a ventricular beat and the P waves occur independent of the QRS complexes. However, the P-P and R-R intervals are constant. The relative rate of discharge of the atrial and ventricular pacemakers depends upon the condition causing A-V dissociation. This is shown in [Table 5.2](#).

In A-V dissociation, the P wave retains its normal morphology as the atria are governed by the SA node as usual. The morphology of the QRS complex depends upon the site of the subsidiary pacemaker.

If the pacemaker is junctional, the QRS complex is normal and narrow as ventricular activation occurs through the specialized conduction system. If the pacemaker is ventricular, the QRS complex is abnormal and wide as ventricular activation then occurs through ordinary myocardium.

52 ECG Made Easy

Table 5.2: Various arrhythmias causing A-V dissociation

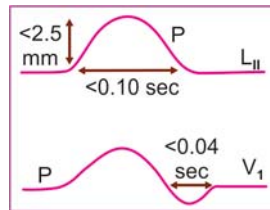
	<i>Idiojunctional tachycardia</i>	<i>Idioventricular tachycardia</i>	<i>Complete A-V block</i>
Atrial rate	70-80 (normal)	70-80 (normal)	70-80 (normal)
Junctional rate	70-100 (slightly faster)	—	40-60 (slightly slower) or
Ventricular rate	—	70-100 (slightly faster)	20-40 (much slower)

6

Abnormalities of the P Wave

NORMAL P WAVE

The P wave is produced by atrial depolarization. It is the sum of right and left atrial activation, the right atrium being activated first since the pacemaker is located in it. The normal P wave meets the following criteria:



- ❖ It is upright in most leads (except aVR, V_1)
- ❖ It is constant in morphology, beat to beat
- ❖ It has a single peak and it is not notched
- ❖ It is less than 2.5 mm (0.25 mV) in height
- ❖ It is less than 2.5 mm (0.10 sec) in width.

ABSENT P WAVE

The P waves are not discernible in the following conditions:

- ❖ *Atrial fibrillation* In atrial fibrillation, P waves are replaced by numerous, small, irregularly occurring fibrillatory waves, producing a ragged base-line.
- ❖ *Atrial flutter* In atrial flutter, P waves are replaced by flutter waves (F waves) that give the baseline a corrugated or saw-toothed appearance.

54 ECG Made Easy

- ❖ *Junctional rhythm* In a junctional rhythm, P waves may just precede, just follow or are buried in the QRS complexes due to near simultaneous activation of the ventricles anterogradely and the atria retrogradely.
- ❖ *Ventricular tachycardia* In ventricular tachycardia, P waves are difficult to identify as they lie buried in the wide QRS complexes.
- ❖ *Hyperkalemia* In hyperkalemia, P waves are reduced in amplitude or altogether absent. This is associated with tall T waves and wide QRS complexes.

INVERTED P WAVE

The P waves are normally upright in leads L_{II} , L_{III} and aVF, since the atria are activated above downwards towards the inferior leads. If activation of the atria occurs retrogradely from below upwards, the P waves in these leads are negative or inverted. Inverted P waves are thus observed in the following conditions:

- ❖ *Junctional rhythm* In a junctional rhythm, inverted P waves may just precede or just follow the QRS complexes.
- ❖ *By-pass tract* Inverted P waves are seen if the atria are activated retrogradely through an accessory pathway by-passing the A-V node. This is known as a by-pass tract and occurs in WPW syndrome.

CHANGING P WAVE MORPHOLOGY

Normally, all the P waves in a given ECG strip are of identical morphology, reflecting a constant pattern of atrial activation. If impulses arise from different foci other than the SA node, the pattern of atrial activation varies from beat to beat. This produces P waves of different morphology, known as P' waves. P' waves are observed in the following rhythms:

- ❖ *Wandering pacemaker rhythm* In this rhythm the pacemaker, so to say, wanders from one focus to the other. The focus of origin of impulses varies from SA node to atrium to AV junction. This results in P waves of variable morphology.
- ❖ *Multifocal atrial tachycardia* In this rhythm, impulses arise from multiple atrial foci to produce an atrial tachycardia or a chaotic pattern of atrial activation. Therefore, the P wave configuration changes from beat to beat.

In both the above rhythms, three kinds of P waves may be observed. Ectopic P' waves are upright but different from sinus P waves and are atrial in origin. Retrograde P' waves are inverted and are junctional in origin. Fusion beats are P waves having a morphology in between that of a sinus P wave and an ectopic P' wave.

Interestingly, wandering pacemaker (WPM) rhythm and multifocal atrial tachycardia (MAT) only differ in terms of the heart rate. While WPM rhythm occurs at a rate less than 100 beats/min., the rate exceeds 100 beats/min. in MAT.

TALL P WAVE

The normal P wave is less than 2.5 mm in height. It is the sum of right and left atrial activation, right preceding the left. If the right atrium is enlarged, the deflection of the right atrium is superimposed on the left atrial deflection resulting in a tall P wave exceeding 2.5 mm in height.

Therefore, a tall P wave is representative of right atrial enlargement (**Fig. 6.1A**). Of the biphasic P wave in lead V_1 , the initial component is larger (**Fig. 6.1B**). A tall P wave is also known as P pulmonale, since it is often caused by pulmonary hypertension or P congenitale, since it may be observed in congenital heart disease.

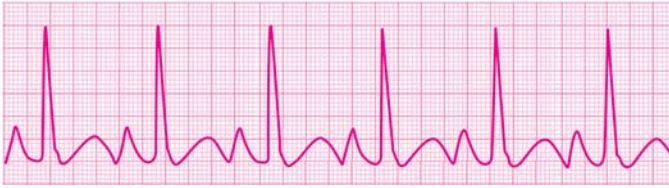

Fig. 6.1A: P. pulmonale: Tall and peaked P wave

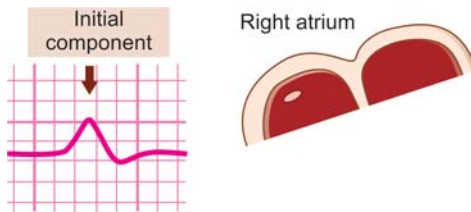


Fig. 6.1B: P wave in V_1 ; large initial component

BROAD P WAVE

The normal P wave is less than 2.5 mm or 0.10 sec in width. It is the sum of right and left atrial activation, right preceding the left. If the left atrium is enlarged, the deflection of the left atrium is further delayed after the right atrial deflection, resulting in a broad P wave exceeding 2.5 mm in width. Also, a notch appears on the P wave, between its right and left atrial components.

Therefore, a broad and notched P wave is representative of left atrial enlargement (**Fig. 6.2A**). Of the biphasic P wave in lead V_1 , the terminal component is larger (**Fig. 6.2B**). A broad and notched P wave is also known as P. mitrale since it is often associated with mitral valve disease.

The common causes of atrial enlargement have been enumerated in **Table 6.1**.

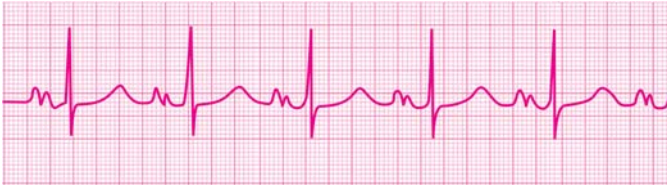

Fig. 6.2A: P. mitrale: Broad and notched P wave

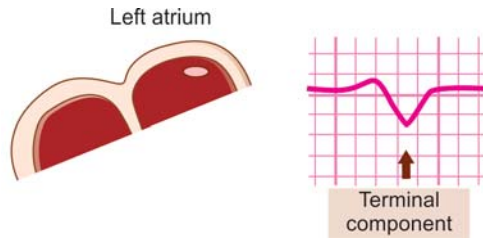


Fig. 6.2B: P wave in V_1 ; large terminal component

Table 6.1: Various causes of atrial enlargement

	<i>Left atrial enlargement</i>	<i>Right atrial enlargement</i>
Intracardiac shunt	Ventricular septal defect (VSD)	Atrial septal defect (ASD)
A-V valve disease	Mitral stenosis Mitral regurgitation	Tricuspid stenosis Tricuspid regurgitation
Outflow obstruction	Aortic stenosis	Pulmonary stenosis
Hypertension	Systemic hypertension	Pulmonary hypertension
Myocardial disease	Cardiomyopathy	Corpulmonale

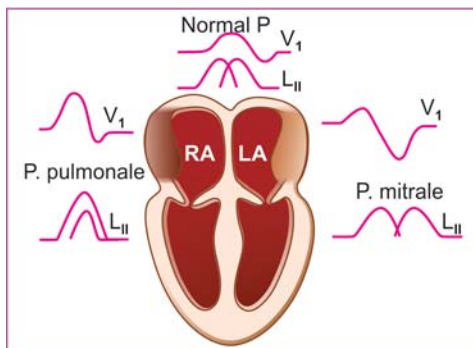


Fig. 6.3: P wave abnormalities in right and left atrial enlargement

The abnormalities of P wave morphology in right atrial and left atrial enlargement are illustrated in **Figure 6.3**.

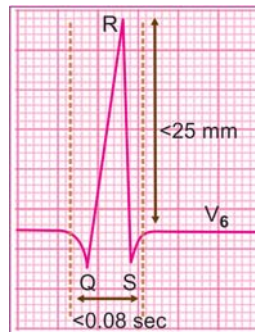
7

Abnormalities of QRS Complex

NORMAL QRS COMPLEX

The QRS complex is produced by ventricular depolarization. It is the sum of synchronized activation of the right and left ventricles. The normal QRS complex meets the following criteria:

- ❖ R wave voltage is at least 5 mm in the limb leads and at least 10 mm in the precordial leads.
- ❖ There is normally no variation in the QRS voltage of consecutive beats in a particular lead.
- ❖ The normal QRS axis ranges from -30° to $+90^\circ$ on the hexaxial reference system.
- ❖ R wave magnitude increases gradually from lead V_1 to lead V_6 representing transition from right ventricular to left ventricular QRS complexes.
- ❖ Physiological q waves are seen in leads L_1 , aVL . They are less than 25 percent of the ensuing R wave in size and less than 0.04 second in duration.
- ❖ R wave voltage does not exceed 4 mm in lead V_1 and is not more than 25 mm in lead V_5 and V_6 .
- ❖ The normal S wave is larger than the r wave in lead V_1 and smaller than the R wave in lead V_6 . It does not exceed a depth of 7 mm in lead V_6 .



60 ECG Made Easy

- ❖ The width of the normal QRS complex does not exceed 0.08 sec or 2 small squares.

LOW-VOLTAGE QRS COMPLEX

The voltage of the R wave in the QRS complex is normally at least 5 mm in the limb leads and at least 10 mm in the precordial leads. If the voltage of the tallest R wave in the limb leads is less than 5 mm and that in the precordial leads is less than 10 mm, the electrocardiogram obtained is called a low voltage graph.

The magnitude of the R wave depends upon the quantum of electrical forces that are generated by the left ventricle as well as on the extent to which these electrical forces are transmitted to the recording electrode.

Therefore, a low voltage graph may be obtained if the myocardium is diseased or if an abnormal substance or tissue intervenes between the epicardial surface of the heart and the recording electrode (**Fig. 7.1**).

Accordingly, the causes of a low voltage ECG graph can be classified as follows:

- ❖ *Due to low voltage generation*
 - Hypothyroidism
 - Constrictive pericarditis
 - Diffuse myocardial disease.

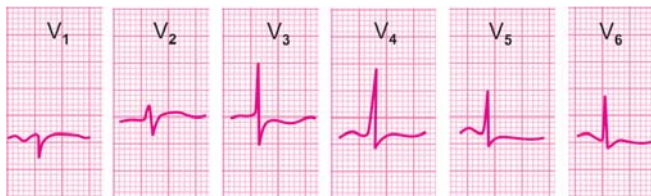


Fig. 7.1: Hypothyroidism: Low voltage graph; T wave inversion

- ❖ *Due to intervening substance/tissue*
 - Adipose tissue in obesity
 - Muscle in thick chest wall
 - Fluid in pericardial effusion
 - Air in pulmonary emphysema.

The cause of a low QRS voltage graph can be assessed by analysis of these parameters:

- ❖ The heart rate
- ❖ The clinical profile
- ❖ The QRS-T shape.

One vital technical point; before the diagnosis of low QRS voltages is made, it must be ensured that the ECG machine has been properly standardized. Accurate standardization means that a one millivolt current produces a 10 mm tall deflection.

ALTERNATING QRS VOLTAGE

Normally, in a given lead, the voltage of all the QRS complexes is the same. This is because all beats originate from one pacemaker and the voltage has no relation to respiration or any other periodic extracardiac phenomenon.

If the voltage of QRS complexes alternates between high and low in successive beats, the condition is known as electrical alternans (**Fig. 7.2**). Total electrical alternans refers to a condition wherein, the voltage of the P wave, T wave and QRS complex are all variable from beat-to-beat.

Electrical alternans is caused either by a positional oscillation of the heart within a fluid-filled pericardial sac or a beat-to-beat variation in the aberrancy of intraventricular conduction. Accordingly, the causes of electrical alternans are:

- ❖ Moderate to severe pericardial effusion
 - Malignant
 - Tubercular
 - Post-surgical.

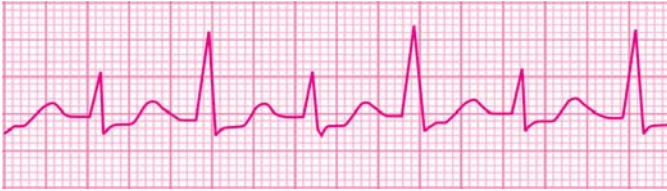

Fig. 7.2: Electrical alternans: Varying voltage of the QRS complex

- ❖ Serious organic heart disease
 - Ischemic cardiomyopathy
 - Diffuse myocarditis.

Total electrical alternans is highly suggestive of moderate to severe pericardial effusion with cardiac tamponade or impending tamponade. Electrical alternans of the QRS complex is often clinically associated with cardiomegaly, gallop rhythm and signs of left ventricular decompensation.

ABNORMAL QRS AXIS

The dominant direction of the net electrical forces constitutes the electrical axis of the QRS complex. Normally, these forces are so directed that the QRS axis is in the range of -30° to $+90^{\circ}$ on the hexaxial reference system.

In other words, the QRS axis falls in the right lower quadrant of the hexaxial system. This means that the main QRS deflection in both leads L_1 as well as aVF is upright. This is also known as the “2 thumbs-up sign”.

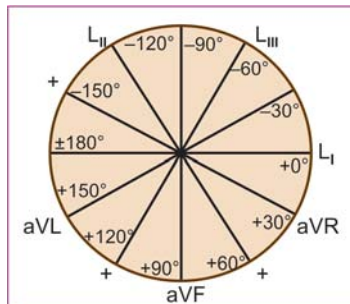


Table 7.1: QRS electrical axis from the hexaxial system

<i>QRS axis</i>	<i>Range in degrees</i>
Normal axis	-30° to $+90^\circ$
Left axis deviation	-30° to -90°
Right axis deviation	$+90^\circ$ to $+180^\circ$
Indeterminate axis	-90° to -180°

Abnormalities of the QRS axis include:

- ❖ Right axis deviation
- ❖ Left axis deviation
- ❖ Indeterminate axis.

On a scale of 360 degrees (0° to $+180^\circ$ and 0° to -180°), the entire hexaxial system is used to qualify the QRS axis as shown in **Table 7.1**.

We have seen that although the QRS axis is generally calculated mathematically, we can know the quadrant into which the axis falls by scanning the direction of the main deflection (positive or negative) in leads L_1 and aVF. Accordingly, the QRS axis can be classified as in **Table 7.2**.

Table 7.2: QRS electrical axis from the leads L_1 and aVF

<i>Main deflection in</i>		<i>QRS quadrant</i>	<i>QRS axis</i>
<i>L_1</i>	<i>aVF</i>		
+ve	+ve	Right lower	0° to $+90^\circ$
+ve	-ve	Right upper	0° to -90°
-ve	+ve	Left lower	$+90^\circ$ to $+180^\circ$
-ve	-ve	Left upper	-90° to -180°

64 ECG Made Easy

The causes of deviation of the QRS axis are:

❖ *Right Axis Deviation*

- Thin tall built
- Right ventricular hypertrophy
- Left posterior hemiblock
- Anterolateral infarction
- Chronic lung disease
- Pulmonary embolism
- Ostium secundum ASD

❖ *Left Axis Deviation*

- Obese stocky built
- Left ventricular hypertrophy
- Left anterior hemiblock
- Inferior wall infarction
- WPW syndrome
- Ostium primum ASD
- External cardiac pacing.

❖ *Indeterminate (North-West) Axis*

- Severe right ventricular hypertrophy
- Aneurysm of left ventricular apex.

Deviation of the QRS axis can occur due to various physiological as well as pathological causes. Age and body habitus are important determinants of the QRS axis.

Minor right axis deviation can occur in thin, lean children and adolescents. Minor left axis deviation is normal in obese adults and with abdominal distension due to pregnancy or ascites.

FASCICULAR BLOCK OR HEMIBLOCK

The intraventricular conducting system consists of a bundle of His which divides into right and left bundle branches. The left bundle branch further divides into an anterior fascicle and a posterior fascicle.

A block in conduction down one of the fascicles results in abnormal left ventricular activation known as hemiblock. Thus, we have left anterior hemiblock and left posterior hemiblock. A hemiblock produces significant deviation of the QRS axis.

In left anterior hemiblock, there is qR pattern in lead L₁ and rS pattern in lead aVF or left axis deviation (**Fig. 7.3A**).

In left posterior hemiblock, there is rS pattern in lead L₁ and qR pattern in lead aVF or right axis deviation (**Fig. 7.3B**).

Left anterior hemiblock (LAHB) may be observed in:

- ❖ Hypertension with LV hypertrophy
- ❖ Calcification from aortic valve
- ❖ Chronic coronary insufficiency
- ❖ Chronic dilated cardiomyopathy
- ❖ Fibrocalcerous degeneration.

LAHB is more common and often occurs alone. This is because the anterior fascicle is long, thin, has a single blood supply and commonly gets involved in diseases affecting the septum and aortic valve.

Left posterior hemiblock (LPHB) may be observed in:

- ❖ Inferior wall infarction
- ❖ Right bundle branch block.

LPHB is less common and rarely occurs alone. This is because the posterior fascicle is short, thick, has a dual blood supply and is uncommonly involved in diseases affecting the septum and aortic valve.

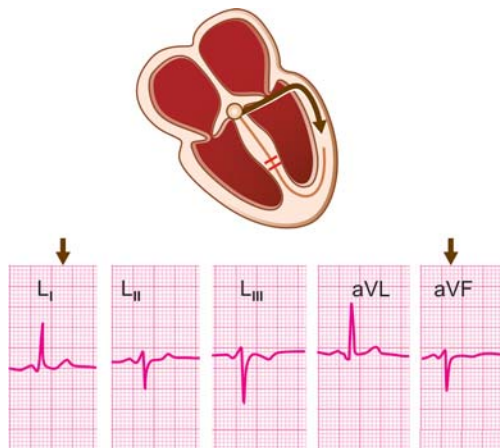


Fig. 7.3A: Left axis deviation: Left anterior fascicular block

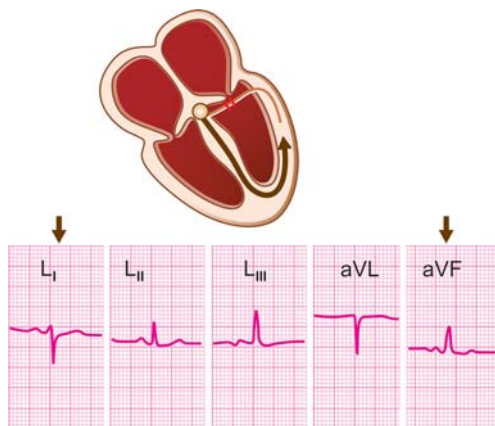


Fig. 7.3B: Right axis deviation: Left posterior fascicular block

NON-PROGRESSION OF R WAVE

Normally, as we move across the precordial leads from lead V_1 to lead V_6 , there is a progressive increase in R wave voltage. This is because the right ventricular leads V_1V_2 record rS complexes while the left ventricular leads V_5V_6 record qR complexes.

The change from rS pattern to qR pattern generally occurs in lead V_3 or V_4 , which is known as the transition zone.

In the transition zone, the QRS complex is isoelectric with the R wave height and S wave depth being almost equal (**Fig. 7.4A**).

The vector can rotate in the horizontal plane with the transitional QRS moving towards the patient's right or left. When it moves to the right (into leads V_1, V_2) this is rightward rotation. When it moves to the left (into leads V_5, V_6) this is leftward rotation. As a rule, the vector shifts towards ventricular hypertrophy and away from myocardial infarction.

Failure of the R wave voltage to increase progressively from lead V_1 to lead V_6 is referred to as non-progression of the R wave (**Fig. 7.4B**) or leftward rotation.

The causes of non-progression of the R wave are:

- ❖ Chronic lung disease
- ❖ Old anteroseptal infarction
- ❖ Diffuse myocardial disease
- ❖ Left ventricular hypertrophy
- ❖ Left bundle branch block.

Non-progression of the R wave in precordial leads can occur due to a variety of causes. Knowledge of this fact can avoid the overdiagnosis of ominous conditions like old myocardial infarction.

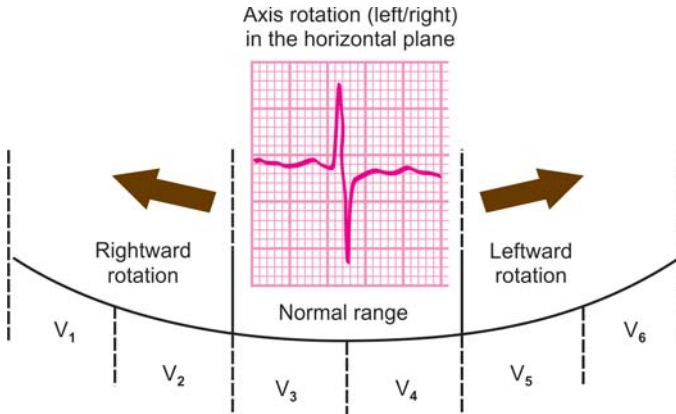


Fig. 7.4A: Rotation of the vector and shift of transition zone

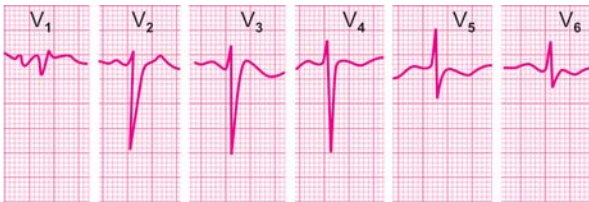

Fig. 7.4B: Non-progression of R wave in the precordial leads

Even improper placement of chest electrodes can produce this striking abnormality, particularly in the setting of a medical emergency!!

ABNORMAL Q WAVES

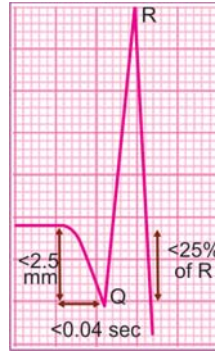The Q waves are not visible in all ECG leads. Rather, they are normally visible in selected leads where they represent initial septal activation in a direction opposite to activation of the main left ventricular mass.

Physiological Q waves are observed in:

- ❖ Leads L_I , aVL , with horizontal heart
- ❖ Leads L_{III} , aVF with vertical heart

Criteria for physiological Q waves are:

- ❖ They do not exceed 0.04 sec in duration
- ❖ They do not exceed one-fourth of R wave height.



Pathological Q waves are most commonly due to necrosis of heart muscle or myocardial infarction. This is a result of occlusion of a coronary artery by a thrombus (Fig. 7.5). Why pathological Q waves appear in myocardial infarction needs to be understood. Infarcted (necrotic) myocardial tissue is electrically inert and does not get depolarized. If an electrode is placed over this “electrical hole” or “void”, it records

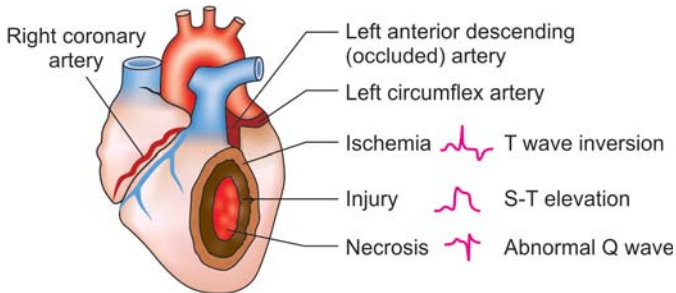


Fig. 7.5: Zones of myocardial infarction and their ECG effects

70 ECG Made Easy

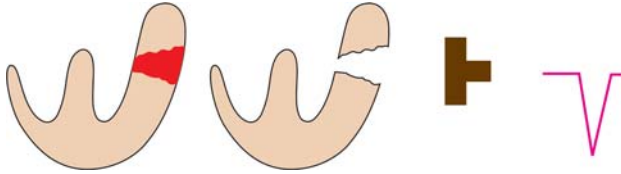


Fig. 7.6: Electrode placed over transmural infarct records negative deflection: The “electrical hole” effect

depolarization of the opposite ventricular wall from the endocardium to the epicardium.

Since, this direction of depolarization is away from the electrode, the recorded deflection is negative and is called the Q wave (**Fig. 7.6**). The Q wave may be followed by a small r wave or there may be an entirely negative deflection called the QS complex.

Pathological Q waves meet the following criteria:

- ❖ More than or equal to 0.04 sec in duration
- ❖ More than one-fourth of R wave amplitude
- ❖ Present in leads besides those with normal q waves
- ❖ Present in several leads and not an isolated lead.

Pathological Q waves occur commonly but not always due to myocardial infarction. Severe reversible myocardial ischemia as in severe angina, hypoxia, hypothermia or hypoglycemia may cause transient appearance of Q waves.

Absence of Q waves does not rule out the possibility of myocardial infarction. Q waves may be absent in the following types of infarction: small infarction, right ventricular infarction, posterior wall infarction, atrial infarction and fresh infarction with delayed ECG changes.

The location of Q waves can help to localize the area of infarction as tabulated in **Table 7.3**.

Table 7.3: Area of infarction determined from Q wave location

<i>Location of Q wave</i>	<i>Area of infarction</i>
V_1V_2	Septal
V_3V_4	Anterior
$V_5V_6L_1aVL$	Lateral
V_{1-4}	Anteroseptal
$V_{3-6}L_1aVL$	Anterolateral
$V_{1-6}L_1aVL$	Extensive anterior
L_1aVL	High lateral
$L_{II}L_{III}aVF$	Inferior

ABNORMALLY TALL R WAVES

The r wave voltage in lead V_1 represents rightward forces while the R wave height in lead V_6 represents left ventricular forces. Normally, the R wave amplitude does not exceed 4 mm in lead V_1 and does not exceed 25 mm in lead V_6 . Also, the R wave height is less than S wave depth (R/S ratio less than 1) in lead V_1 and more than the S wave depth (R/S ratio more than 1) in lead V_6 .

A R wave greater than 4 mm in lead V_1 is considered tall. Causes of tall R waves in lead V_1 are:

- ❖ Right ventricular hypertrophy
- ❖ Right bundle branch block
- ❖ Persistent juvenile pattern
- ❖ True posterior wall infarction
- ❖ Mirror-image dextrocardia
- ❖ Pre-excitation (WPW syndrome)
- ❖ Duchenne muscular dystrophy.

72 ECG Made Easy

A R wave greater than 25 mm in lead V_6 is considered tall. Causes of tall R waves in lead V_6 are:

- ❖ Left ventricular hypertrophy
- ❖ Left bundle branch block.

Right Ventricular Hypertrophy (RVH)

The QRS complex represents ventricular depolarization. Therefore, the tall R wave in lead V_1 in right ventricular hypertrophy, reflects the increased electrical forces generated by the thickened right ventricular myocardium.

The voltage criteria of RVH are:

- ❖ R wave in V_1 more than 4 mm
- ❖ R/S ratio in V_1 more than 1
- ❖ S wave in V_6 more than 7 mm
- ❖ R in V_1 + S in V_6 more than 10 mm.

Besides voltage criteria, other features of RVH are:

- ❖ Right axis deviation of the QRS complex
- ❖ Right atrial enlargement: P. pulmonale
- ❖ S-T segment depression and T wave inversion in leads V_1 and V_2 : the RV strain pattern (**Fig. 7.7**).

The causes of RVH can be classified into causes of pulmonary hypertension and those of pulmonary stenosis. These are:

- ❖ *Pulmonary Hypertension*
 - Congenital heart disease (intracardiac shunt)
 - Mitral valve disease (stenosis or regurgitation)
 - Chronic pulmonary disease (cor pulmonale)
 - Primary pulmonary hypertension (idiopathic).
- ❖ *Pulmonary Stenosis (PS)*
 - Isolated congenital PS
 - PS of Fallot's tetralogy.

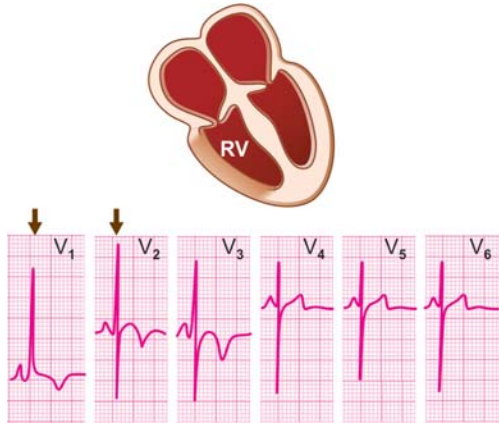


Fig. 7.7: Right ventricular hypertrophy:
Tall R wave in V_1 to V_3
rS pattern in V_4 to V_6

In pulmonary hypertension, there is increased resistance to blood flow in the pulmonary vasculature. In pulmonary stenosis, there is obstruction to right ventricular outflow at the level of pulmonary valve.

Right ventricular hypertrophy is common but by no means, the only cause of tall R waves in lead V_1 . It needs to be differentiated from the following conditions that also produce tall R waves in lead V_1 .

Persistent Juvenile Pattern

The right ventricle is the dominant ventricle in childhood. Sometimes, the juvenile pattern of right ventricular dominance persists into adulthood to cause a dominantly upright deflection in lead V_1 .

Right Bundle Branch Block (RBBB)

In RBBB, the dominant deflection in lead V_1 is upright. But close analysis of the QRS complex reveals a wide deflection

74 ECG Made Easy

(>0.12 sec in width) with a triphasic contour that produces a M-pattern or RsR' configuration.

Posterior Wall Infarction

None of the electrocardiographic leads is oriented towards the posterior wall of the heart. Therefore, the diagnosis of posterior wall infarction is made from the inverse of classical changes of infarction in lead V₁.

These include a tall R wave and an upright T wave which are the reverse of a deep Q wave and an inverted T wave. Note that posterior wall infarction is the only cause of tall R wave in V₁ in which the T wave is also tall and upright.

Mirror-image Dextrocardia

In mirror-image dextrocardia, since the heart lies in the right side of the chest and lead V₁ overlies the left ventricle, the R wave is tallest in lead V₁ and diminishes towards lead V₆.

The WPW Syndrome

The WPW syndrome or pre-excitation syndrome is often associated with upright QRS complexes in right precordial leads V₁, V₂. Other electrocardiographic features of WPW syndrome include a short P-R interval and a delta wave deforming the normally smooth ascending limb of the R wave.

Left Ventricular Hypertrophy (LVH)

The QRS complex represents ventricular depolarization. Therefore, the tall R wave in lead V₅ in left ventricular hypertrophy reflects the increased electrical forces generated by the thickened left ventricular myocardium.

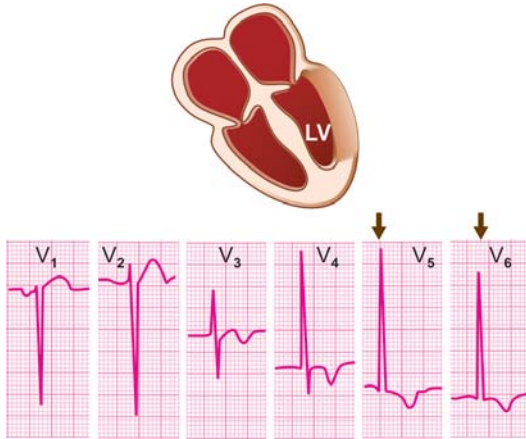


Fig. 7.8: Left ventricular hypertrophy:
Tall R wave in V_5, V_6
Deep S wave in V_1, V_2

The voltage criteria of LVH are:

- ❖ S in $V_1 + R$ in (V_5 or V_6) > 35 mm (Sokolow)
- ❖ R in $V_4-V_6 > 25$ mm; R in $aVL > 11$ mm (Framingham)
- ❖ S in $V_3 + R$ in $aVL > 28$ mm in men (Cornell)
(> 20 mm in women)

Besides voltage criteria, other features of LVH are:

- ❖ Left axis deviation of the QRS complex
- ❖ Left atrial enlargement: P mitrale
- ❖ S-T segment depression and T wave inversion in leads V_5 and V_6 : LV strain pattern (**Fig. 7.8**).

The causes of LVH can be classified into causes of systolic LV overload and those of diastolic LV overload. These are:

76 ECG Made Easy

- ❖ *Systolic LV Overload*
 - Systemic hypertension
 - Aortic stenosis
 - Valvular
 - Subvalvular
 - Coarctation of aorta
 - Hypertrophic cardiomyopathy
- ❖ *Diastolic LV Overload*
 - Aortic regurgitation
 - Mitral incompetence
 - Ventricular septal defect
 - Patent ductus arteriosus.

In systolic overload, there is increased resistance to outflow of arterial blood from the left ventricle. In diastolic overload, there is an increased inflow of venous blood to the left ventricle.

Left ventricular hypertrophy is a common but by no means, the only cause of tall R wave in V_6 . It needs to be differentiated from other conditions that cause tall R wave.

- ❖ *Voltage criteria alone* The voltage criteria of LVH can be fulfilled by high cardiac output states such as anemia, thyrotoxicosis and beri-beri. Similarly, strenuous exercisers, conditioned athletes and marathon runners can have tall R waves in lead V_6 .

However, in these conditions, the voltage criteria are not accompanied by other ECG features of LVH such as left axis deviation, strain pattern or P. mitrale. Moreover, their clinical evaluation is unremarkable. Therefore, one must be careful before diagnosing left ventricular hypertrophy by voltage criteria alone.

- ❖ *Left bundle branch block (LBBB)* In LBBB, the QRS deflection in lead V_6 is tall. But close analysis of the QRS

complex reveals a wide deflection (> 0.12 sec in width) with a triphasic contour that produces a M-pattern or RsR' configuration.

- ❖ *Left ventricular diastolic overload* In true left ventricular hypertrophy or systolic overload, the tall R wave without a preceding Q wave is classically associated with depression of the S-T segment and inversion of the T wave, the so called left ventricular strain pattern.

Left ventricular diastolic overload can be differentiated from systolic overload by certain subtle differences. In diastolic overload, the tall R wave is preceded by a deep narrow Q wave and associated with a tall and upright T wave.

ABNORMALLY DEEP S WAVES

The S wave in lead V_1 represents left ventricular activation while in lead V_6 it represents right ventricular activation. Normally, the S wave depth in lead V_1 is greater than the r wave height. Also, the s wave is much smaller than the R wave in lead V_6 and does not exceed 7 mm in depth.

In lead V_1 , if the s wave is smaller than the R wave and the R/S ratio is greater than 1, it indicates right ventricular dominance or hypertrophy (**Fig. 7.7**). If the sum of S wave voltage in lead V_1 and R wave voltage in lead V_6 exceeds 35 mm, it indicates left ventricular hypertrophy (**Fig. 7.8**).

It is interesting to note that the lead V_1 provides a wealth of information concerning hypertrophy of the cardiac chambers.

- ❖ LV hypertrophy : deep S wave, small r wave
- ❖ RV hypertrophy : tall R wave small s wave
- ❖ LA enlargement : large terminal P component
- ❖ RA enlargement : large initial P component

ABNORMALLY WIDE QRS COMPLEXES

The QRS complex represents depolarization of the entire ventricular myocardium. Since the right and left ventricles are depolarized in a synchronous fashion, the normal QRS width does not exceed 0.04 to 0.08 sec (1 to 2 small squares) on the horizontal or time axis.

If the QRS complex is wider than 0.08 sec, it means that either the two ventricles are activated asynchronously or ventricular conduction is slow. Causes of wide QRS complexes are:

- ❖ Bundle branch block
 - Right bundle branch block
 - Left bundle branch block
- ❖ Intraventricular conduction defect
 - Antiarrhythmic drugs, e.g. amiodarone
 - Electrolyte imbalance, e.g. hyperkalemia
 - Myocardial disease, e.g. myocarditis
- ❖ Ventricular pre-excitation
 - WPW syndrome
 - LGL syndrome
- ❖ Wide QRS arrhythmias
 - Supraventricular tachycardia with aberrant Ventricular conduction
 - Atrial fibrillation with accessory pathway Ventricular tachycardia.

The causes of wide QRS complexes can also be classified according to the width of the complexes:

- ❖ *QRS width 0.09-0.10 sec*
 - Left anterior or posterior hemiblock
 - Partial intraventricular conduction defect

- ❖ *QRS width 0.11-0.12 sec*
 - Incomplete bundle branch block
 - Intraventricular conduction defect
 - Ventricular pre-excitation syndrome
- ❖ *QRS width > 0.12 sec*
 - Bundle branch block
 - Wide QRS arrhythmias.

Bundle Branch Block

Bundle branch block denotes a delay or block of conduction down one of the two branches of the bundle of His. Accordingly, we can have right bundle branch block (RBBB) or left bundle branch block (LBBB). Bundle branch block produces widening of the QRS complex because of delayed activation of one of the ventricles, right ventricle in RBBB and left ventricle in LBBB. Depolarization of the blocked ventricle occurs slowly through the myocardium and not by the specialized conduction system.

An incomplete bundle branch block results in a QRS width of 0.11 to 0.12 sec while in a complete block the QRS width exceeds 0.12 sec. Bundle branch block produces a RSR' pattern or M-shaped QRS deflection with two peaks. The QRS complexes of the ventricles are "out of sync" with each other and produce two R waves in sequential order.

In RBBB, the RSR' pattern is observed in lead V_1 , the R' wave representing delayed right ventricular activation (**Fig. 7.9**). In LBBB, the M-shaped pattern is observed in lead V_6 , the notched R wave representing delayed left ventricular activation (**Fig. 7.10**). The RSR' complex is followed by S-T segment depression and T wave inversion which together constitute secondary ST-T changes of bundle branch block.

Bundle branch block often indicates organic heart disease, more so LBBB. On the other hand, RBBB is occasionally

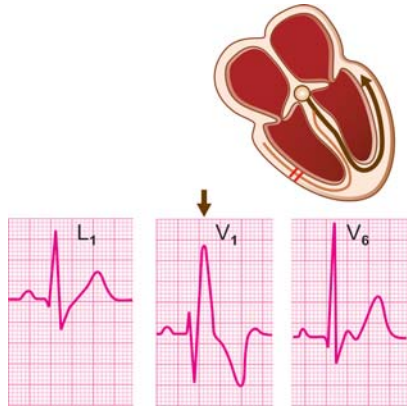


Fig. 7.9: Right bundle branch block: M-shaped complex in V₁ slurred S wave in L₁, V₆

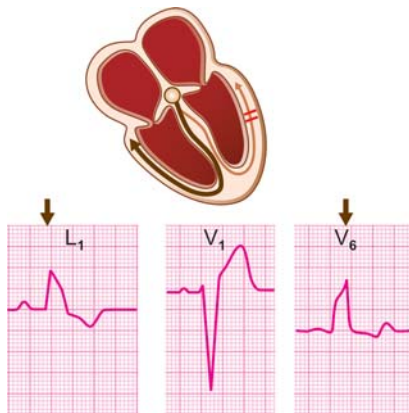


Fig. 7.10: Left bundle branch block: M-shaped complex in L₁, V₆ wide QS complex in V₁ to V₄

observed in normal individuals. Causes of left bundle branch block are:

- ❖ Myocardial infarction (recent or healed)
- ❖ Systemic hypertension (long-standing)
- ❖ Aortic valve disease (calcific stenosis)
- ❖ Cardiomyopathy (or acute myocarditis)
- ❖ Fibrocalcerous disease (degenerative)
- ❖ Cardiac trauma (accidental or surgical).

Causes of right bundle branch block, besides those mentioned above are:

- ❖ Atrial septal defect
 - Ostium secundum : incomplete RBBB
 - Ostium primum : RBBB + LAHB
- ❖ Acute pulmonary embolism
- ❖ Arrhythmogenic RV dysplasia
- ❖ Chronic pulmonary disease.

RBBB does not distort the QRS complex but only adds a terminal deflection which is the R' wave in leads V_1 , V_2 and slurred S wave in leads L_1 , V_6 . On the other hand, LBBB totally distorts the QRS complex. Therefore, it is possible to diagnose myocardial infarction in the presence of RBBB but difficult in the presence of LBBB. Criteria for the diagnosis of myocardial infarction in the presence of LBBB are:

- ❖ Presence of Q wave in L_1 , aVL, V_5 , V_6
- ❖ Terminal S wave in the leads V_5 , V_6
- ❖ Upright T wave concordant with QRS
- ❖ S-T drift > 5 mm discordant with QRS.

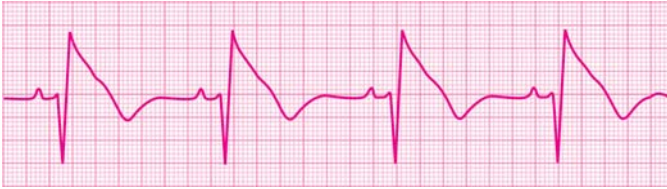

Fig. 7.11: The Brugada Syndrome:
rSR' pattern in lead V₁
normal rSR' duration
elevated S-T segment
inverted T wave

The Brugada Syndrome

The Brugada syndrome also produces a rSR' pattern in lead V₁ with saddle-back shaped S-T elevation and T wave inversion, which superficially resembles a RBBB pattern (**Fig. 7.11**). But unlike in RBBB, the rSR' is not more than 0.12 sec wide and there are no slurred S waves in leads L₁ and V₆.

The Brugada syndrome is a rare congenital disorder of sodium transport, across ion channels in the right ventricle. Patients with this condition are prone to develop episodic syncope due to ventricular tachycardia or even cardiac arrest due to ventricular fibrillation. The genetic defect underlying Brugada syndrome may exist in several family members (autosomal dominant inheritance) and forms the basis of familial malignant ventricular arrhythmias requiring an implantable cardioverter defibrillator (ICD).

Brugada syndrome belongs to a group of congenital channelopathies responsible for 5-10% of cases of sudden cardiac death (SCD). Other channelopathies are long Q-T syndrome (LQTS) and catecholaminergic ventricular tachycardia (CVT).

Arrhythmogenic RV Dysplasia

Arrhythmogenic right ventricular dysplasia (ARVD) produces incomplete right bundle branch block (RBBB) pattern, with a post-depolarization epsilon wave at the end of the QRS complex, best seen in lead V_1 . There is also T wave inversion in the right precordial leads V_1 to V_4 .

Echocardiography reveals a mildly dilated right ventricle with akinetic regions due to substitution of portions of the right ventricular musculature with fibrotic adipose tissue. A definitive diagnosis of ARVD comes from magnetic resonance imaging (MRI). Electrophysiology study demonstrates inducible polymorphic ventricular tachycardia. These patients merit life-long arrhythmia prophylaxis with a beta-blocker or an implantable cardioverter defibrillator (ICD).

Acute Pulmonary Embolism

Pulmonary embolism causing acute cor pulmonale, is a prominent cause of acute onset right bundle branch block. Various ECG features of acute pulmonary embolism are:

- ❖ Sinus tachycardia (invariable)
- ❖ Atrial fibrillation (occasional)
- ❖ Incomplete/complete RBBB
- ❖ T wave inversion V_1 to V_3
- ❖ Tall P wave—P. pulmonale
- ❖ An $S_1Q_3T_3$ pattern
 - prominent S in L_1
 - significant Q in L_{III}
 - inversion of T in L_{III}

Chronic Pulmonary Disease

Chronic obstructive pulmonary disease (COPD) with cor pulmonale can also cause right bundle branch block (RBBB). Various ECG features of COPD are:

84 ECG Made Easy

- ❖ Low voltage QRS complexes
- ❖ Right ventricular hypertrophy
- ❖ Right atrial enlargement
- ❖ Rightward QRS axis deviation
- ❖ Atrial fibrillation (AF) or even multifocal atrial tachycardia.

Intraventricular Conduction Defect

An intraventricular conduction defect (IVCD) refers to a delay or block in conduction in the Purkinje system, distal to the bundle branches. It produces widening of the QRS complex since the ventricular muscle has to be activated through ordinary myocardium instead of the specialized conduction tissue. As we have seen earlier, an IVCD may occur due to anti-arrhythmic drugs, electrolyte imbalance or primary myocardial disease.

Antiarrhythmic drugs such as amiodarone, widen the QRS complex. A widening beyond 25 percent of the baseline value is an indication of drug toxicity.

Other ECG effects of antiarrhythmic drugs are:

- ❖ S-T depression and T inversion
- ❖ Prolongation of Q-T interval
- ❖ Prominence of U wave (**Fig. 7.12**).

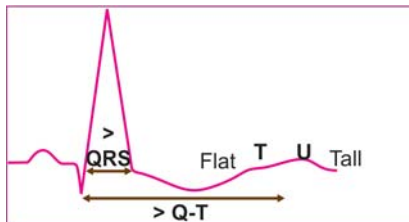


Fig. 7.12: Effects of amiodarone

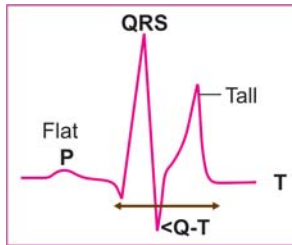


Fig. 7.13: Effects of hyperkalemia

Hyperkalemia if severe (serum K^+ more than 9 mEq/L), results in a QRS complex that is wide and bizarre.

Other ECG features of hyperkalemia are:

- ❖ Tall peaked T waves
- ❖ Short Q-T interval
- ❖ Flat P waves (**Fig. 7.13**).

Disease processes primarily affecting the myocardium such as cardiomyopathy or myocarditis produce total distortion and widening of the QRS complex. Low voltages of these complexes may cause poor progression of R wave in precordial leads.

Ventricular Pre-excitation (WPW Syndrome)

The WPW syndrome is an entity in which an accessory pathway or by-pass tract called the bundle of Kent connects the atrial to the ventricular myocardium, without passing through the A-V node.

Conduction of impulses down this tract results in premature ventricular activation, also called pre-excitation, since the A-V nodal delay is by-passed. Conduction of an impulse through the usual conduction system follows the pre-excitation. The WPW syndrome is associated with the following ECG features:

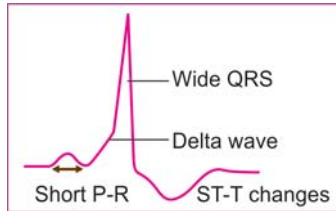


Fig. 7.14: The WPW syndrome

- ❖ *Wide QRS complex* The QRS complex is wide since it is the sum of ventricular pre-excitation by the accessory pathway and normal ventricular activation.
- ❖ *Delta wave* Pre-excitation of the ventricle produces a slur on the ascending limb of R wave, termed the delta wave.
- ❖ *Short P-R interval* The P-R interval is short because ventricular depolarization begins early after the P wave, having by-passed the A-V nodal delay.
- ❖ *ST-T changes* S-T segment depression and T wave inversion are secondary to the abnormality of the QRS complex (**Fig. 7.14**).

The clinical significance of WPW syndrome lies in the fact that it predisposes an individual to arrhythmias particularly paroxysmal atrial tachycardia, atrial fibrillation and even ventricular tachycardia. WPW syndrome is a masquerader of several cardiac conditions. These are:

- ❖ Delta wave appearing separate from the R wave mimics bundle branch block.
- ❖ Dominant R wave in lead V_1 resembles pattern of right ventricular hypertrophy.
- ❖ Negative delta waves with ST-T changes give the impression of myocardial infarction.
- ❖ Antidromic AV reentrant tachycardia conducted antero-gradely through the accessory pathway may be mistaken for ventricular tachycardia.

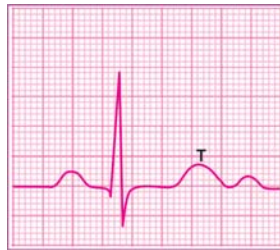8

Abnormalities of the T Wave

NORMAL T WAVE

The T wave is produced by the rapid phase of ventricular repolarization and follows the QRS complex. The normal T wave fulfills the following criteria:

- ❖ It is upright in most leads (except aVR, L_{III}, V₁)
- ❖ It is taller in V₆ than in lead V₁ and taller in L_I than in lead L_{III}
- ❖ It does not exceed 5 mm in height in the limb leads and 10 mm in precordial leads.



INVERTED T WAVE

The T wave is considered to be the most unstable component of the ECG graph. Therefore, change in polarity of the T wave or T wave inversion is one of the most common ECG abnormalities.

The significance of flattening or reduction in height of the T wave is similar to that of T wave inversion. Since inversion of the T wave is often associated with depression of the S-T segment, together they are referred to as ST-T changes.

As the T wave is an unstable deflection, it is not surprising that T wave inversion can be caused by a wide variety of etiological

88 ECG Made Easy

factors. The causes of T wave inversion can be classified as follows:

NON-SPECIFIC CAUSES

- ❖ *Physiological states*
 - Heavy meals
 - Smoking
 - Anxiety
 - Tachycardia
 - Hyperventilation
- ❖ *Extra-cardiac disorders*
 - Systemic, e.g. hemorrhage, shock
 - Cranial, e.g. cerebrovascular accident
 - Abdominal, e.g. pancreatitis, cholecystitis
 - Respiratory, e.g. pulmonary embolism
 - Endocrine, e.g. hypothyroidism.

SPECIFIC CAUSES

- ❖ *Primary abnormality*
 - Pharmacological, e.g. digitalis, quinidine
 - Metabolic, e.g. hypokalemia, hypothermia
 - Myocardial, e.g. cardiomyopathy, myocarditis
 - Pericardial, e.g. pericarditis, pericardial effusion
 - Ischemic, e.g. coronary insufficiency, infarction
- ❖ *Secondary abnormality*
 - Ventricular hypertrophy
 - Bundle branch block
 - WPW syndrome.

T wave inversion lacks specificity as a diagnostic indicator. Since inversion of the T wave can be caused by certain

physiological states and non-cardiac diseases, it highlights the importance of viewing T inversion in the light of clinical data.

One should be careful before diagnosing myocardial ischemia only by ECG criteria. T wave inversion should be interpreted carefully in the presence of upper abdominal and respiratory diseases, when the clinical picture may be confused with that of heart disease.

A cerebrovascular accident such as cerebral thrombosis or intracranial bleed, may be associated with T wave inversion for which there are several reasons. One, there may be concomitant coronary artery disease due to common atherosclerotic risk factors. Two, the neurogenic stress response to stroke may cause acute hypertension and coronary vasoconstriction. Three, a left ventricular mural thrombus in an aneurysm may be the source of cerebral embolism.

Cardiovascular drugs like digitalis and amiodarone can cause T wave inversion and S-T segment depression. With digitalis therapy, the S-T segment and T wave resemble the mirror-image of the correction mark sign (∩) (Fig. 8.1A).

When these changes are confined to leads V_5 , V_6 , they indicate digitalis administration. Changes occurring in most leads are suggestive of digitalis intoxication.

Antiarrhythmic drugs also causes T wave inversion and S-T segment depression but unlike digitalis, they also widen the QRS complex and prolong the Q-T interval (Fig. 8.1B).

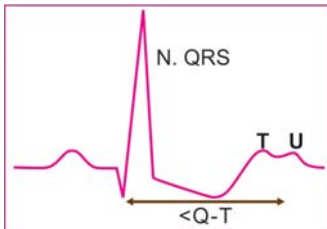


Fig. 8.1A: Effects of digitalis

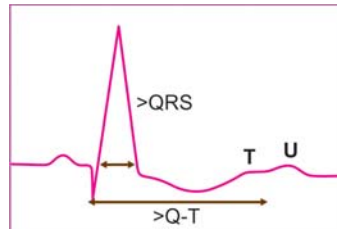


Fig. 8.1B: Effects of amiodarone

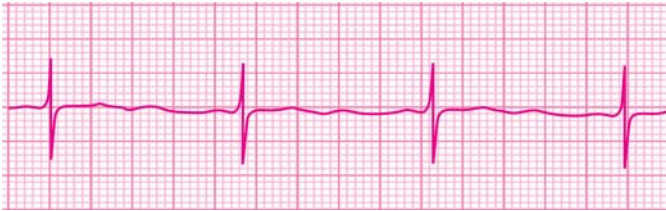

Fig. 8.2A: Effect of hypokalemia on the T wave

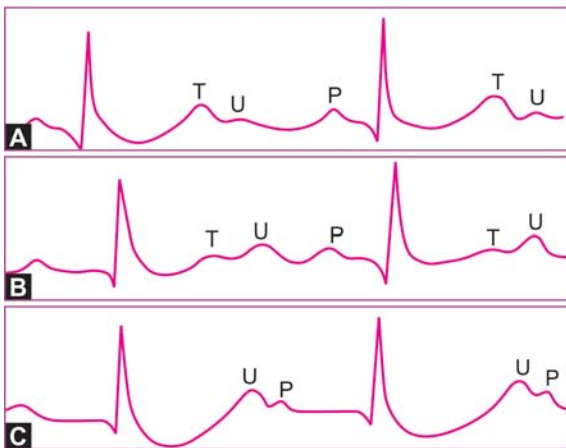


Fig. 8.2B: Effects of progressively increasing hypokalemia

Hypokalemia is an important cause of T wave change. The T wave is either reduced in amplitude, flattened or inverted. This is associated with prominence of the U wave that follows the T wave (Fig. 8.2A). A low T wave followed by a prominent U wave produces a 'camel-hump' effect while a flat T with a prominent U falsely suggests prolongation of the Q-T interval (Fig. 8.2B).

Causes of hypokalemia include dietary deficiency of potassium, gastrointestinal losses in the form of vomiting and diarrhea as well as diuretic and steroid therapy. The importance of hypokalemia in cardiac patients on diuretic treatment lies in the

fact that hypokalemia can precipitate digitalis toxicity and initiate ventricular tachyarrhythmias such as Torsades de Pointes.

Clinical features of hypokalemia are fatigue, leg cramps and neuromuscular paralysis. Treatment of hypokalemia is potassium administration, either dietary or pharmacological and correction of the underlying cause.

Primary diseases of the myocardium such as cardiomyopathy and acute myocarditis produce T wave inversion and S-T segment depression. These changes are often associated with wide QRS complexes due to intraventricular conduction defect.

During the acute stage of pericarditis, the S-T segment is elevated and the T wave is upright. Once the S-T segment has returned to the baseline, the T wave undergoes inversion that may persist for a long time.

In pericardial effusion, T wave inversion is associated with low voltage QRS complexes. A similar pattern is observed in hypothyroidism (myxedema) with the difference that while pericardial effusion causes tachycardia, hypothyroidism is accompanied by bradycardia.

Clinically speaking, coronary artery disease with myocardial ischemia or infarction is the most important cause of T wave inversion. Acute coronary insufficiency produces coving (convexity) of the S-T segment and T wave inversion (**Fig. 8.3**). In non-Q myocardial infarction, a similar pattern is observed.

The two conditions can be differentiated by the fact that in acute coronary insufficiency, the chest pain is of short duration, cardiac enzyme titers (CPK, SGOT) are normal and the ECG changes rapidly revert to normal with treatment. In non-Q myocardial infarction, there is history of prolonged chest pain, blood levels of cardiac enzymes are raised and the ECG changes persist for a longer period.

In the fully evolved phase of Q-wave myocardial infarction, T wave inversion is associated with elevation (convex upwards) of the S-T segment (**Fig. 8.3**). This is in contrast to the T wave inversion observed in pericarditis which occurs after the elevated

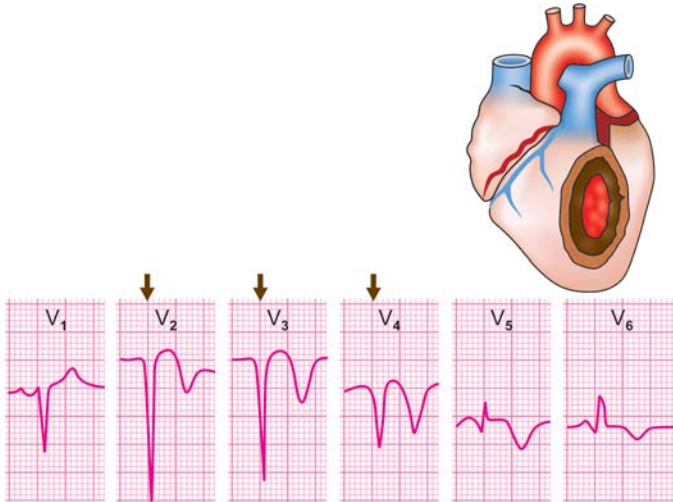


Fig. 8.3: Acute extensive anterior wall myocardial infarction fully evolved phase: QS in V₁ to V₄; qR in V₅ to V₆

(concave upwards) S-T segment has nearly returned to the baseline.

The inverted T wave of ischemic heart disease (coronary insufficiency or myocardial infarction) has certain characteristic features. The T wave is symmetrical, the apex is midway between its two limbs and peaked like an arrowhead. The right and left sides of the inverted T wave of myocardial ischemia, are mirror-images of each other (**Fig. 8.4**).

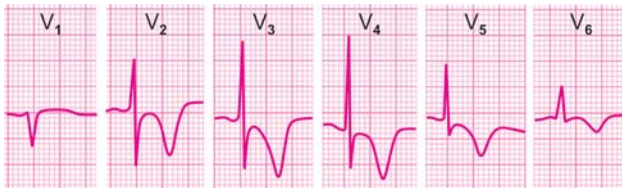


Fig. 8.4: Acute non-Q anterior wall myocardial infarction: convex S-T segment; symmetrical inverted T wave

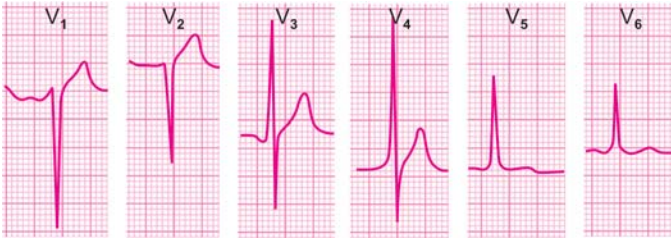

Fig. 8.5: Coronary insufficiency: T wave in V_1 taller than in V_6

A subtle evidence of myocardial ischemia is that the T wave amplitude in lead L_I is less than in L_{III} and that in lead V_6 is less than in V_1 (**Fig. 8.5**).

Conditions associated with abnormal QRS morphology may also cause T wave inversion in the leads where the QRS complexes are upright. Three classical examples are ventricular hypertrophy, bundle branch block and WPW syndrome.

The T wave inversion in these conditions is secondary to abnormal ventricular depolarization or intraventricular conduction and is called secondary T wave inversion.

The characteristic feature of secondary T wave inversion is that it is asymmetrical, with the distal limb steeper than the proximal limb and the apex is blunt (**Fig. 8.6**).

In left ventricular hypertrophy, the inverted T wave has a long and gradual downslope with a rapid return to the baseline, thus making it asymmetrical.

T wave inversion secondary to ventricular hypertrophy occurs in leads showing tall R waves. This along with S-T segment depression constitutes the pattern of systolic overload or ventricular strain (**Fig. 8.7A**).

Mega-sized 'giant' inverted T waves are observed in hypertrophic cardiomyopathy where the hypertrophy is confined to the left ventricle apex. Similar deep inverted T waves are also seen after intracranial hemorrhage (**Fig. 8.7B**).

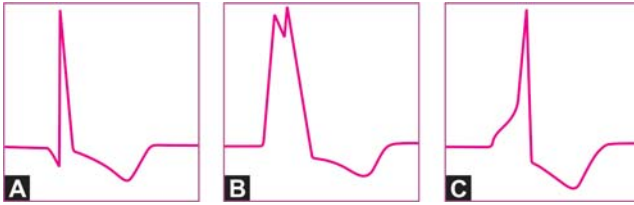


Fig. 8.6: Causes of secondary T wave inversion:
A. Ventricular hypertrophy
B. Bundle branch block
C. WPW syndrome

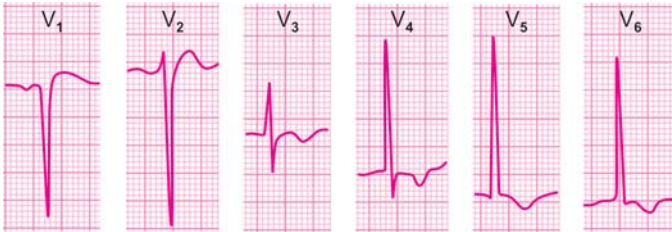


Fig. 8.7A: Left ventricular hypertrophy with strain:
Depressed S-T segment; inverted T waves

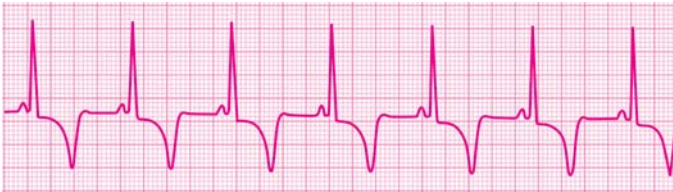

Fig. 8.7B: Hypertrophic apical cardiomyopathy:
Giant inverted T waves

In bundle branch block, the T wave is generally opposite to the direction of the QRS deflection and constitutes secondary T wave inversion. If the T wave is upright in leads showing a positive QRS deflection, associated myocardial ischemia should be considered.

In WPW syndrome, the T wave is inverted in leads showing a wide and upright deflection. It reflects abnormal repolarization secondary to pre-excitation of the ventricle.

T wave inversion in nearly all ECG leads is generally due to non-specific causes, a metabolic abnormality or a diffuse process affecting the myocardium or pericardium. Regional inversion of the T wave in specific leads can be caused by specific etiological factors such as:

- ❖ *In Leads L_I , aVL , V_5 , V_6*
 - Lateral wall ischemia/infarction
 - Left ventricular hypertrophy
 - Left bundle branch block
 - Digitalis effect or toxicity
- ❖ *In Leads V_1 , V_2 , V_3*
 - Anteroseptal ischemia/infarction
 - Right ventricular hypertrophy
 - Right bundle branch block
 - WPW syndrome, Type A
 - Persistent juvenile pattern
 - Acute pulmonary embolism
 - Arrhythmogenic RV dysplasia
- ❖ *In Leads L_{II} , L_{III} , aVF*
 - Inferior wall ischemia/infarction
 - Mitral valve prolapse syndrome.

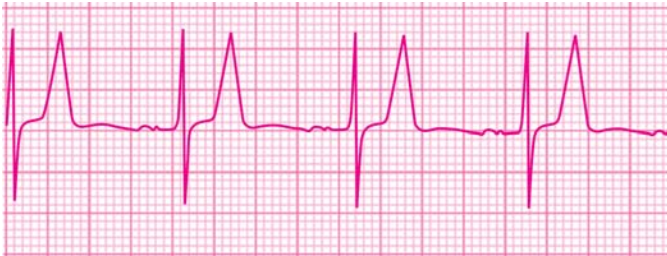

Fig. 8.8A: Effect of hyperkalemia on the T wave

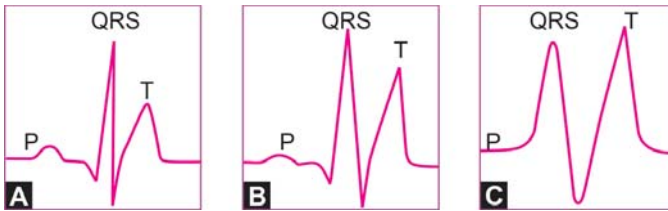


Fig. 8.8B: Effects of progressively increasing hyperkalemia

TALL T WAVE

The T wave exceeding a voltage of 5 mm in the standard leads and 10 mm in precordial leads is considered tall.

The causes of tall T waves are:

- ❖ Hyperkalemia (**Fig. 8.8**)
- ❖ Myocardial ischemia/injury
 - Hyperacute infarction
 - Prinzmetal's angina.

A high serum potassium value is classically associated with tall T waves. The T wave of hyperkalemia is very tall, peaked, symmetrical and has a narrow base, the so called 'tented' T wave (**Fig. 8.8A**).

Other ECG features of hyperkalemia (**Fig. 8.8B**) depend upon serum potassium values and can be categorized as:

- A. Serum $K^+ > 6.8$ mEq/L
 - Tall tented T waves
 - Short Q-T interval
- B. Serum $K^+ > 8.4$ mEq/L
 - Low/absent P waves
- C. Serum $K > 9.1$ mEq/L
 - Wide, bizarre QRS
 - A-V block and arrhythmias

The common causes of hyperkalemia include renal failure, adrenal insufficiency, metabolic acidosis and excessive potassium intake. The clinical importance of hyperkalemia lies in the fact that it can cause life-threatening arrhythmias.

Since hyperkalemia severe enough to cause gross ECG changes is most often due to renal failure, the clinical picture is usually that of uremia with hypertension, fluid overload, anemia and low urinary output.

Treatment of hyperkalemia includes elimination of dietary potassium, infusion of glucose with insulin, bicarbonate administration to combat acidosis, cation-exchange resins to bind potassium and hemodialysis in extreme situations.

In the hyperacute phase of myocardial infarction, there is S-T segment elevation (convex upwards) along with tall T waves, the proximal limb of the T wave blending with the elevated S-T segment (**Fig. 8.9**).

This phase is followed by serial evolution of ECG changes with appearance of Q waves, settling down of the S-T segment and inversion of the T waves. Because of myocardial necrosis secondary to coronary occlusion, the serum levels of cardiac enzymes (CPK, SGOT) are raised.

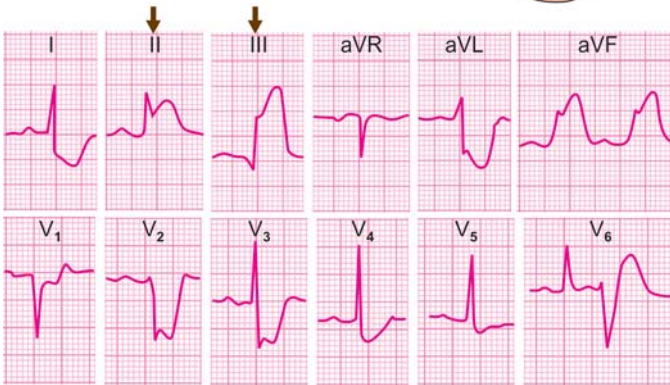
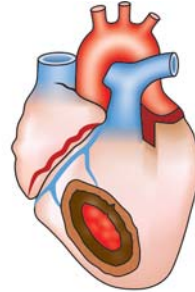


Fig. 8.9: Acute inferior myocardial infarction, hyperacute phase: S-T elevation in II, III, aVF; reciprocal depression in I, aVL

In a variety of angina called variant angina or Prinzmetal's angina, the basis of myocardial ischemia is not coronary thrombosis but coronary spasm. In such an ischemic episode of vasospastic angina, the ECG changes are similar to those of hyperacute phase of infarction with S-T segment elevation and tall T waves (**Fig. 8.9**).

The difference is that the ECG changes do not evolve serially but settle down rapidly. Q waves never appear and serum levels of cardiac enzymes are not raised as there is no myocardial necrosis.

Table 8.1: Relationship between location of ECG changes and coronary artery spasm

<i>Coronary artery showing spasm of</i>	<i>Location of ECG changes</i>
Left anterior descending artery	V ₁ V ₂ V ₃ V ₄
Left circumflex artery	L _I aVLV ₅ V ₆
Right coronary artery	L _{II} L _{III} aVF

Since the basis of Prinzmetal's angina is vasospasm, the coronary artery undergoing spasm can be predicted from the leads showing ECG changes, as depicted in **Table 8.1**.

The T wave may become excessively tall in the presence of coronary insufficiency. This T wave differs from the tall T wave of hyperkalemia by the fact that it is broad based and the Q-T interval is prolonged. On the other hand in hyperkalemia, the T wave is narrow based or "tented" and the Q-T interval is shortened.

9

Abnormalities of the U Wave

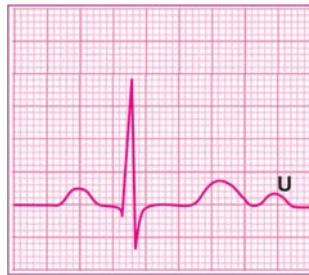NORMAL U WAVE

The U wave is produced by slow and late repolarization of the intraventricular Purkinje system and follows the T wave which represents repolarization of the main ventricular mass.

The normal U wave fulfills the following criteria:

- ❖ It is an upright deflection
- ❖ It is much smaller than the T wave.

It is often difficult to notice the U wave but when seen, it is best appreciated in the precordial leads V_2 to V_4 . The U wave is easily visible when the Q-T interval is short, being clearly separated from the T wave it follows. It is also easily visible when the heart rate is slow, being clearly separated from the P wave that follows it.



PROMINENT U WAVE

A U wave that is exaggerated and approximates the size of the T wave is considered to be a prominent U wave (**Fig. 9.1**). The causes of prominent U waves are:

- ❖ Hypokalemia and hypercalcemia
- ❖ Cardiovascular drugs, e.g. digitalis

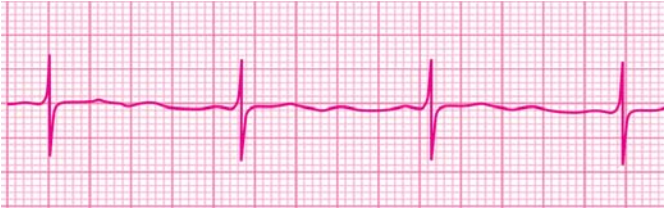


Fig. 9.1: Prominent U wave due to hypokalemia

- ❖ Psychotropic drugs, e.g. tricyclic antidepressants
- ❖ Congenital long Q-T syndrome
- ❖ Early repolarization variant.

In hypokalemia, a prominent U wave that follows a low T wave produces a 'camel-hump' effect. Alternatively, a flat T wave followed by a prominent U wave may falsely suggest prolongation of the Q-T interval while actually it is the Q-U interval that is being measured.

Certain cardiovascular therapeutic agents and psychotropic drugs can cause prominence of the U waves. Knowledge of this fact can avoid the over diagnosis of hypokalemia and Q-T interval prolongation.

INVERTED U WAVE

A U wave that is reversed in polarity is called an inverted U wave (**Fig. 9.2**). The causes of inverted U wave are:

- ❖ Ischemic heart disease
- ❖ Left ventricular diastolic overload.

Inversion of U waves can be taken as a sign of myocardial ischemia or ventricular strain. When inversion is due to myocardial ischemia, this is usually associated with changes in the S-T segment and T wave. Occasionally, U wave inversion may occur alone in the absence of ST-T changes.

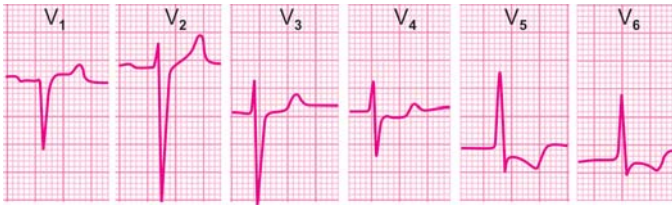


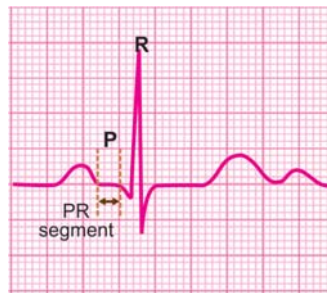
Fig. 9.2: Inverted U wave due to myocardial ischemia

Left ventricular overload may be systolic or diastolic. Inversion of the U wave occurs in diastolic (volume) overload. This is associated with tall QRS complexes in left ventricular leads V₅, V₆, L₁ and aVL. The strain pattern of S-T segment depression and T wave inversion is only observed in systolic (pressure) overload.

10

Abnormalities of P-R Segment

All ECG deflections occur above or below a reference baseline known as the isoelectric line. The main segment of the isoelectric line intervenes between the T (or U) wave of one cardiac cycle and the P wave of the next cycle.



The portion of the isoelectric line between the termination of the P wave and the onset of the QRS complex is called the P-R segment. It denotes the conduction delay in the atrioventricular node. Normally, the P-R segment is at the same level as the main segment of the isoelectric line.

Potential abnormality of the P-R segment is depression of the P-R segment in relation to the baseline. Abnormalities of the length of the P-R segment reflect variations in the duration of the P-R interval.

P-R SEGMENT DEPRESSION

The P wave is produced by atrial depolarization. The Ta wave is produced by atrial repolarization. Normally, the Ta wave is not seen as it coincides with and lies buried in the much larger QRS complex. Prominence of the Ta wave produces depression of the P-R segment (**Fig. 10.1**).

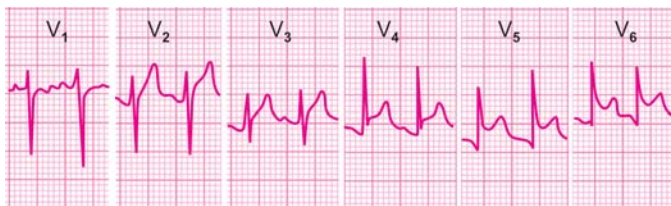


Fig. 10.1: Depressed P-R segment due to acute pericarditis

The causes of P-R segment depression are:

- ❖ *Secondary Causes*
 - Sinus tachycardia
 - Atrial enlargement
- ❖ *Primary Causes*
 - Acute pericarditis
 - Atrial infarction
 - Chest wall trauma.

P-R segment depression secondary to marked sinus tachycardia has no separate clinical relevance. A depressed P-R segment alone has low sensitivity as a diagnostic criteria for atrial enlargement.

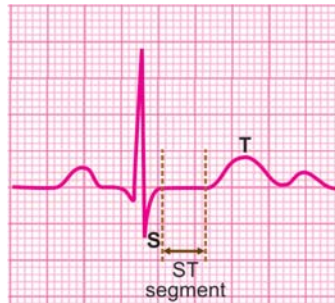
Acute pericarditis is a frequent cause of P-R segment depression and in fact, a diagnostic feature of this condition. In myocardial infarction, the P-R segment is depressed only if atrial infarction occurs. This fact is used to differentiate acute pericarditis from acute myocardial infarction since both conditions present with chest pain and ECG changes.

Depression of the P-R segment may follow trauma to the chest wall, either accidental or surgical. The P-R segment depression observed after penetrating chest wounds or cardiac surgery is due to accompanying pericarditis or atrial injury.

11

Abnormalities of S-T Segment

All ECG deflections occur above or below a reference baseline known as the isoelectric line. The main segment of the isoelectric line intervenes between the T (or U) wave of one cardiac cycle and the P wave of the next cycle.



The portion of the isoelectric line between the termination

of the S wave (J point) and the onset of the T wave is called the S-T segment. It represents the slow plateau phase of ventricular repolarization. Normally, the S-T segment is at the same level as the main segment of the isoelectric line.

Potential abnormalities of the S-T segment are depression or elevation of the S-T segment in relation to the baseline. Abnormalities of the length of the S-T segment reflect variation in the duration of the Q-T interval.

S-T SEGMENT DEPRESSION

Depression of the S-T segment greater than 1.0 mm in relation to the baseline constitutes significant S-T segment depression. Since depression of the S-T segment is often associated with inversion of the T wave, together they are referred to as ST-T changes.

The causes of S-T segment depression are:

NON-SPECIFIC CAUSES

- ❖ *Physiological states*
 - Anxiety
 - Tachycardia
 - Hyperventilation
- ❖ *Extra-cardiac disorders*
 - Systemic, e.g. hemorrhage, shock
 - Cranial, e.g. cerebrovascular accident
 - Abdominal, e.g. pancreatitis, cholecystitis
 - Respiratory, e.g. pulmonary embolism.

SPECIFIC CAUSES

- ❖ *Primary abnormality*
 - Pharmacological, e.g. digitalis, quinidine
 - Metabolic, e.g. hypokalemia, hypothermia
 - Myocardial, e.g. cardiomyopathy, myocarditis
 - Ischemic, e.g. coronary insufficiency, infarction
- ❖ *Secondary abnormality*
 - Ventricular hypertrophy
 - Bundle branch block
 - WPW syndrome.

S-T segment depression lacks specificity as a diagnostic indicator. Since depression of the S-T segment can be caused by certain physiological states and non-cardiac diseases, it only highlights the importance of viewing any ECG finding in the light of clinical data.

One should be careful before diagnosing myocardial ischemia only by ECG criteria. S-T segment depression should be interpreted with caution in upper abdominal and respiratory

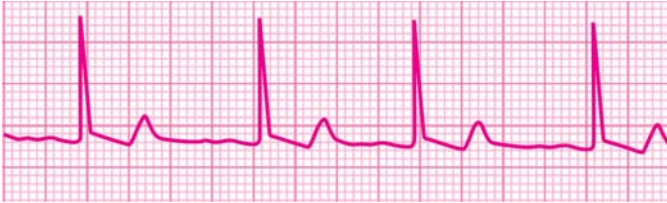

Fig. 11.1: Effect of digitalis on the S-T segment

diseases where the clinical picture may be confused with that of heart disease.

Digitalis administration produces various ECG abnormalities of which S-T segment depression is an important manifestation. The depressed S-T segment either assumes a shape that is a mirror-image of the correction mark sign (\checkmark) (**Fig. 11.1**).

When these changes are confined to leads V_5 , V_6 , they indicate digitalis administration. Changes occurring in most leads are suggestive of digitalis intoxication.

Hypokalemia causes S-T segment depression (**Fig. 11.2**) but the more prominent abnormalities are:

- ❖ Low or flat T waves
- ❖ Prominent U waves
- ❖ Prolonged P-R interval
- ❖ Prolonged Q-U interval

Primary diseases of the myocardium such as cardiomyopathy and acute myocarditis produce S-T segment depression and T wave inversion. These changes are often associated with wide QRS complexes due to intraventricular conduction defect.

Clinically speaking, coronary artery disease is the most important cause of S-T segment depression. In myocardial ischemia, the degree of S-T segment depression (greater than 1 mm) generally correlates with severity of coronary insufficiency (**Fig. 11.3**).

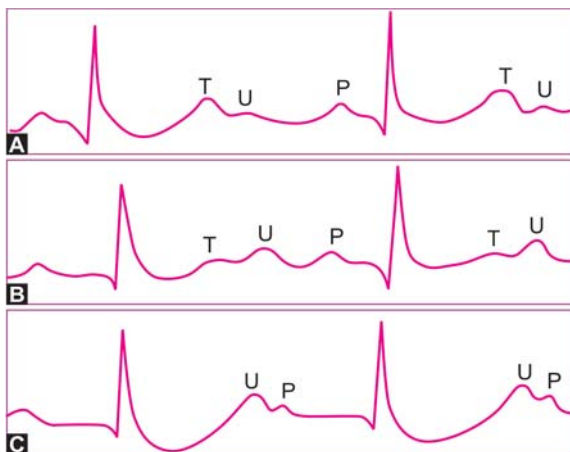


Fig. 11.2: Effects of progressively increasing hypokalemia

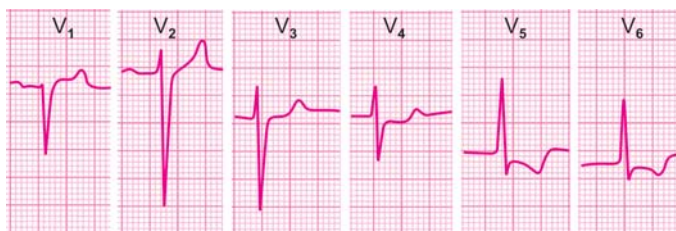

Fig. 11.3: Lateral wall ischemia changes after angina pectoris: Depression of S-T segment; inversion of T wave

Besides being depressed, the morphology of the S-T segment associated with increasing severity of myocardial ischemia, can be classified as given in **Figure 11.4**.

In acute coronary insufficiency, the S-T segment acquires a coved or convex appearance. This change may be observed in several leads in contrast to localized changes seen in regional

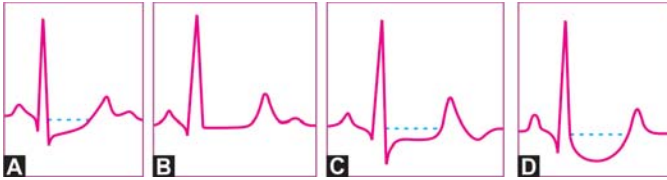


Fig. 11.4: Types of ST segment depression with increasing severity of myocardial ischemia:

- A. Only J point depression (upsloping S-T segment)
- B. Horizontality of S-T segment (sharp ST-T junction)
- C. Plane S-T depression (horizontal S-T depression)
- D. Sagging depression (hammock-like S-T segment)

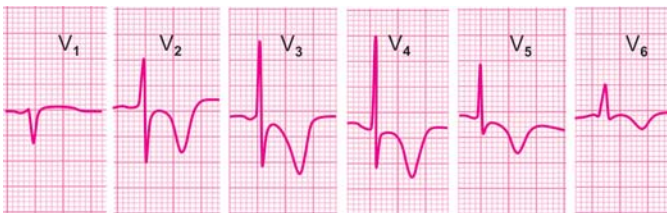


Fig. 11.5: Acute non-Q anterior wall myocardial infarction:
Convex S-T segment; inverted T wave

myocardial ischemia. Acute non-Q myocardial infarction may also produce an identical picture (**Fig. 11.5**) but with the following differences:

- ❖ There is history of prolonged chest pain.
- ❖ Cardiac enzymes (e.g. CPK) are raised.
- ❖ ST-T changes persist in serial ECGs.

In acute Q-wave myocardial infarction, the ECG leads oriented towards the infarct show S-T segment elevation while the leads oriented towards the uninjured surface of the heart may reveal S-T segment depression. Such depression of the S-T segment is termed as reciprocal depression.

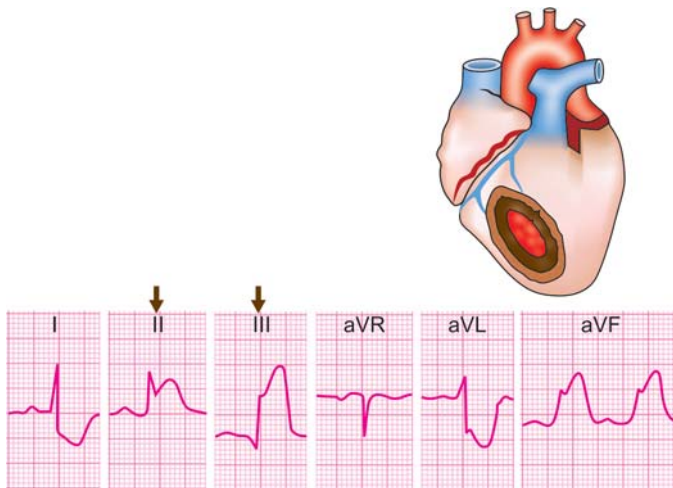


Fig. 11.6: Acute inferior myocardial infarction, hyperacute phase: S-T elevation in II, III, aVF; reciprocal depression in I, aVL

For instance, inferior wall myocardial infarction leads to S-T segment elevation in leads L_{II} , L_{III} and aVF, while leads L_I and aVL show S-T segment depression (**Fig. 11.6**).

Depression of the S-T segment constitutes the most useful criterion for the positivity of the exercise ECG test (stress test) using a treadmill or bicycle ergometer. The degree of positivity of the stress test (mild, moderate or severe) can be gauged from these parameters of S-T segment depression:

❖ *Degree of S-T Depression*

Greater the magnitude of S-T depression, higher is the grade of positivity of the stress test. A depression of 3 mm or more indicates severe coronary artery disease.

❖ *Nature of S-T Depression*

The types of S-T depression with increasing diagnostic significance are:

- Rapid upstroke of S-T segment

- Slow upstroke of S-T segment
- Horizontal ST segment depression
- Downslope ST segment depression.

❖ *Timing of S-T Depression*

Earlier the appearance of S-T depression in the exercise period, greater is the grade of positivity of the stress test. Depression that appears in the first stage of exercise indicates greater positivity than that which appears in the third stage.

❖ *Duration of S-T Depression*

Greater the total duration of S-T depression (exercise plus recovery period), more is the grade of positivity of the stress test. Depression that persists for upto 8 minutes of the recovery period indicates severe coronary disease.

Conditions associated with abnormal QRS morphology may also cause S-T segment depression in the leads where the QRS complex is upright. Three classical examples are ventricular hypertrophy, bundle branch block and WPW syndrome. The S-T segment depression in these conditions is secondary to an abnormality of ventricular depolarization or intraventricular conduction and is called secondary S-T segment depression.

Secondary S-T segment depression can be differentiated from primary depression of myocardial ischemia by the shape of the T wave. The T wave of ischemia is symmetrical and peaked while that of secondary S-T depression is asymmetrical and blunt (**Fig. 11.7**).

S-T SEGMENT ELEVATION

Elevation of the S-T segment exceeding 1 mm in relation to the baseline constitutes significant S-T segment elevation. The causes of S-T segment elevation are:

- ❖ Coronary artery disease
 - Myocardial infarction

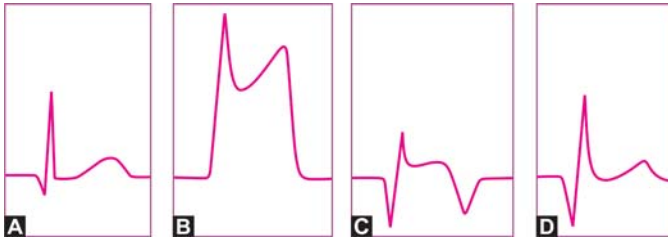


Fig. 11.8: Phases of acute myocardial infarction:
 A. Normal QRS-T
 B. Hyperacute phase
 C. Fully evolved phase
 D. Stabilized phase

The leads which show S-T segment elevation in myocardial infarction depend upon the location of the infarct and can be expressed as given in **Table 11.1**.

Besides S-T segment elevation, other electrocardiographic features of myocardial infarction are:

- ❖ Symmetrical T wave inversion
- ❖ Appearance of Q wave

Table 11.1: Location of infarction determined from ECG leads

<i>S-T elevation in</i>	<i>Location of infarction</i>
V ₁ to V ₄	Anteroseptal
V ₁ , V ₂	Septal
V ₃ , V ₄	Anterior
I _r , aVL	High lateral
V ₅ -V ₆ I _r aVL	Lateral
V ₃ -V ₆ I _r aVL	Anterolateral
V ₁ -V ₆ I _r aVL	Extensive anterior
I _{II} I _{III} avF	Inferior
V ₃ R V ₄ R	Right ventricular

114 ECG Made Easy

- ❖ Loss of R wave height
- ❖ Regional location of changes
- ❖ Reciprocal S-T depression in other leads
- ❖ Arrhythmias and conduction defects
- ❖ Serial evolution of ECG changes.

The ECG findings of a myocardial infarct depend upon several factors such as:

- ❖ Age of the infarct; hyperacute or recent damage
- ❖ Type of the infarct; transmural or subendocardial
- ❖ Site of the infarct; anterior wall or inferior wall
- ❖ Underlying abnormality; LBBB, LVH or WPW.

Reasons for disparity between ECG changes and clinical findings include:

- ❖ Left circumflex disease
- ❖ Attenuation phenomenon
- ❖ Hibernating myocardium
- ❖ Mechanical complication.

In Prinzmetal's angina, the ECG changes are very similar to those of the hyperacute phase of myocardial infarction with the following differences:

- ❖ ECG changes resolve rapidly and do not evolve serially
- ❖ Serum levels of cardiac enzymes (e.g. CPK) are normal.

The basis of Prinzmetal's angina is coronary spasm and not coronary thrombosis as in the case of myocardial infarction. Coronary spasm may be provoked by injection of intracoronary ergonovine. The coronary artery undergoing spasm can be predicted from the leads showing S-T elevation as shown in **Table 11.2**.

Besides acute myocardial infarction, another frequent cause of S-T segment elevation is acute pericarditis. Since both these

Table 11.2: Relationship between location of S-T elevation and coronary artery spasm

<i>S-T elevation in</i>	<i>Coronary artery spasm of</i>
V ₁ V ₂ V ₃ V ₄	Left anterior descending artery
V ₅ V ₆ L ₁ avL	Left circumflex artery
L _{II} L _{III} avF	Right coronary artery

conditions are associated with chest pain, given the more serious nature of myocardial infarction, it is extremely important to differentiate them.

Electrocardiographic features of acute pericarditis (**Fig.11.9**), as different from those of acute myocardial infarction are:

- ❖ S-T segment elevation is flat or concave upwards
- ❖ S-T elevation is observed in nearly all leads
- ❖ T wave is upright and elevated off the baseline
- ❖ Q wave does not appear at any stage
- ❖ R wave height is maintained
- ❖ P-R segment is depressed
- ❖ There is no reciprocal S-T segment depression
- ❖ Sinus tachycardia is almost invariably present
- ❖ Arrhythmias and conduction defects are unusual
- ❖ ECG changes do not evolve but resolve rapidly.

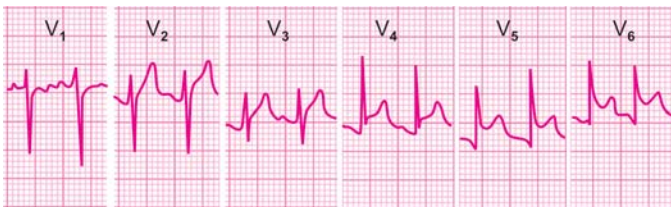


Fig. 11.9: Acute pericarditis: Saddle-shaped S-T segment elevation

116 ECG Made Easy

During the resolving phase of acute myocardial infarction, occasionally, there may be re-elevation of the S-T segment for which three explanations may be offered.

- ❖ Firstly, it may be due to reinfarction with re-elevation of cardiac enzymes requiring intensive treatment.
- ❖ Secondly, it may represent coronary vasospasm, the significance of which is similar to that of Prinzmetal's angina.
- ❖ Finally, S-T segment re-elevation may be due to the post-infarction syndrome or Dressler syndrome.

The specific features of Dressler syndrome are:

- ❖ Elevation of S-T segment without reciprocal depression
- ❖ Precordial pain increasing on inspiration
- ❖ Fever and tachycardia are often present
- ❖ Raised ESR but normal cardiac enzymes
- ❖ Appearance of pleuro-pericardial rub
- ❖ Responsiveness to steroid therapy.

A picture similar to that in Dressler's syndrome may be observed in the post-cardiotomy syndrome that follows cardiac surgery, chest wall trauma or pacemaker implant.

Any survivor of myocardial infarction in whom the typical pattern of the evolved phase of infarction persists for three months or longer after acute attack, should be suspected to have developed a ventricular aneurysm.

However, this ECG sign has a low sensitivity for the diagnosis of an aneurysm. The presence of a ventricular aneurysm has to be confirmed by echocardiography.

There exists a benign but often alarming electrocardiographic entity that presents with concave upward S-T segment elevation and an entirely normal clinical profile. It is known as the "early repolarization" syndrome. Since it is observed in young healthy individuals, this entity is also known as the "athletic heart".

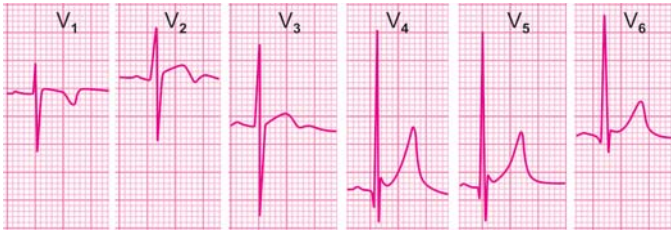


Fig. 11.10: ECG features of early repolarization syndrome:

- a. tall R waves in leads V_4 to V_6
- b. deep and narrow initial q waves
- c. concave-upward ST segment elevation
- d. initial slur on ST segment; the J wave
- e. tall and upright symmetrical T waves
- f. prominent mid-precordial U waves

It represents early repolarization of a portion of the myocardium, before the entire myocardium has been depolarized.

There is an early uptake of the S-T segment before the descending limb of the R wave has reached the baseline. This causes an initial slur on the S-T segment known as the J wave. The J wave or Osborne wave is also observed in hypothermia.

The T waves are tall and upright in the lateral leads and the U waves are prominent in the mid-precordial leads (**Fig. 11.10**).

Other ECG features of the athletic heart are:

- ❖ Sinus bradycardia with sinus arrhythmia
- ❖ Voltage criteria of left ventricular hypertrophy
- ❖ Persistent juvenile pattern (T wave inversion V_1 to V_3).

The clinical features of early repolarization syndrome are:

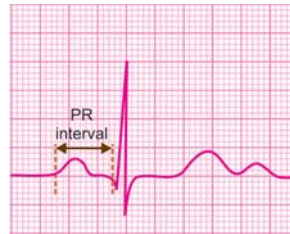
- ❖ Subject is a young black male
- ❖ He is healthy and of athletic built
- ❖ He is active and free from symptoms
- ❖ The clinical evaluation is entirely normal
- ❖ ST segment returns to baseline after exercise.

12

Abnormalities of P-R Interval

NORMAL P-R INTERVAL

The P-R interval is measured on the horizontal axis from the onset of the P wave to the beginning of the QRS complex, irrespective of whether it begins with a Q wave or R wave. The width of the P wave is included in the length of P-R interval.



Since the P wave represents atrial depolarization and the QRS complex represents ventricular depolarization, the P-R interval is a measure of the atrioventricular (AV) conduction time. The AV conduction time includes the time taken for atrial depolarization, the conduction delay in the A-V node and the time taken for an impulse to traverse the intraventricular conduction system before ventricular depolarization begins.

Since the conduction delay in the A-V node is the major fraction of the P-R interval, the length of P-R interval is a measure of the duration of A-V nodal delay.

The normal P-R interval in adults ranges from 0.12 to 0.20 sec depending upon the heart rate. It is longer at slow heart rates and shorter at fast heart rates. The P-R interval is slightly shorter in children, the upper limit being 0.18 sec. It is slightly longer in the elderly, the upper limit being 0.22 sec.

Potential abnormalities of the P-R interval are:

- ❖ Prolonged P-R interval
- ❖ Shortened P-R interval
- ❖ Variable P-R interval.

PROLONGED P-R INTERVAL

A P-R interval that exceeds 0.20 sec in adults and 0.18 sec in children is taken as prolonged. Since the P-R interval reflects atrioventricular conduction time, a prolonged P-R interval indicates increased A-V nodal conduction delay or first degree atrioventricular (AV) block (**Fig. 12.1**).

The causes of prolonged P-R interval are:

- ❖ Vagal dominance in athletes
- ❖ Acute rheumatic fever or diphtheria
- ❖ Coronary artery disease with fascicular block
- ❖ Drugs acting on the A-V node, e.g. digitalis, beta-blockers, calcium-channel blockers.

P-R interval prolongation is normally observed in vagotonic individuals such as athletes. It is also a normal effect of vagal stimulation, e.g. carotid sinus massage and sympathetic blockade, e.g. beta-blocker administration

A prolonged P-R interval is one of the diagnostic criteria of acute rheumatic fever and indicates carditis. Similarly, a prolonged P-R interval in diphtheria indicates myocarditis.

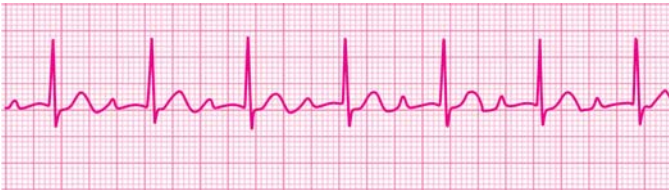

Fig. 12.1: Prolonged P-R interval: First-degree A-V block

120 ECG Made Easy

P-R interval prolongation is usual with cardiovascular drugs that act on the A-V node and delay A-V conduction. Examples are digitalis, verapamil, diltiazem, propranolol and metoprolol.

Prolongation of the P-R interval in the presence of bundle branch block indicates that atrioventricular conduction down the unblocked bundle branch is also delayed. Since such patients are likely to develop complete A-V block, they may require prophylactic cardiac pacing.

SHORTENED P-R INTERVAL

A P-R interval that is less than 0.12 sec is considered short. Since P-R interval reflects atrioventricular conduction time, a short P-R interval indicates decreased A-V nodal delay.

The causes of shortened P-R interval are:

- ❖ A-V nodal or junctional rhythm
- ❖ WPW syndrome with pre-excitation
- ❖ Drugs that hasten A-V conduction.

If a cardiac rhythm originates from the A-V nodal area (junctional rhythm), the ventricles are activated in the normal sequence but the atria are activated retrogradely, that is, from below upwards. Since the atria are activated nearly simultaneously with the ventricles, the P waves just precede, just follow or are merged in the QRS complexes. When the P waves just precede the QRS complexes, they are associated with a short P-R interval (**Fig. 12.2**).

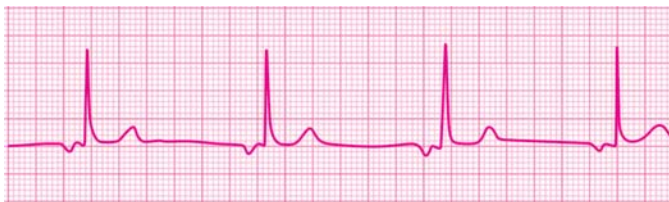

Fig. 12.2: Shortened P-R interval: Junctional rhythm

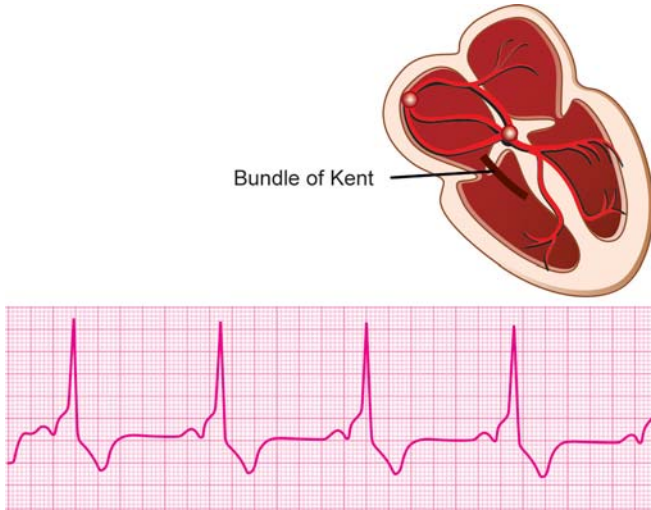


Fig. 12.3: Short P-R interval: WPW syndrome

A junctional rhythm at its inherent discharge rate of 40-60 beats per minute constitutes a junctional escape rhythm while a junctional rhythm at an enhanced rate of 60-100 beats per minute constitutes a junctional tachycardia.

The Wolff-Parkinson-White (WPW) syndrome is an entity in which an accessory pathway or by-pass tract called the bundle of Kent directly connects the atrial to the ventricular myocardium without passing through the A-V node. Fast conduction of impulses down this tract results in premature ventricular activation called pre-excitation, since the A-V node is by-passed. This results in a short P-R interval (**Fig. 12.3**).

The QRS complex is wide because it is a fusion beat which is the blend of ventricular pre-excitation (by bundle of Kent) and normal ventricular activation (by bundle of His). Pre-excitation causes a slur on the ascending limb or R wave known as the delta wave. S-T segment depression and T wave inversion are secondary ST-T changes.

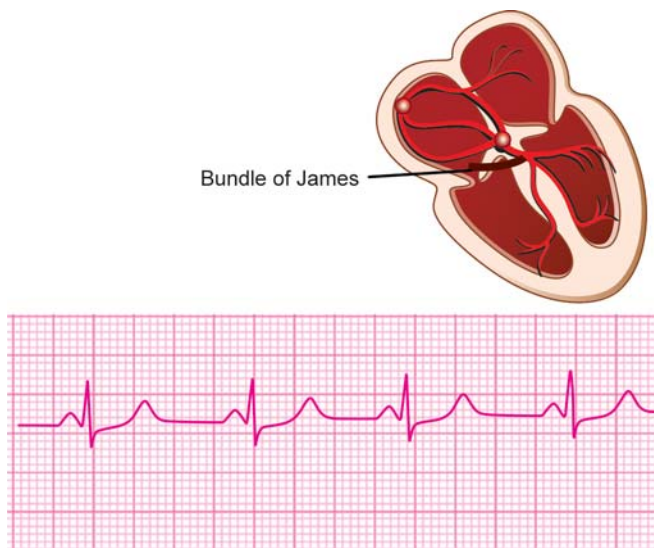


Fig. 12.4: Short P-R interval: LGL syndrome

In the Lown-Ganong-Levine (LGL) syndrome, an accessory atriofascicular tract (James bypass) directly connects the atria to the bundle of His. This causes pre-excitation of the ventricles and a short P-R interval without A-V nodal delay. The QRS complex is narrow because the ventricles are activated as usual by the bundle of His (**Fig. 12.4**).

The P-R interval is prolonged in vagotonic individuals and with vagal stimulation. Conversely, the P-R interval is shortened with vagolytic drugs, e.g. atropine and other drugs that have anticholinergic effects.

VARIABLE P-R INTERVAL

During any rhythm, a changing P-R interval on a beat-to-beat basis is designated as variable P-R interval. Normally, atrial

activation (P wave) is followed by ventricular activation (QRS complex) with an identical intervening P-R interval in all beats, thus establishing fixed relationship between them.

If atrial and ventricular activation occur independent of each other and not sequentially, or if the extent of A-V nodal conduction delay varies from beat-to-beat, the P-R interval is variable.

The causes of variable P-R interval are:

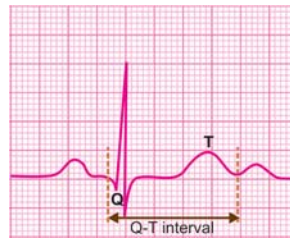
- ❖ Type I, second-degree A-V block
- ❖ Junctional pacemaker rhythm
- ❖ Complete, third-degree A-V block
- ❖ Wandering pacemaker rhythm
- ❖ Multifocal atrial tachycardia.

13

Abnormalities of Q-T Interval

NORMAL Q-T INTERVAL

The Q-T interval is measured on the horizontal axis from the onset of the Q wave to the termination of the T wave (not the U wave). The duration of the QRS complex, the length of the S-T segment and the width of the T wave are included in the measurement of the Q-T interval.



Since the QRS duration represents ventricular depolarization time and the T wave width represents ventricular repolarization time the Q-T interval is a measure of the total duration of ventricular electrical systole.

The normal Q-T interval is in the range of 0.35 to 0.43 sec or 0.39 ± 0.04 sec. The upper limit of normal Q-T interval depends upon several variables including age, gender, autonomic tone and drug therapy.

The Q-T interval tends to be shorter in young individuals (< 0.44 sec) and slightly longer in the elderly (< 0.45 sec). It is slightly shorter in males, the upper limit being 0.43 sec. The Q-T interval shortens at fast heart rates and lengthens at slow heart rates.

Therefore, for proper interpretation, the Q-T interval must be corrected for the heart rate. The corrected Q-T interval is known

as the Q-Tc interval. The Q-Tc interval is determined using the Bazett's formula:

$$Q-Tc = \frac{Q-T}{\sqrt{R-R}}$$

Q-T is the measured Q-T interval

$\sqrt{R-R}$ is square-root of R-R interval

When the R - R interval is 25 mm or 1 sec ($25 \times 0.04 \text{ sec} = 1 \text{ sec}$), the value of $\sqrt{R-R}$ is 1 and the Q-Tc is equal to the Q-T interval. This occurs at a heart rate of 60 beats/min.

As a general rule, QT interval that exceeds half of the duration of R-R interval is taken as prolonged.

Potential abnormalities of the Q-T interval are:

- ❖ Shortened Q-T interval
- ❖ Prolonged Q-T interval.

SHORTENED Q-T INTERVAL

A corrected Q-T interval (Q-Tc interval) less than 0.35 sec is considered short (**Fig. 13.1**). The causes of a shortened Q-Tc interval are:

- ❖ Hyperkalemia
- ❖ Hypercalcemia
- ❖ Digitalis effect
- ❖ Acidosis
- ❖ Hyperthermia

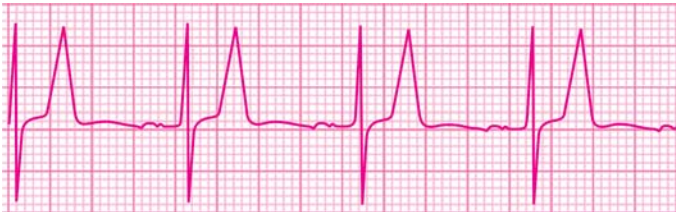

Fig. 13.1: Shortened Q-T interval due to hyperkalemia

126 ECG Made Easy

Hyperkalemia shortens the Q-T interval and is associated with tall T waves, wide QRS complexes and diminished P waves. Hypercalcemia also shortens the Q-T interval but there are no changes in the morphology of the QRS deflection or of the P and T waves.

A short Q-T interval with S-T segment depression and T wave inversion suggests digitalis effect. Anti-arrhythmic drugs also produce ST-T changes but the Q-T interval is prolonged.

PROLONGED Q-T INTERVAL

A corrected Q-T interval (Q-Tc interval) greater than 0.43 sec is considered prolonged (**Fig. 13.2**). The causes of a prolonged Q-Tc interval can be classified as:

- ❖ Congenital Q-T syndromes
 - Romano-Ward syndrome (autosomal dominant, without deafness)
 - Jerwell-Lange-Nielson syndrome (autosomal recessive, with deafness)
- ❖ Acquired Q-T syndromes
 - Electrolyte deficiency, e.g. potassium, calcium
 - Antiarrhythmic drugs, e.g. quinidine, amiodarone
 - Coronary disease, e.g. acute myocardial infarction
 - Acute myocarditis, e.g. viral myocarditis, rheumatic fever

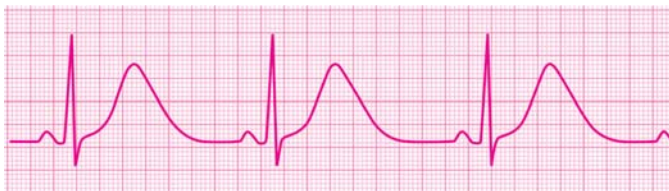

Fig. 13.2: Prolonged Q-T interval due to amiodarone

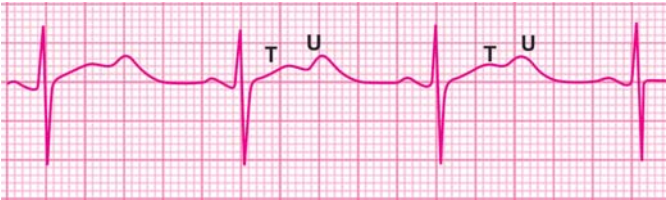


Fig. 13.3: Pseudo-prolonged Q-T interval in hypokalemia

- Intracranial event, e.g. head injury, hemorrhage
- Bradyarrhythmias, e.g. A-V block, sinus bradycardia.
- Psychotropic drugs, e.g. tricyclic antidepressants
- Miscellaneous drugs, e.g. terfenadine, cisapride.

Hypocalcemia produces true prolongation of the Q-T interval without any alteration of the S-T segment or T wave.

In hypokalemia, the T wave is flattened and the prominent U wave may be mistaken for the T wave. This may falsely suggest prolongation of the Q-T interval, whereas it is actually the Q-U interval. Hypokalemia, therefore, causes pseudo-prolongation of the Q-T interval (**Fig. 13.3**).

Antiarrhythmic drugs such as quinidine, procainamide and amiodarone can prolong the Q-T interval. They also cause widening of the QRS complex which if exceeds 25 percent of baseline, is an indication for withdrawing the culprit drug.

Since Q-T interval prolongation predisposes to arrhythmias, this is one way to explain the arrhythmia enhancing property or proarrhythmic effect of antiarrhythmic drugs.

Certain non-cardiovascular drugs such as the antihistamine terfenadine and the prokinetic cisapride prolong the Q-T interval. They do so especially in combination with ketoconazole (antifungal), erythromycin (macrolide antibiotic) or a statin (cholesterol lowering drug), which also utilize the same cytochrome enzyme CYP3A4 for hepatic metabolism. Therefore

128 ECG Made Easy

it is mandatory to measure the Q-T interval, in clinical trials undertaken for new drug development.

The clinical importance of Q-T interval prolongation lies in the fact that it predisposes to a typical type of polymorphic ventricular arrhythmia known as “Torsade de pointes” a ballet term which literally means “torsion around a point”.

This term explains the morphology of the ventricular tachycardia which consists of polymorphic QRS complexes that keep changing in amplitude and direction. The polymorphic QRS complexes give the appearance of torsion or twisting of points around the isoelectric line.

Besides Q-T prolongation and Torsade de pointes, other features of long Q-T syndrome (LQTS) are T wave alternans and notched T waves.

14

Premature Beats in Regular Rhythm

PREMATURE BEATS

Premature beats are impulses that arise due to the premature firing of an irritable automaticity focus other than the normal pacemaker, the S-A node. They are also known as premature contractions, premature complexes or simply extrasystole.

According to focus of origin, premature beats are classified as:

- ❖ Atrial premature beats
- ❖ Junctional premature beats
- ❖ Ventricular premature beats.

Atrial and junctional premature complexes are together referred to as supraventricular premature beats.

ATRIAL PREMATURE COMPLEX

An atrial premature complex (APC) (**Fig. 14.1**) is recognized by the following features:

- ❖ Premature inscription of an upright P wave, earlier than the expected sinus P wave.
- ❖ Abnormal morphology of the premature P wave due to ectopic focus of origin.
- ❖ Normal morphology of the QRS complex that follows it, since ventricular conduction is normal.
- ❖ Compensatory pause after the APC due to momentary suppression of S-A node automaticity.

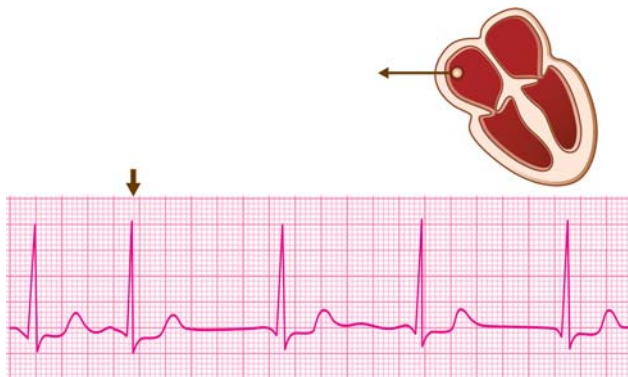


Fig. 14.1: Atrial premature beat: Ectopic P wave, narrow QRS, incomplete compensatory pause

Occasionally, two variations of APCs may be observed:

- ❖ *Blocked APC* A very premature APC may find the A-V node still refractory to ventricular conduction and may consequently get blocked. Such an APC inscribes a P wave that deforms the T wave of the preceding beat, is not followed by a QRS complex but is followed by a compensatory pause.
- ❖ *APC with aberrant ventricular conduction* Most often, the QRS complex of the APC is normal in morphology. However, if the APC finds one of the bundle branches still refractory to ventricular conduction, it inscribes a wide QRS complex or bundle branch block pattern. This is known as aberrant ventricular conduction of the APC.

APCs alternating with sinus impulses constitute a bigeminal rhythm (extrasystolic atrial bigeminy) while a series of three or more successive APCs constitute an atrial tachycardia. Frequent APCs arising from different atrial foci constitute a multifocal atrial tachycardia.

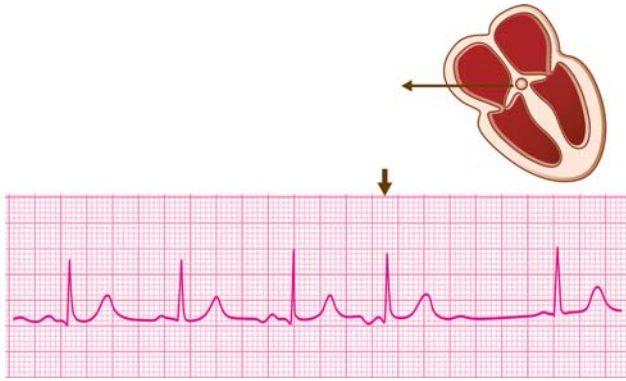


Fig. 14.2: Junctional premature beat: Inverted P wave, narrow QRS, incomplete compensatory pause

JUNCTIONAL PREMATURE COMPLEX

A junctional premature complex (JPC) (**Fig. 14.2**) is very similar to an APC but with these differences:

- ❖ The P wave of the JPC if seen, is inverted because of retrograde atrial activation.
- ❖ The P wave just precedes, just follows or is merged in the QRS complex because of near simultaneous atrial and ventricular activation.

Since, both atrial and junctional premature complexes have a somewhat similar clinical relevance and are managed in the same way, their differentiation is often futile and they are together referred to as supraventricular premature complexes.

VENTRICULAR PREMATURE COMPLEX

A ventricular premature complex (VPC) (**Fig. 14.3**) is recognized by the following features:

- ❖ Premature inscription of a QRS complex earlier than the next expected sinus beat.
- ❖ Wide and bizarre morphology of the QRS complex due to

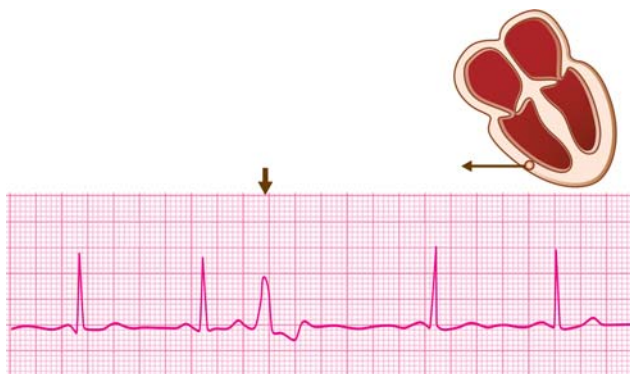


Fig. 14.3: Ventricular premature beat: Absent P wave, wide QRS, complete compensatory pause

slow activation of the ventricles.

- ❖ Bizarre QRS complex is not preceded by a P wave because of ventricular origin of the beat. A sinus P wave even if it occurs independently, is not visible as it is buried in the wide QRS complex.
- ❖ Compensatory pause after the VPC. When a VPC is inscribed, a sinus beat that was to occur around that time is missed but the next sinus beat is inscribed as usual. This is expressed as a compensatory pause after the VPC. The compensatory pause after a VPC is complete, that is, it fully compensates for the prematurity of the VPC. This is in contrast to an APC where the compensatory pause is incomplete and the next sinus beat is only somewhat delayed.

On the basis of their occurrence, VPCs can be qualified as:

- ❖ VPCs of different morphology and varying coupling interval (between VPC and preceding sinus beat) are known as multifocal VPCs (**Fig. 14.4**).

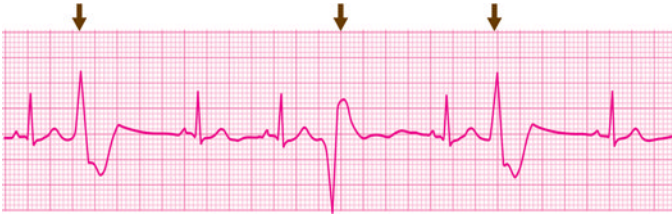


Fig. 14.4: Multifocal VPCs: Different morphology, variable coupling interval

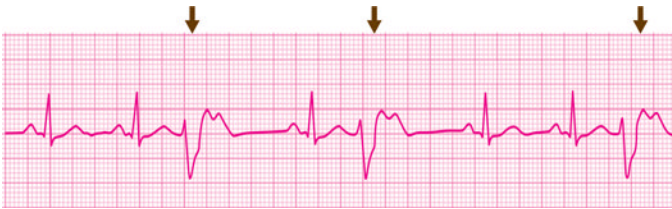


Fig. 14.5: Unifocal VPCs: Similar morphology, constant coupling interval

- ❖ VPCs of similar morphology and constant coupling interval are known as unifocal VPCs (**Fig. 14.5**).
- ❖ VPC occurring late in the diastolic period of the preceding sinus beat (long coupling interval), just about when the next sinus beat is due, is called an end-diastolic VPC.
- ❖ VPC that is so premature (very short coupling interval) that it is imposed upon the T wave of the preceding sinus impulse, exhibits the R-on-T phenomenon (**Fig. 14.6**).
- ❖ VPC during a slow rhythm, that does not allow any sinus beat to be missed and is not followed by a compensatory pause, is called an interpolated VPC (**Fig. 14.7**). It appears to be sandwiched between two sinus beats.
- ❖ VPCs alternating with sinus beats constitute a bigeminal rhythm (extrasystolic ventricular bigeminy) (**Fig. 14.8**). VPCs

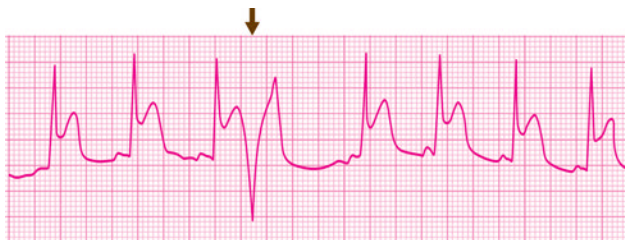


Fig. 14.6: VPC exhibiting R-on-T phenomenon:
Deformed T wave of preceding beat

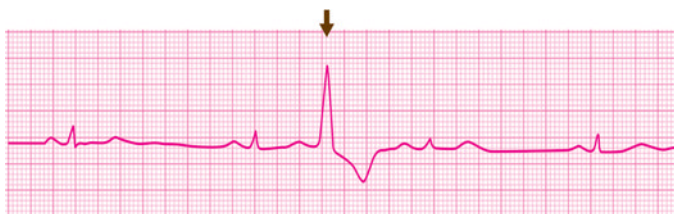

Fig. 14.7: Interpolated VPC: Ectopic beat sandwiched
between two sinus beats

after every two sinus beats represent trigeminy (**Fig. 14.9**) and after every third sinus beat constitute quadrigeminy.

- ❖ A pair of successive VPCs form a couplet (**Fig. 14.10**) and three consecutive VPCs constitute a triplet (**Fig. 14.11**).

A VPC is quite different in morphology from an APC, the former having a wide and bizarre QRS complex while the latter possessing a narrow QRS complex. Their differentiation assumes importance only if an APC conducts aberrantly to the ventricles and inscribes a wide QRS complex.

An APC with aberrant ventricular conduction can be differentiated from a true VPC by the following features:

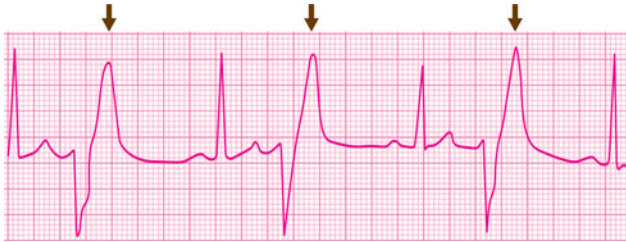


Fig. 14.8: Extrasystolic ventricular bigeminy: VPCs alternating with sinus beats

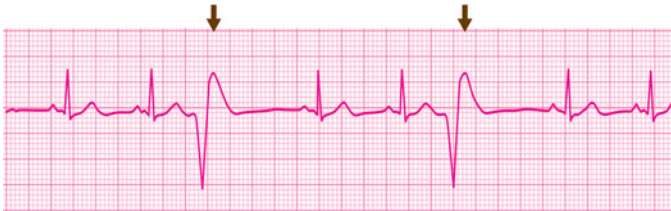

Fig. 14.9: Extra systolic ventricular trigeminy: VPC after every two sinus beats

- ❖ Preceding P wave
- ❖ Triphasic QRS contour
- ❖ Incomplete compensatory pause.

Clinical Relevance of Premature Complexes

Supraventricular Premature Complexes

Atrial premature complexes (APCs) are common even in normal persons and occur due to these causes:

- ❖ Emotional stress or physical exercise
- ❖ Smoking or high intake of tea/coffee

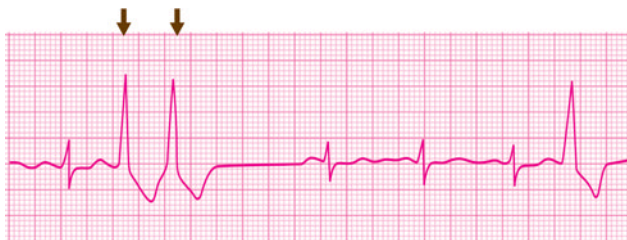

Fig. 14.10: Couplet of ventricular ectopic beats:
Two VPCs in succession

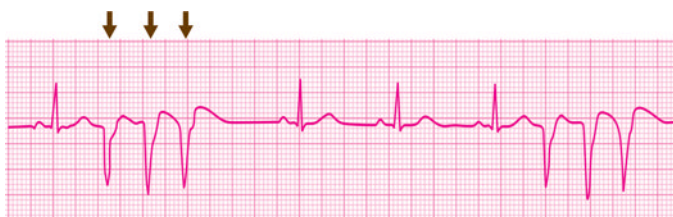

Fig. 14.11: Triplet of ventricular ectopic beats:
Three VPCs in succession

- ❖ Drugs, e.g. salbutamol, theophylline
- ❖ Metabolic causes, e.g. hypoxia, acidosis.

Junctional premature complexes (JPCs) are less common than APCs and are less likely to occur in normal persons. In other words, their presence is more indicative of heart disease.

Cardiac causes of APCs and JPCs are:

- ❖ Rheumatic carditis
- ❖ Digitalis toxicity
- ❖ Myocardial infarction
- ❖ Pericarditis
- ❖ Thyrotoxicosis
- ❖ Cardiac surgery.

Although APCs may be asymptomatic, the most common symptoms due to them are palpitations and sensation of "missed beats". JPCs cause similar symptoms but additionally produce neck-pulsation because of synchronous atrial and ventricular contraction or atrial contraction during A-V valve closure.

Treatment of supraventricular premature complexes is generally not required especially if they are asymptomatic and not associated with organic heart disease. Management is indicated if premature beats are frequent enough to produce symptoms or if they trigger tachyarrhythmias such as supraventricular tachycardia or atrial flutter.

The first step in management is avoidance of precipitating factors such as stress, vigorous exercise, smoking, beverage consumption and adrenergic drugs. Addition of a mild sedative may be useful in some patients. The next step is treatment of any underlying cardiac condition, if present. This includes withdrawal of digitalis, treatment of rheumatic fever, control of thyrotoxicosis and management of ischemia.

If premature beats are frequent, low doses of beta-blockers or diltiazem are effective in controlling the ventricular rate. Propranolol may be the drug of choice in the management of premature beats caused by anxiety, adrenergic drugs and other catecholamine excess states. Amiodarone is quite effective in suppressing the ectopic atrial focus.

Ventricular Premature Complexes

Ventricular premature complexes (VPCs) can occur even in normal individuals although they are more often due to organic heart disease.

Causes of VPCs in normal persons are:

- ❖ Emotional stress or physical exercise
- ❖ Smoking or high intake of tea/coffee
- ❖ Drugs, e.g. sympathomimetics, theophylline
- ❖ Anxiety neurosis or thyrotoxicosis.

138 ECG Made Easy

Cardiac conditions where VPCs are observed are:

❖ *Coronary Artery Disease*

- Ischemia
- Infarction
- Reperfusion

❖ *Congestive Heart Failure*

- Hypertension
- Cardiomyopathy
- Myocarditis
- Ventricular aneurysm

❖ *Mitral Valve Prolapse Syndrome*

❖ *Digitalis Treatment/Intoxication*

❖ *Cardiac Surgery or Catheterization.*

VPCs that meet the following criteria are considered to be “dangerous” or “malignant” VPCs.

- ❖ Occurring frequently (6 or more beats/min)
- ❖ In showers with runs of ventricular tachycardia
- ❖ In couplets or VPCs in bigeminal rhythm
- ❖ With short coupling interval (R-on-T phenomenon)
- ❖ More than 0.14 sec wide, bizarre or multifocal
- ❖ Associated with serious organic heart disease and left ventricular dysfunction.

Severity of ventricular ectopy can be classified on the basis of Lown's classification, as given in [Table 14.1](#).

Multifocal VPCs arise from different irritable ventricular foci, each producing a distinctive VPC, every time it fires. Since even a single irritable focus can fire a salvo of rapid discharges to cause ventricular tachycardia, presence of multifocal VPCs means that several foci are discharging and trouble is imminent.

Table 14.1: Lown's classification of ventricular ectopy

<i>Category</i>	<i>Degree of ectopy</i>
Class 0	No ectopy
Class 1	Less than 30/hour
Class 2	More than 30/hour
Class 3	Multiform VPCs
Class 4A	Couplets
Class 4B	Runs of 3 or more
Class 5	R-on-T phenomenon

The chances of developing life-threatening ventricular fibrillation are enhanced.

A VPC that occurs very prematurely (very short coupling interval) superimposes on the T wave of the preceding sinus beat and is said to exhibit the 'R-on-T' phenomenon. This represents the occurrence of ventricular stimulation during the vulnerable phase of Purkinje fiber repolarization or period of heightened excitability and is likely to precipitate ventricular fibrillation.

The 'R-on-T' phenomenon is observed in:

- ❖ VPCs after acute myocardial infarction
- ❖ VPCs with underlying Q-T interval prolongation
- ❖ Electrical cardioversion during digitalis therapy
- ❖ Very premature stimuli during artificial pacing.

VPCs may be asymptomatic or associated with palpitations and sensation of "missed beats". Awareness of VPCs is due to the post-VPC compensatory pause and increased force of contraction of the beat following the VPC.

Neck pulsations may be felt due to atrial systole occurring with a closed tricuspid valve as the atria and ventricles are activated almost synchronously by the VPC.

140 ECG Made Easy

Management of VPCs is governed by:

- ❖ Symptoms produced by premature beats
- ❖ Presence or absence of organic heart disease
- ❖ Nature and severity of ventricular ectopy.

Few isolated asymptomatic VPCs, in the absence of heart disease, are mostly left alone. If they are symptomatic, a search for etiological factors must be made and they should be corrected adequately.

Such measures include:

- ❖ Alleviating anxiety and stress
- ❖ Reduction of smoking and beverages
- ❖ Withdrawal of adrenergic drugs
- ❖ Management of digitalis intoxication
- ❖ Treatment of congestive heart failure
- ❖ Management of myocardial ischemia.

Antiarrhythmic drugs may be used in symptomatic patients with organic heart disease and significant ventricular ectopy in whom correction of precipitating factors does not suffice.

Patients with structural cardiac abnormalities such as left ventricular hypertrophy (LVH), hypertrophic obstructive cardiomyopathy (HOCM), dilated cardiomyopathy (DCMP) and arrhythmogenic right ventricular dysplasia (ARVD) would benefit more from antiarrhythmic drugs.

Beta-blockers like propranolol and metoprolol are the drugs of choice for treatment of VPCs associated with anxiety, physical exercise, mitral valve prolapse or thyrotoxicosis.

Lidocaine and amiodarone are the drugs of choice for VPCs after myocardial infarction, cardiac surgery or catheterization.

VPCs occurring within 24 hours of myocardial infarction carry a better prognosis and indicate reperfusion. VPCs that appear after 24 hours carry a worse prognosis and merit drug treatment.

When a patient of congestive heart failure on digitalis develops significant VPCs, it has to be decided on clinical grounds whether digitalis should be continued to manage the heart failure or withdrawn in view of drug intoxication.

If digitalis is to be withdrawn, the antiarrhythmic drug of choice for digitalis induced VPCs is phenytoin sodium which should be used in conjunction with standard therapy of digitalis intoxication.

Antiarrhythmic drugs may be used for control of VPCs but before initiating treatment with these drugs, the following issues need to be addressed to:

- ❖ Inappropriate drug usage, when the cause and effect relationship of VPCs to fatal ventricular arrhythmias has not been established.
- ❖ Aggravation of underlying cardiac abnormalities such as bradycardia and left ventricular dysfunction.
- ❖ Proarrhythmic effect of these drugs with increased likelihood of other tachyarrhythmias.
- ❖ Potential systemic side-effects associated with long-term antiarrhythmic therapy.

15

Pauses During Regular Rhythm

PAUSES DURING RHYTHM

A pause during normal regular sinus rhythm is a brief period of electrical inactivity on the ECG graph between successive beats, due to delay in onset of the next scheduled beat. A pause produces a larger gap between two successive beats than that seen in other parts of the rhythm.

The causes of pauses are:

- ❖ Premature beats
- ❖ Sinoatrial block
- ❖ Atrioventricular block.

PAUSE AFTER PREMATURE BEAT

A premature beat, whether supraventricular or ventricular, is followed by a pause that compensates for its prematurity. This is known as the compensatory pause.

In the case of a supraventricular premature beat, there is a momentary suppression of S-A node automaticity so that the next sinus beat is somewhat delayed. This results in an incomplete compensatory pause, that is, the interval between the beat preceding and following the premature beat, is less than twice the R-R interval between two successive sinus beats.

In the case of ventricular premature beat, one sinus beat after the premature beat fails to activate the already depolarized ventricles while the second sinus beat occurs as usual. This results in a complete compensatory pause, which fully

compensates for the prematurity of the ectopic beat. In other words, the interval between the beat preceding and that following the premature beat is exactly twice the R-R interval between two successive sinus beats.

PAUSE AFTER BLOCKED PREMATURE BEAT

A very premature atrial ectopic beat may find the A-V node refractory to ventricular conduction, having already been traversed by the preceding sinus beat. Therefore, it gets blocked in the A-V node and fails to inscribe a QRS complex. Nevertheless, the ectopic P wave of the premature beat deforms the T wave of the preceding sinus beat and is followed by a pause.

This premature ectopic P wave is the key to the differentiation of a non-conducted atrial premature beat from a pause due to sinoatrial block or atrioventricular block.

PAUSE DUE TO SINOATRIAL BLOCK

Sinoatrial (SA) block refers to an interference with the propagation of an impulse from the sinus node to the surrounding atrial myocardium, resulting in a delay or omission of an atrial response.

There are three degrees of sinoatrial block:

- ❖ **1° S-A block** First-degree S-A block cannot be diagnosed from the ECG as there are no dropped beats. Electrophysiological study reveals slow sinoatrial conduction.
- ❖ **2° S-A block** In second-degree S-A block, there is intermittent dropping of one more beats. In fact, an entire beat (P wave with QRS complex) is dropped as neither atrial nor ventricular activation occurs (**Fig. 15.1**).

If every second beat is dropped, that is, in a period of time when there should be 2 beats but there is only one beat, it is called 2:1 S-A block. If every third beat is dropped, that is, 2 beats occur in a period of time when there should be 3 beats, it is called 3:2 S-A block.

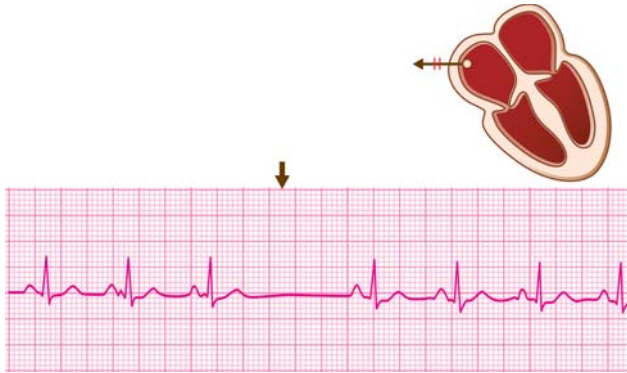


Fig. 15.1: Dropped beat due to second-degree sinoatrial block

- ❖ **3° S-A block** This is also known as complete S-A block, sinus arrest or atrial standstill (**Fig. 15.2**). In third-degree S-A block, there is a prolonged period of electrical inactivity or asystole following which either an escape rhythm from a subsidiary pacemaker takes over or prolonged asystole results in cardiac arrest.

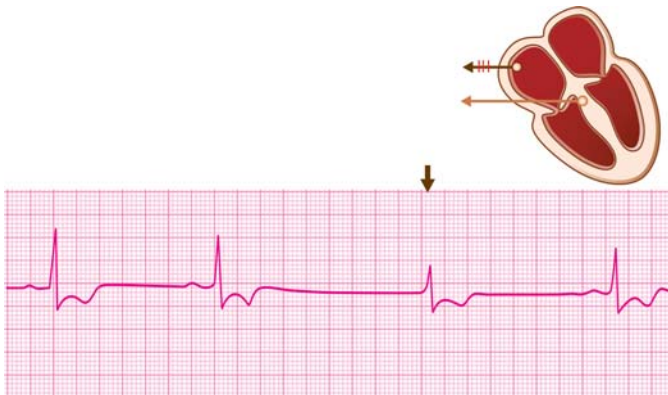

Fig. 15.2: Asystole followed by a junctional escape beat

Second-degree S-A block needs to be differentiated from two other conditions.

- ❖ A non-conducted atrial ectopic beat also results in a pause resembling S-A block. However, the non-conducted ectopic beat inscribes a premature ectopic P wave that superimposes on the T wave of the preceding sinus beat.
- ❖ A second-degree atrioventricular block (A-V block) also results in missing of a beat but in that case, the P wave is inscribed normally and only the QRS complex is missing.

PAUSE DUE TO ATRIOVENTRICULAR BLOCK

Atrioventricular (A-V) block refers to an interference with the propagation of an impulse from the atria to the ventricles, resulting in a delay or omission, of a ventricular response.

There are three degrees of atrioventricular block:

- ❖ **1° A-V block** In first-degree A-V block, there is only a delay in atrioventricular conduction of all beats. This is reflected in a prolonged P-R interval in all beats, without any dropped beats (**Fig. 15.3**).

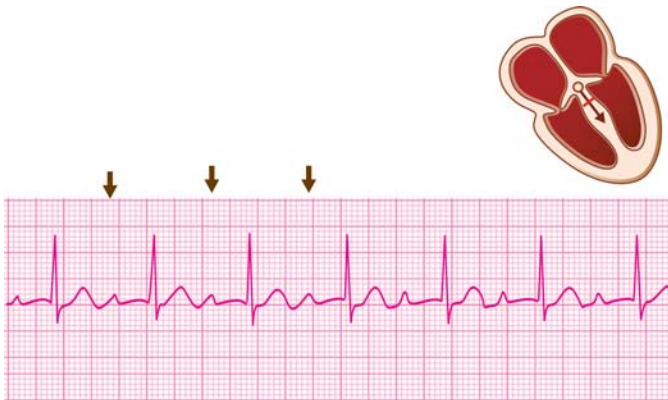

Fig. 15.3: First-degree A-V block: Prolonged P-R interval

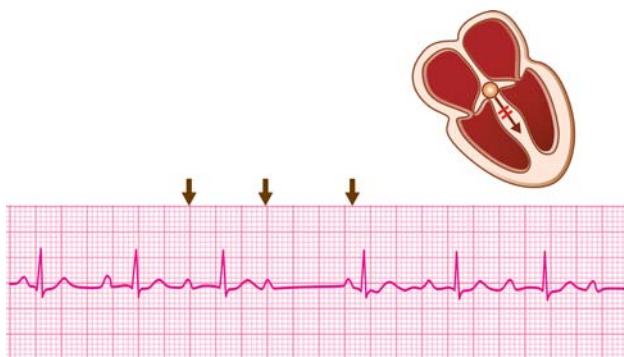


Fig. 15.4: Second-degree A-V block (Mobitz Type I): Wenckebach phenomenon

- ❖ **2° A-V block** In second-degree A-V block, there is intermittent dropping of one or more beats. The P wave of the dropped beat is inscribed normally as atrial activation proceeds as usual. Only the QRS complex is missing because of failure of ventricular activation.

Second-degree A-V block is further classified as Mobitz Type I block and Mobitz Type II block.

In Mobitz Type I block, there is a gradual lengthening of the P-R interval from beat-to-beat till a P wave is not followed by a QRS complex (**Fig. 15.4**), indicating a progressively increasing difficulty in A-V nodal transmission. After the dropped beat the P-R interval again shortens, indicating recovery of the A-V node, but then begins to lengthen once again. This sequence of events is referred to as the Wenckebach phenomenon.

In Mobitz Type II block, the P-R interval remains constant but there is intermittent dropping of beats, with some P waves not followed by a QRS complex (**Fig. 15.5**). The ratio of the number of P waves to the number of QRS complexes represents the conduction sequence. If every

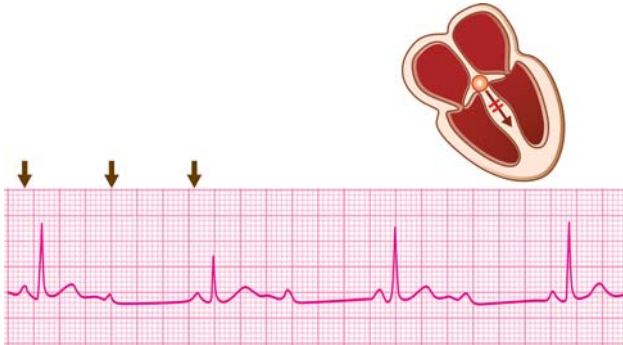


Fig. 15.5: Second-degree A-V block (Mobitz Type II):
2:1 A-V conduction

second P wave is blocked, it is 2:1 A-V block and if every third P wave is blocked, it is 3:2 A-V block.

- ❖ **3° A-V block** Third-degree A-V block is also known as complete heart block. In this type of A-V block, no sinus beat conducts to the ventricles as all of them get blocked in the A-V node. Therefore, while the atria are activated by the S-A node, the ventricles are activated by a subsidiary pacemaker in the His bundle system or in the ventricle.

In other words, the atria and ventricles work independent of each other and asynchronously, leading to atrioventricular (AV) dissociation.

In third-degree A-V block, P waves occur at a rate of 60-80 beats/min that represents the discharge rate of the S-A node. The rate of which QRS complexes occur depends upon the location of the subsidiary pacemaker.

If the lower pacemaker is situated in the His bundle system, the ventricular rate is 40-60 beats/min and the QRS complexes are narrow since intraventricular conduction of beats is normal (**Fig. 15.6A**).

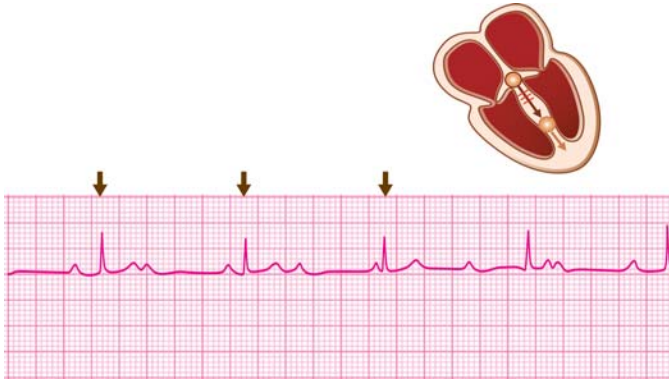


Fig. 15.6A: Third-degree (complete) A-V block:
Narrow QRS complexes

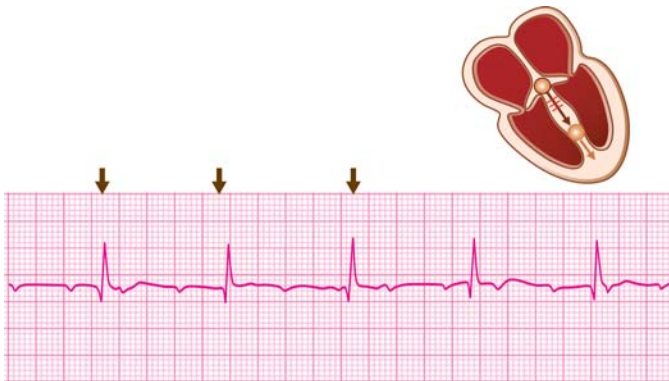


Fig. 15.6B: Third-degree (complete) A-V block:
Wide QRS complexes

However, if the lower pacemaker is situated in the ventricles, the rate is 20-40 beats/min and the QRS complexes are wide as the ventricles are activated in a slow random fashion (**Fig. 15.6B**).

Clinical Relevance of Pauses in Rhythm

Pause After Premature Beat

The compensatory pause after an atrial premature beat is incomplete while a ventricular premature beat is followed by a complete compensatory pause. This fact helps to differentiate a ventricular premature beat from an atrial premature beat conducted aberrantly to the ventricles.

An inordinately long pause after an atrial premature beat (prolonged sinus node recovery time) indicates sinus node dysfunction, the so called 'sick sinus syndrome'.

The awareness of a ventricular premature beat by the patient and its clinical recognition depend upon the compensatory pause and the increased force of the sinus beat following the premature beat.

Pause After Blocked Premature Beat

Atrial premature beat that fail to conduct to the ventricles produce pauses that resemble those due to S-A block or A-V block. Proper recognition of such pauses is important as their clinical significance and management are different.

Non-conducted atrial premature beats are frequently observed in elderly patients who have advanced A-V nodal disease and in the presence of digitalis toxicity.

Pause Due to Second-Degree S-A Block

Sinoatrial block may be observed in these conditions:

- ❖ Drugs, e.g. beta-blockers, diltiazem, digitalis.
- ❖ Sinus node dysfunction or sick sinus syndrome.

The "sick sinus syndrome" is a clinical condition caused by a diseased sinus node which fails to produce sufficient impulses. It is observed in elderly patients and is believed to be caused by a degenerative condition (amyloidosis) or infiltration of the atria by a fibrocalcerous process.

150 ECG Made Easy

The ECG features of sick sinus syndrome are:

- ❖ Sinus bradycardia
- ❖ Sinoatrial block
- ❖ Slow atrial fibrillation
- ❖ Junctional escape rhythm.

Other clinical features of this syndrome are:

- ❖ Inadequate tachycardia with stimuli
- ❖ Atropine resistant bradyarrhythmias
- ❖ Excessive beta-blocker sensitivity
- ❖ Alternating fast and slow rhythms (the “brady-tachy” syndrome).

Symptoms of sick sinus syndrome are:

- ❖ Dizziness, syncope or fainting attacks
- ❖ Fatigue and dyspnea from heart failure
- ❖ Palpitations and angina pectoris
- ❖ Mental confusion and memory defects.

Treatment of sick sinus syndrome includes:

- ❖ Drugs to increase the heart rate, e.g. atropine and sympathomimetic drugs
- ❖ Pacemaker insertion if symptoms due to bradycardia are frequent and severe
- ❖ Antiarrhythmic drugs for tachyarrhythmias which can be used only if an artificial pacemaker is in place or else they may cause severe bradycardia.

Pause Due to Second-Degree A-V Block

Atrioventricular block (second-degree) may be observed in the following conditions:

- ❖ Acute febrile illness
 - Rheumatic fever
 - Diphtheria

- ❖ Drug therapy
 - Digitalis
 - Diltiazem
 - Beta-blockers
- ❖ Coronary artery disease
 - Inferior wall infarction
 - Right coronary artery spasm.

The occurrence of A-V block in a febrile illness like rheumatic fever or diphtheria indicates associated myocarditis. The fact that drugs like propranolol and diltiazem can cause A-V block is put to use in the management of atrial tachycardia to reduce the ventricular rate.

Since the A-V node receives its blood supply from the right coronary artery in 90 percent of subjects, transient A-V blocks are observed in inferior wall myocardial infarction caused by occlusion of the right coronary artery. The same may occur when the right coronary artery undergoes spasm.

Mobitz Type I A-V block is often acute in onset, runs a self-limited course, only occasionally produces symptoms, rarely progresses to complete A-V block, carries a good prognosis and often requires no treatment.

Mobitz Type II A-V block is often chronic, almost always pathological, likely to produce symptoms such as dizziness and fainting, may progress to complete A-V block, carries an adverse prognosis and often requires cardiac pacing.

In the management of symptomatic A-V block, although drugs like atropine and adrenaline can temporarily accelerate the ventricular rate, cardiac pacing is the definitive form of treatment especially in patients with recurrent and severe symptoms.

Pauses Causing Bigeminal Rhythm

We have examined above the various causes of pauses during a regular rhythm. If these pauses occur regularly and are so

152 ECG Made Easy

timed that they follow a pair of beats, they produce a characteristic rhythm called bigeminal rhythm.

The causes of a bigeminal rhythm are:

- ❖ Alternate atrial premature beats
(extrasystolic atrial bigeminy)
- ❖ Alternate ventricular premature beats
(extrasystolic ventricular bigeminy)
- ❖ Blocked atrial ectopics after two beats
- ❖ 3:2 second-degree sinoatrial block
- ❖ 3:2 second-degree atrioventricular block.

16

Fast Regular Rhythm with Narrow QRS

REGULAR FAST RHYTHM

A regular cardiac rhythm that exceeds a rate of 100 beats per minute indicates rapid discharge of impulses from the pacemaker governing the rhythm of the heart.

If the QRS complexes during such a rhythm are narrow, it indicates normal intraventricular conduction and that the pacemaker is supraventricular in location, be it the S-A node, the atrial myocardium or the A-V junction.

Let us examine the specific arrhythmias that are associated with these features.

SINUS TACHYCARDIA

The occurrence of sinus node discharge at a rate exceeding 100 beats/min constitutes sinus tachycardia. The rhythm is regular and the P wave as well as QRS morphology are obviously as in normal sinus rhythm (**Fig. 16.1**).

Sinus tachycardia generally does not exceed a rate of 150 beats/min as the A-V node cannot conduct more than 150 impulses in a minute. Therefore, in sinus tachycardia, the R-R interval ranges from 10 mm (heart rate 150) to 15 mm (heart rate 100).

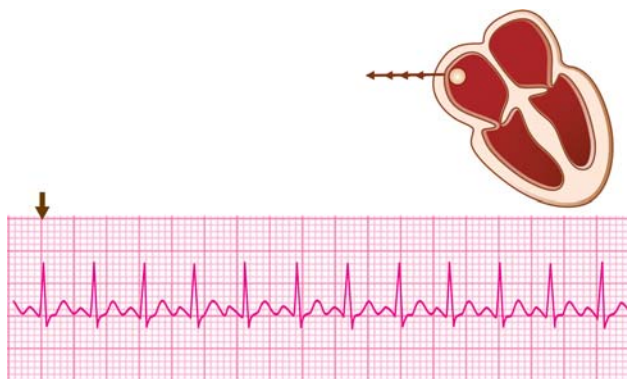


Fig. 16.1: Sinus tachycardia: Narrow QRS complexes; rate < 150/min

ATRIAL TACHYCARDIA

Atrial tachycardia or supraventricular tachycardia, is a fast regular rhythm produced by two possible mechanisms:

- ❖ Rapid impulse discharge from ectopic focus in the atrium (ectopic tachycardia; 10% cases).
- ❖ Repetitive circus movement in a closed re-entrant circuit (reentrant tachycardia; 90% cases).

The circuit is either composed of two pathways within the A-V node (AV nodal reentrant tachycardia—AVNRT; 50% cases) or consists of an A-V nodal pathway and an accessory bypass tract alongside the A-V node (AV reentrant tachycardia—AVRT; 40% cases). The two pathways of the reentrant circuit are connected to each other functionally, to form a closed loop.

An atrial impulse first passes anterogradely down one of the pathways, the other pathway being in the refractory period. The impulse then returns retrogradely through the other pathway, which has by now recovered its conductivity. In this way, repetitive circulation of impulses occurs to produce a sustained atrial tachycardia.

The heart rate in paroxysmal atrial tachycardia is 150 to

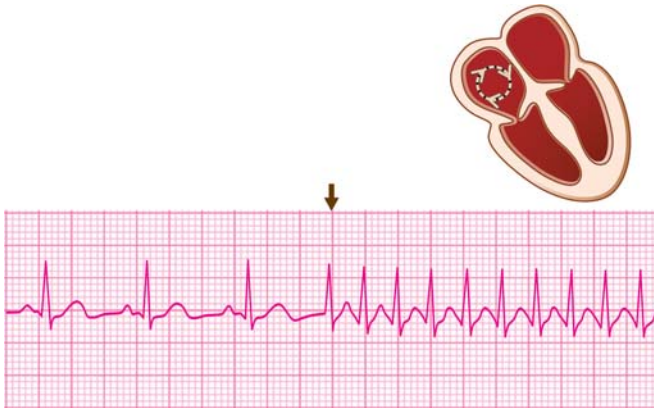


Fig. 16.2: A-V reentrant tachycardia: Narrow QRS complexes, rate > 150/min

200 beats per minute (**Fig. 16.2**), if a reentrant circuit is involved. It tends to be slower in ectopic atrial tachycardia (120 to 150 beats/min) as the A-V node cannot conduct more than 150 atrial impulses per minute.

The heart rate can exceed a rate of 200 beats/min if a true accessory bypass tract is involved as in the WPW syndrome. This is because in the WPW syndrome, the impulses can bypass the decremental influence of the A-V node by passing down the accessory pathway.

In most cases of atrial tachycardia, the ventricular rate is the same as the atrial rate representing 1:1 A-V conduction. This is always true for a reentrant tachycardia because the block of even a single impulse can interrupt the continuous reciprocating process and terminate the tachycardia. However, an ectopic atrial tachycardia can coexist with a physiological block such as 2:1 A-V block.

The contour and polarity of the P waves in atrial tachycardia is

different from P wave morphology during sinus rhythm. In ectopic atrial tachycardia, the P waves are generally upright while they may be inverted in reciprocating tachycardia, signifying retrograde atrial activation. The P waves are often not discernible in atrial tachycardia as they are fused with the T waves.

The QRS complex of an atrial tachycardia has a normal narrow configuration if atrial impulses pass anterogradely through the AV node (orthodromic tachycardia). The QRS complexes are wide if atrial beats pass through the bypass tract and retrogradely through the AV node (antidromic tachycardia). At times, the atrial impulses find one of the two bundle branches refractory to conduction and pass down only one bundle branch. This produces a bundle branch block like configuration of the QRS complexes and is known as aberrant ventricular conduction of an atrial tachycardia.

Other causes of wide QRS complexes during atrial tachycardia are pre-existing conditions producing QRS abnormalities such as true bundle branch block, intraventricular conduction defect or the WPW syndrome.

The differences between sinus tachycardia and atrial tachycardia have been tabulated in **Table 16.1**.

The features of a paroxysmal atrial tachycardia that differentiate it from sinus tachycardia are:

- ❖ Heart rate of 150-220 beats/min
- ❖ Clock-like regularity of rhythm
- ❖ Sudden onset of tachycardia
- ❖ P waves different from sinus P waves
- ❖ History of recurrent episodes of tachycardia
- ❖ Abrupt termination with vagal manoeuvres.

An atrial tachycardia arising from an ectopic focus can be

Table 16.1: Differences between sinus and atrial tachycardia

	<i>Atrial tachycardia</i>	<i>Sinus tachycardia</i>
Heart rate	150-220/min	100-150/min
Regularity	Clock-like	Respiratory variation
P wave	Ectopic/Inverted	Normal
Onset	Sudden	Gradual warming up
Effect of vagal manoeuvres	Termination	Slowing of rate
ECG during normal rhythm	APCs or WPW syndrome	Often normal

differentiated from a tachycardia due to a reentrant mechanism by the features mentioned in **Table 16.2**.

An atrial tachycardia with aberrant ventricular condition closely resembles a ventricular tachycardia. Features that favor the diagnosis of atrial tachycardia are:

- ❖ Clock-like regular rhythm

Table 16.2: Differences between ectopic and reentrant tachycardia

	<i>Ectopic tachycardia</i>	<i>Reentrant tachycardia</i>
Heart rate	120-150/min	More than 150/min
Onset and offset	Gradual	Sudden
P wave	Ectopic. Visible	Inverted. Rarely visible
A-V block	Can coexist	Never. 1:1 conduction
Effect of vagal manoeuvres	Slowing	Termination
Past history	Not significant	Of previous episodes
Organic heart disease	May be present	Generally absent

158 ECG Made Easy

- ❖ Maintained P-QRS relationship
- ❖ QRS width less than 0.14 sec
- ❖ Stable hemodynamic parameters
- ❖ Termination with carotid sinus pressure.

ATRIAL FLUTTER

Atrial flutter is a fast rhythm caused by rapid discharge of an ectopic atrial focus or alternatively, a self-perpetuating re-entrant circuit located in the atrium. Therefore, it is obvious that atrial flutter is akin to atrial tachycardia.

The major difference between atrial flutter and atrial tachycardia is in terms of the atrial rate. The atrial rate in atrial flutter is 220-350 beats per minute. The P waves are replaced by flutter waves (F waves) that occur rapidly at this rate and give the baseline a corrugated or saw-toothed appearance (**Fig. 16.3**).

It is understandable that all flutter waves cannot activate the ventricles. Therefore, there exists a physiological A-V block whereby the ventricular rate is a fraction of the atrial rate. If there is 2:1 physiological A-V block, two flutter waves are

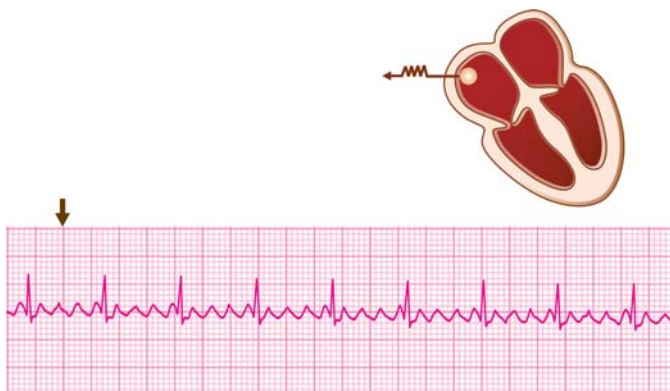


Fig. 16.3: Atrial flutter: Discrete F waves; regular rhythm

followed by one QRS complex while if the block is 4:1, four flutter waves are followed by one QRS complex.

Generally, the even ratios of physiological A-V block (2:1, 4:1) are more common than odd ratios (3:1, 5:1). Assuming an atrial flutter at an atrial rate of 300 beats/min, with 2:1 block, the ventricular rate would be 150 beats/min and with 4:1 block it would be 75 beats/min.

Atrial flutter is quite akin to atrial tachycardia in terms of causation, mechanism and ECG features. The two conditions can be differentiated from each other by the features enumerated in **Table 16.3**.

Atrial flutter with 2:1 physiological A-V block resembles a sinus tachycardia at a rate of 120-150 beats/min if one of the two flutter waves is buried in the QRS complex and the other is mistaken for the P wave. The diagnosis of atrial flutter can be clinched if after carotid sinus massage, A-V nodal refractoriness increases and both the flutter waves become identifiable.

Clinical Relevance of Fast Regular Narrow QRS Rhythm

Table 16.3: Differences between atrial flutter and atrial tachycardia

	<i>Atrial flutter</i>	<i>Atrial tachycardia</i>
Atrial rate	220-350/min	150-220/min
Ventricular rate	1/2 or 1/4 of atrial rate (2:1 or 4:1 A-V block)	Same as atrial rate (1:1 A-V conduction)
P waves	Saw-tooth like flutter waves	Ectopic/inverted P waves
Effect of carotid sinus pressure	Increased degree of A-V block	Termination in PAT. Slowing in ectopic tachycardia

Sinus Tachycardia

Sinus tachycardia represents response of the S-A node to a variety of physiological and pathological stimuli, mediated by the nervous and hormonal control over the pacemaker discharge rate.

The causes of sinus tachycardia are:

- ❖ Exercise and anxiety
- ❖ Fever and volume depletion
- ❖ Hypoxemia and anemia
- ❖ Hypotension and heart failure
- ❖ Thyrotoxicosis and pregnancy
- ❖ Caffeine, nicotine and alcohol
- ❖ Atropine and beta-agonists
- ❖ Hemorrhage and hypoglycemia
- ❖ Pericarditis and myocarditis
- ❖ Massive pulmonary embolism.

In febrile patients, for each degree Fahrenheit rise in temperature, the heart rate rises by 8 to 10 beats/min. A sinus tachycardia in excess of the predicted rate is a feature of myocarditis, rheumatic fever or bacterial endocarditis.

A sinus tachycardia at a rate less than expected in a febrile person is known as relative bradycardia and is observed in typhoid fever and in brucellosis.

Failure to develop sinus tachycardia in response to a physiological or pathological stimulus and in the absence of beta-blocker or calcium-blocker therapy is a sign of sinus node dysfunction, the so called sick sinus syndrome.

Sinus tachycardia is not a primary arrhythmia and therefore, treatment should be directed towards the basic underlying

condition. Examples are antipyretics for fever, oxygen for hypoxemia, fluids for volume depletion and tranquilizers for emotional upset.

Specific therapy should be instituted when sinus tachycardia is an expression of the underlying disease. Such diseases include severe anemia, thyrotoxicosis, congestive heart failure, rheumatic fever and bacterial endocarditis.

Withdrawal of smoking, beverages, spices, anticholinergic drugs and adrenergic agents is mandatory to control the tachycardia. Propranolol and mild tranquilizers are indicated for supportive therapy of sinus tachycardia associated with anxiety, anemia and thyrotoxicosis.

Atrial Tachycardia

As a series of three or more successive atrial ectopic beats constitutes an atrial tachycardia, the causes of ectopic atrial tachycardia are similar to those of atrial premature beats. These include:

- ❖ Rheumatic fever
- ❖ Digitalis toxicity
- ❖ Thyrotoxicosis
- ❖ Myocardial ischemia
- ❖ Acute myocarditis
- ❖ Adrenergic drugs
- ❖ Cardiac surgery.

Paroxysmal reentrant atrial tachycardia is most often based on a reciprocal mechanism involving a bypass tract or dual intra-nodal pathway. Episodes of atrial tachycardia are one of the manifestation of pre-excitation syndrome, the WPW syndrome.

In the absence of WPW syndrome, paroxysmal atrial tachycardia (PAT) is generally not associated with organic heart disease. If properly managed, PAT does not alter life-expectancy and has an excellent prognosis.

PAT coexisting with the WPW syndrome carries a poorer prognosis because of the risk of degeneration into ventricular tachycardia.

A reentrant atrial tachycardia always exists with 1:1 A-V conduction since the reciprocating circuit would break with the block of even a single beat. This is also the reason why vagal stimulation methods and drugs that block the A-V node can terminate the tachycardia.

On the other hand, an ectopic atrial tachycardia can coexist with A-V block and is popularly known as 'PAT with block'. Digitalis toxicity is the most common cause of this rhythm.

Symptoms due to atrial tachycardia depend upon the atrial rate, the duration of the tachycardia and the presence of heart disease.

A fast atrial tachycardia causes palpitation and neck pulsations. Angina pectoris may occur due to increased myocardial oxygen demand and reduced coronary filling time.

Prolonged atrial tachycardia can cause dizziness or syncope due to decline in cardiac output (shortened ventricular filling time) and loss of atrial contribution to ventricular filling.

Termination of the tachycardia is often followed by polyuria due to the release of atrial natriuretic peptide (ANP) by myocardial stretch.

Atrial tachycardia needs to be differentiated clinically and electrocardiographically from various other rhythms that closely resemble it. Differentiation from sinus tachycardia is important since atrial tachycardia needs more aggressive treatment.

The causation and to some extent, the response to treatment of ectopic atrial tachycardia is somewhat different from that of reentrant tachycardia and they need to be differentiated from each other.

Since the heart rate in atrial tachycardia is rapid, P waves are not discernible and therefore differentiation from junctional

tachycardia becomes difficult. However, since treatment of both is similar, the umbrella term supraventricular tachycardia (SVT) is used and further distinction becomes redundant.

Finally, atrial tachycardia with aberrant ventricular conduction needs to be identified as distinct from ventricular tachycardia since their causation, clinical presentation, prognosis and treatment are entirely different.

The Wolff-Parkinson-White (WPW) syndrome is a distinct electrocardiographic entity wherein an accessory pathway, the Bundle of Kent, connects the atrial to the ventricular myocardium, bypassing the A-V node. This produces abnormalities of the QRS complex, P-R interval, S-T segment and the T wave, during sinus rhythm.

The clinical importance of the WPW syndrome lies in the fact that it predisposes to paroxysmal atrial tachycardia since the bypass tract forms a reentrant circuit with the regular conduction pathway. Paroxysmal tachycardia in the presence of WPW syndrome needs to be differentiated from a PAT without the accessory pathway since its management is somewhat different.

A paroxysm of atrial tachycardia in the presence of an underlying WPW syndrome is suggested if it meets one of the following criteria:

- ❖ ECG recorded in sinus rhythm shows a short P-R interval, delta wave and a wide QRS complex.
- ❖ The ventricular rate exceeds 200 beats/min indicating absence of physiological A-V block.
- ❖ Inverted P waves are observed indicating retrograde atrial activation and conduction.

There are several modalities of treatment of PAT. Since reentry through an intra-nodal pathway or a bypass tract accounts for 90 percent of PAT, we shall first discuss the management of reentrant PAT.

The first step is to try methods of vagal stimulation so as to

164 ECG Made Easy

reduce A-V conduction and consequently the ventricular rate. Vagal manoeuvres that may be attempted include carotid sinus massage, supraorbital pressure, Valsalva manoeuvre or immersion of face in ice-cold water.

Carotid sinus massage is performed behind the angle of the mandible and over the carotid artery, for 5 to 10 seconds at a time. Before commencing massage, the carotid artery on both sides should be auscultated for a bruit. If a bruit is present, carotid massage should not be done or else an embolus may dislodge from an atheromatous plaque.

Carotid massage should be done on one side at a time and not simultaneously since bilateral massage can cause a precipitous fall in cerebral circulation.

If vagal manoeuvres fail to abort the tachycardia, a drug acting on the A-V node may be given intravenously.

The protocol of drug therapy for PAT is:

Adenosine 6 mg IV over 1-3 sec.; repeat 12 mg IV after 1-2 min; repeat 12 mg IV after another 1-2 min; till sinus rhythm is restored or 30 mg is given.

OR

Diltiazem 15-20 mg (0.25 mg/kg) IV over 2 min; repeat 20-25 mg (0.35 mg/kg) IV over 2 min after 15 min if needed.

OR

Amiodarone 150 mg IV over 10 min (15 mg/min); repeat 150 mg IV over 10 min; repeat every 10 min if needed.

Oral diltiazem, amiodarone or metoprolol is prescribed after restoration of sinus rhythm to prevent recurrence of PAT.

If a pacemaker is already in place, delivering a single programmed extrastimulus or overdrive pacing can break the reentrant circuit and restore sinus rhythm.

Electrical cardioversion with 80-100 Joules is the treatment of choice for atrial tachycardia associated with deranged hemodynamics and a low cardiac output.

Surgical ablation of the A-V junction may be considered as a last resort in frequent, recurrent drug-refractory PAT which, however, makes the concomitant insertion of a permanent pacemaker mandatory.

The management of ectopic atrial tachycardia is similar to that of PAT with these differences:

- ❖ Vagal manoeuvres are less likely to be effective
- ❖ Digoxin is to be avoided as it causes ectopic beats
- ❖ Programmed extra-stimulus cannot restore sinus rhythm
- ❖ Long-term prophylactic treatment is not indicated
- ❖ Electrical cardioversion and surgical ablation have no role.

The management of paroxysmal atrial tachycardia in the presence of WPW syndrome is also somewhat different.

- ❖ Vagal manoeuvres would be useful only if anterograde conduction occurs through the A-V node.
- ❖ Digitalis is contraindicated as it enhances conduction down the accessory pathway and may precipitate ventricular fibrillation.
- ❖ Diltiazem and metoprolol reduce tolerance to the high ventricular rate and precipitate congestive heart failure.
- ❖ Amiodarone is the antiarrhythmic agent of choice for the long-term treatment and prevention of arrhythmias associated with the WPW syndrome.

Urgent electrical cardioversion is life-saving in atrial tachycardia associated with unstable hemodynamic parameters.

Cardioversion should be preceded by intravenous heparin and a transesophageal ECHO to exclude an atrial clot. It should follow up by oral anticoagulation for 4 weeks.

The availability of sophisticated electrophysiological studies (EPS) to identify and locate bypass tracts and the development of ablative techniques have revolutionized the management of WPW syndrome.

166 ECG Made Easy

For ablation of the bypass tract, high-frequency AC current is delivered through a thermistor-tipped catheter, which leads to localized heat coagulation.

Radiofrequency ablation (RFA) of the bypass tract can be offered to patients who report recurrent and frequent symptomatic episodes of PAT that produce hemodynamic compromise and are refractory to drug therapy.

RFA is the preferred form of treatment in these subsets:

- ❖ Very short P-R interval on ECG
- ❖ Very short refractory period on EPS
- ❖ Familial syndrome and Ebstein anomaly
- ❖ High-risk professionals, e.g. aircraft pilots and military personnel.

Atrial Flutter

Atrial flutter is quite akin to ectopic tachycardia electrocardiographically, differing from it only in terms of the atrial rate. In terms of causation too, atrial flutter closely resembles atrial tachycardia.

Common causes are:

- ❖ Ischemic heart disease
- ❖ Rheumatic heart disease
- ❖ Acute respiratory failure
- ❖ Thyrotoxicosis
- ❖ Cor pulmonale
- ❖ Myocarditis
- ❖ Pericarditis
- ❖ Cardiac surgery

Compared to its better known counterpart called atrial fibrillation, atrial flutter is less common and generally short-lived. It causes

fewer symptoms and is less likely to cause a left atrial thrombus and subsequent risk of systemic embolization.

As far as the management of atrial flutter is concerned, the heart rate may be controlled by diltiazem or metoprolol as in atrial tachycardia. If conversion to sinus rhythm or to atrial fibrillation is the goal, digoxin or amiodarone may be used.

Digoxin converts atrial flutter to fibrillation with an increase in atrial rate. However, this is of advantage since the ventricular rate declines as the degree of concealed conduction increases. When digitalis is stopped, this often restores sinus rhythm.

If the patient's clinical status is unsatisfactory with angina, hypotension or heart failure, electrical cardioversion with a low energy shock of 10 to 50 Joules is the most effective form of treatment. In fact, atrial flutter is the most responsive of the tachyarrhythmias that revert with electrical cardioversion.

17

Normal Regular Rhythm with Narrow QRS

REGULAR NORMAL RHYTHM

A regular cardiac rhythm at a rate of 60 to 100 beats per minute is considered to be a normal rhythm.

If the QRS complexes during such a rhythm are narrow, it indicates normal intraventricular conduction and that the pacemaker is supraventricular in location. The pacemaker may be the S-A node, in the atrial myocardium or at the A-V junction.

Let us examine the specific arrhythmias that are associated with these features.

NORMAL SINUS RHYTHM

The occurrence of sinus node discharge at a rate of 60 to 100 beats/min constitutes a normal sinus rhythm.

The rhythm is regular, the P wave and QRS complex are normal in morphology and they are related to each other with a 1:1 relationship.

ATRIAL TACHYCARDIA WITH 2:1 A-V BLOCK

In atrial tachycardia, the atrial rate varies from 150 to 200 beats/min. If all atrial impulses are conducted to the ventricles, the ventricular rate is identical.

However, if there exists a physiological 2:1 A-V block and every alternate P wave is followed by a QRS complex, the ventricular rate is half of the atrial rate or 75 to 100 beats/min.

Such a rhythm superficially resembles a normal sinus rhythm with the difference that the P-P interval between successive P waves reflects an atrial rate of 150 to 200 beats/min.

ATRIAL FLUTTER WITH 4:1 A-V BLOCK

In atrial flutter the atrial rate varies from 220 to 350 beats/min. Since all atrial impulses cannot conduct to the ventricles at this rate, there exists a physiological A-V block and the ventricular rate is a fraction of the atrial rate.

If the physiological block is 4:1 and every fourth flutter wave is followed by QRS complex the ventricular rate is one-fourth of the atrial rate or 60 to 80 beats/min.

Such a rhythm superficially resembles a normal sinus rhythm with the difference that the P waves are replaced by rapidly occurring flutter waves.

Atrial flutter can be differentiated from atrial tachycardia (atrial rate 150 to 200 beats/min) with 2:1 block by the fact that the F-F interval between successive F waves indicates an atrial rate of 220 to 350 beats/min.

JUNCTIONAL TACHYCARDIA

Junctional tachycardia is an ectopic rhythm originating from a latent subsidiary pacemaker located in the A-V junction. Normally, this pacemaker is subdued when the cardiac rhythm is governed by the S-A node. However, when the junctional pacemaker undergoes enhancement of its inherent automaticity, it produces a junctional tachycardia.

This rhythm is also known as non-paroxysmal junctional tachycardia to differentiate it from extrasystolic junctional

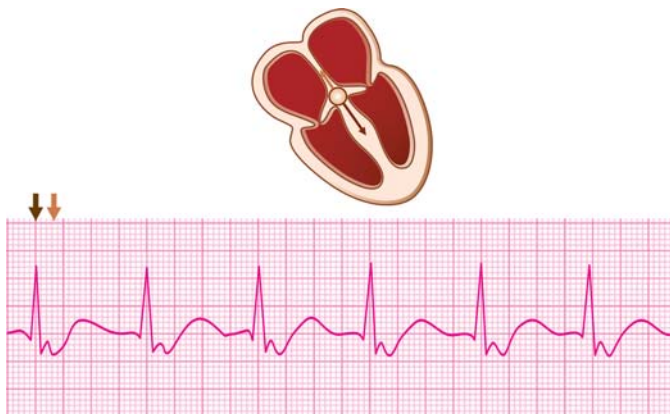


Fig. 17.1: Accelerated junctional rhythm: Inverted P waves just following QRS complexes

tachycardia produced by a series of three or more junctional premature beats. Non-paroxysmal junctional tachycardia is also known as accelerated junctional rhythm.

Junctional tachycardia produces a regular rhythm at a rate of 60 to 100 beats/min which is greater than the inherent rate of the junctional pacemaker (40 to 60 beats/min). The QRS complexes are narrow as in normal sinus rhythm (**Fig. 17.1**).

The distinctive feature of a junctional tachycardia is the typical relationship between P waves and QRS complexes. If the atria are activated retrogradely from the junctional pacemaker, the P waves are inverted and related to the QRS complexes. They may just precede, just follow or be buried in the QRS complexes because of near-simultaneous atrial and ventricular activation.

If the atria continue to be activated by the S-A node, the P waves are upright and unrelated to the QRS complexes. In that case, the junctional pacemaker only activates the ventricles. The ventricular rate is then slightly greater than the atrial rate, that is, the R-R interval is slightly shorter than the P-P interval.

Consequently, there is a progressive shortening of the P-R interval in successive beats till the P wave merges in the QRS complex and then follows it. The P wave, so to say, marches through the QRS complex. This form of atrioventricular dissociation is called isorhythmic A-V dissociation since atrial and ventricular rates are nearly similar.

The P-QRS relationship mentioned above is typical of a rhythm originating from the AV junctional pacemaker. Inverted P waves just precede, just follow or are buried in the QRS complexes.

A junctional escape rhythm has similar features but occurs at a slower rate of 40 to 60 beats/min which is the inherent rate of the junctional pacemaker.

An extrasystolic junctional tachycardia can be differentiated from accelerated junctional rhythm by the fact that it starts abruptly, is often paroxysmal in nature and the ventricular rate exceeds 120 beats/min. The two conditions can be differentiated by features mentioned in **Table 17.1**.

Clinical Relevance of Regular Narrow QRS Rhythm

Normal Sinus Rhythm

A rhythm originating from the S-A node at a rate of 60 to 100 beats/min is a normal sinus cardiac rhythm. It is the most common, but by no means the only cause of a rhythm at this rate.

Table 17.1: Junctional tachycardia versus junctional rhythm

	<i>Extrasystolic junctional tachycardia</i>	<i>Accelerated junctional rhythm</i>
Onset	Abrupt	Slow warm-up
Occurrence	Paroxysmal	Sustained
Ventricular rate	120-150/min	60-100/min

172 ECG Made Easy

Atrial Tachycardia with A-V Block

A fast atrial rhythm such as atrial tachycardia or atrial flutter, when associated with a fixed degree of physiological A-V block, can also produce a normal ventricular rhythm at 60 to 100 beats/min.

Junctional Tachycardia

A junctional tachycardia due to enhanced automaticity of the junctional pacemaker may be observed in:

- ❖ Digitalis toxicity
- ❖ Rheumatic carditis
- ❖ Inferior wall infarction
- ❖ Cardiac surgery
- ❖ Thyrotoxicosis.

When a febrile child develops a junctional tachycardia, rheumatic fever with carditis should be suspected. Thyrotoxicosis is a frequent cause of various atrial tachyarrhythmias including junctional tachycardia.

In a coronary care unit, junctional tachycardia is often observed in cases of inferior wall myocardial infarction after they have recovered from A-V block.

Open heart surgery especially septal repair around the A-V node, may be a cause of junctional tachycardia in the postoperative period.

If a patient is on digitalis for atrial fibrillation, regularization of the cardiac rhythm, even if sinus rhythm is not restored, is often due to the onset of junctional tachycardia. This constitutes one of the markers of digitalis toxicity.

It is difficult and often futile to differentiate an extrasystolic junctional tachycardia from an ectopic tachycardia of atrial origin. They are both supraventricular tachycardias and similar in etiology, significance and management.

Junctional tachycardia is generally asymptomatic as it occurs at the same rate-range as sinus rhythm. Moreover, its onset does not cause significant clinical deterioration as ventricular activation is normal. Only the loss of atrial contribution to ventricular filling (A-V dissociation) can cause slight decline in cardiac output.

Active treatment of junctional tachycardia is generally not required as it is asymptomatic and has few hemodynamic consequences.

If treatment is required as in patients with poor cardiac reserve, management of the precipitating event is the first goal. This includes management of digitalis intoxication, treatment of rheumatic carditis and control of thyrotoxicosis.

If these do not suffice, atropine can be given to accelerate the sinus rate, overdrive the junctional rhythm and eliminate atrioventricular dissociation.

Antiarrhythmic drugs, electrical cardioversion and external pacing are unnecessary while vagal stimulation methods have no role in the management of junctional tachycardia.

18

Fast Irregular Rhythm with Narrow QRS

IRREGULAR FAST RHYTHM

A cardiac rhythm that exceeds a rate of 100 beats per minute indicates rapid discharge of impulses from the pacemaker governing the rhythm of the heart.

If the QRS complexes during such a rhythm are narrow, it indicates normal intraventricular conduction and that the pacemaker is supraventricular in location.

Further, if the rhythm is irregular, it signifies a variability either in impulse origin or in impulse conduction through the A-V node.

Let us examine the specific arrhythmias that are associated with these features.

ATRIAL TACHYCARDIA WITH A-V BLOCK

In atrial tachycardia, the atrial rate varies from 150 to 220 beats/min. If all atrial impulses are conducted to the ventricles, the ventricular rate is identical.

However, if some atrial impulses are blocked in the A-V node and this physiological A-V block is variable, the QRS complexes occur at varying intervals to produce an irregular rhythm.

ATRIAL FLUTTER WITH VARYING A-V BLOCK

In atrial flutter, the atrial rate varies from 220 to 350 beats/min. Since all atrial impulses cannot conduct to the ventricles at this rate, there exists a physiological A-V block and the ventricular rate is a fraction of the atrial rate.

Generally, the degree of A-V block is fixed and occurs in even ratios such as 2:1, 4:1 and 8:1. If this physiological A-V block is variable, the QRS complexes occur at varying intervals to produce an irregular rhythm.

MULTIFOCAL ATRIAL TACHYCARDIA

Ectopic atrial tachycardia is a fast rhythm produced by a rapid discharge of impulses from a single ectopic atrial focus. If impulses arise from numerous atrial foci, it constitutes a multifocal atrial tachycardia or a chaotic atrial rhythm.

Multifocal atrial tachycardia is a fast rhythm at a rate of 100 to 150 beats/min characterized by a beat-to-beat variability in P wave configuration representing a changing focus of origin of impulses (**Fig. 18.1**).

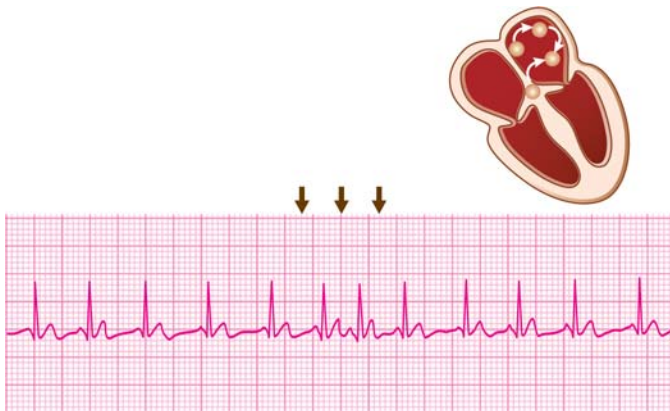


Fig. 18.1: Multifocal atrial tachycardia: Variable P waves

It may not be possible to select the dominant P wave of sinus origin. The P-R interval is also variable because of variability in A-V conduction time, depending upon the focus of origin. Some P waves are premature, others are blocked and they vary in morphology from being upright to inverted.

The ventricular rhythm is irregular because of the varying degree of prematurity of atrial impulses and the occurrence of blocked atrial beats.

Multifocal atrial tachycardia needs to be differentiated from multiple atrial premature beats occurring frequently during sinus rhythm. In the latter case, it is possible to select the dominant P waves of sinus origin. Moreover, the abnormal P waves occur prematurely and the QRS complexes that succeed them are followed by compensatory pauses.

Multifocal atrial tachycardia (MAT) also closely resembles atrial fibrillation, since the ventricular rate is irregular in both rhythms. However, definite P waves are discernible in MAT while they are absent or replaced by fibrillatory waves (f waves) in atrial fibrillation.

A beat-to-beat variation in the P wave morphology is also a feature of a wandering pacemaker. However, in a wandering pacemaker rhythm, the heart rate is 60 to 100 beats/min and not chaotic.

ATRIAL FIBRILLATION

Atrial fibrillation is a grossly irregular fast rhythm produced by the functional fractionation of the atria into numerous tissue islets. Therefore, instead of the sinus impulse spreading evenly and contiguously to all parts of atria, these islets are in various stages of excitation and recovery. Consequently, atrial activation is chaotic and ineffectual in causing hemodynamic pumping.

Although 400 to 500 fibrillatory impulses reach the A-V node per minute, only 100 to 160 of them succeed in eliciting a ventricular response while others are blocked due to A-V nodal

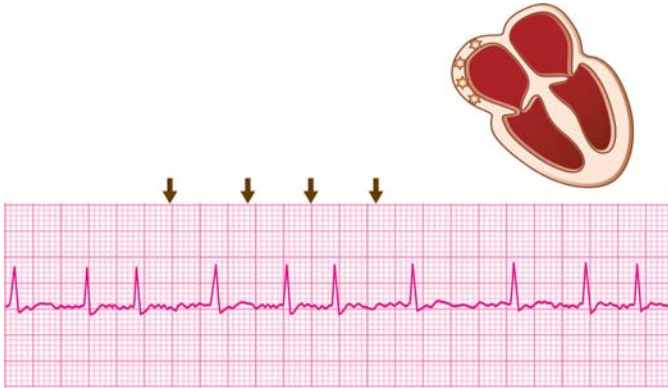


Fig. 18.2: Atrial fibrillation: Fine f waves; irregular rhythm

refractoriness. The random activation of the ventricles produces a grossly irregular ventricular rhythm.

The hallmark of atrial fibrillation is absence of discrete P waves. Instead, there are numerous, small, irregular fibrillatory waves (f waves) that are difficult to identify individually but produce a ragged baseline (**Fig. 18.2**).

In longstanding atrial fibrillation, these undulations are minimal and produce a nearly flat baseline. As mentioned earlier, the ventricular rate is grossly irregular and varies from 100 to 160 beats per minute.

Atrial fibrillation can be differentiated from multifocal atrial tachycardia (MAT) by the fact that P waves are absent or replaced by fibrillatory waves while definite P waves are discernible in MAT.

Atrial fibrillation can be differentiated from atrial flutter by the following features:

- ❖ absence of P waves
- ❖ irregular ventricular rate

178 ECG Made Easy

At times, precise differentiation between the two may be difficult and the rhythm is then known as “flutter-fibrillation”, “coarse fibrillation” or “impure flutter”. The differences between atrial flutter and atrial fibrillation are enlisted in **Table 18.1**.

Table 18.1: Differences between atrial flutter and atrial fibrillation

	<i>Atrial flutter</i>	<i>Atrial fibrillation</i>
Atrial rate	220-350 beats/min	Over 350 beats/min
Ventricular rate	Regular. Fraction of atrial rate	Variable. No relation to atrial rate
Atrial activity	Visible flutter (F) waves	Fine fibrillatory (f) waves
Baseline	Saw-toothed	Ragged
Ventricular activity	Constant R-R interval	Variable R-R interval

Clinical Relevance of Fast Irregular Narrow QRS Rhythm

Atrial Tachycardia with Varying A-V Block

The occurrence of a fast rhythm such as atrial tachycardia or atrial flutter with a variable interval between QRS complexes indicates a variability in conduction of the atrial impulses through the AV node.

Only an ectopic atrial tachycardia and not reentrant atrial tachycardia can coexist with A-V block. ‘PAT with block’ is a popular term for this condition and digitalis toxicity is the most common cause of this rhythm.

Multifocal Atrial Tachycardia

The most frequent cause (in 80 to 90% cases) of multifocal atrial tachycardia is chronic obstructive lung disease with cor pulmonale and respiratory failure in a seriously ill elderly patient.

Aggravating factors that often coexist are:

- ❖ Respiratory tract infection
- ❖ Theophylline or digitalis
- ❖ Coronary artery disease
- ❖ Hypoxia and hypercapnia
- ❖ Electrolyte imbalance
- ❖ Alcohol intoxication.

Multifocal atrial tachycardia not only mimics but often heralds the onset of atrial fibrillation. It has serious prognostic implications and carries a high mortality rate.

The treatment of aggravating factors and improvement of the pulmonary condition are the most important principles in the management of multifocal atrial tachycardia.

Necessary measures include treatment of infection with antibiotics, withdrawal of offending drugs, correcting electrolyte imbalance and administering oxygen.

Multifocal atrial tachycardia is not only refractory to antiarrhythmic drugs like verapamil, beta-blockers and digitalis but these can worsen the cardiorespiratory status and are hence to be avoided.

Atrial Fibrillation

Atrial fibrillation may be observed in virtually all forms of organic heart disease. Causes of atrial fibrillation are:

- ❖ Persistent atrial fibrillation (> 7 days)
 - Congenital heart disease (ASD)
 - Rheumatic heart disease (MS)
 - Coronary artery disease (MR)
 - Hypertensive heart disease
 - Idiopathic cardiomyopathy
 - Cardiac trauma or surgery
 - Constrictive pericarditis.

180 ECG Made Easy

- ❖ Paroxysmal atrial fibrillation (< 7 days)
 - Acute alcoholic intoxication
 - Recurrent pulmonary embolism
 - Thyrotoxicosis
 - WPW syndrome
 - Sick sinus syndrome
 - Lone atrial fibrillation.

In atrial fibrillation, the ventricular rate generally varies from 100 to 150 beats per minute. Faster rates are observed in children, patients of thyrotoxicosis and in the presence of WPW syndrome.

Slower rates are observed during drug treatment with propranolol/atenolol or verapamil/diltiazem as these drugs block the A-V node. Elderly patients with A-V nodal disease may also manifest slow atrial fibrillation.

Regularization of the ventricular rate in a patient on digitalis for atrial fibrillation indicates the onset of junctional tachycardia and is a manifestation of digitalis toxicity.

Symptoms due to atrial fibrillation depend upon:

- ❖ The ventricular rate
- ❖ The severity of heart disease
- ❖ The effectiveness of treatment.

The symptoms frequently observed in atrial fibrillation along with their causation are:

- ❖ Palpitations (fast heart rate).
- ❖ Angina (increased myocardial oxygen demand and shortened coronary filling time).
- ❖ Fatigue (low cardiac output due to loss of atrial contribution to ventricular filling).
- ❖ Dyspnea (pulmonary congestion due to ineffectual atrial contraction).

- ❖ Regional ischemia (systemic embolization from atrial thrombus).

Atrial fibrillation may be life-threatening in these situations:

- ❖ Low cardiac output state with pulmonary edema due to left ventricular dysfunction.
- ❖ Non-compliant ventricle when atrial contribution to ventricular filling is crucial.
- ❖ WPW syndrome where conduction of impulses down the accessory pathway can precipitate ventricular tachycardia or fibrillation.
- ❖ Injudicious treatment of atrial fibrillation such as digitalis usage in WPW syndrome and diltiazem or propranolol for sick sinus syndrome.

Clinical signs of atrial fibrillation are:

- ❖ *Pulse* Irregular and fast pulse rate; pulse deficit which is radial pulse rate less than the heart rate counted by cardiac auscultation.
- ❖ *BP* Low systolic blood pressure; variable pulse pressure.
- ❖ *JVP* Raised jugular venous pressure; absent 'a' waves.
- ❖ *Heart sounds* Beat-to-beat variability in the intensity of the first heart sound.

Various modalities of treatment are available for the management of atrial fibrillation, the judicious use of which can result in clinical improvement of most patients.

- ❖ *Anti-arrhythmic drugs* If hemodynamics of the patient are stable, it suffices to control the ventricular rate by a drug that prolongs the refractory period of the A-V node.

Diltiazem, esmolol or amiodarone may be administered intravenously to control the heart rate.

Diltiazem 15-20 mg over 2 min; repeat after 15 min.

Esmolol 500 mcg/kg over 1-2 min; repeat after 10-15 min.

Amiodarone 150 mg over 10 min; repeat after 10 min.

Oral diltiazem, amiodarone or metoprolol can be prescribed for long-term rate control but should be avoided in the presence of heart failure in which case digoxin is preferable.

These drugs are contraindicated in the presence of WPW syndrome where A-V nodal block would increase the conduction of impulses down the accessory pathway and hence, the likelihood of ventricular fibrillation.

Amiodarone is very effective in the prevention of paroxysmal atrial fibrillation. Moreover, it is effective and safe in the presence of the WPW syndrome as it suppresses conduction of impulses down the accessory pathway.

If rate control does not suffice and symptoms persist, pharmacological cardioversion to restore sinus rhythm may be tried. Drugs used for this indication are dronedarone, flecainide, propafenone, sotalol and ibutilide. Limitations of this approach are modest efficacy, adverse effects, high recurrence rate and proarrhythmic potential.

- ❖ *Anti-coagulants* Long-standing atrial fibrillation produces stasis of blood in the left atrium and promotes the development of thrombi in the atrial cavity and atrial appendage.

Dislodged fragments of these thrombi can enter the systemic circulation as emboli and settle down in any arterial territory to produce effects of regional ischemia.

Examples are blindness due to retinal artery occlusion, hemiparesis due to cerebral circulation, impairment and ischemia of a limb due to brachioradial or iliofemoral obstruction.

Anticoagulants such as caumarin and warfarin are required for long-term use in chronic atrial fibrillation to reduce likelihood of systemic embolization. This particularly applies to patients of rheumatic heart disease and prosthetic valve recipients as well as those with previous history of thromboembolism (stroke, TIA) and documented cardiac thrombus.

Anticoagulation is also indicated two weeks before and several weeks after electrical cardioversion since restoration of sinus rhythm and atrial function is likely to expel systemic emboli.

- ❖ *Electrical defibrillation* If the patient's clinical status is poor and hemodynamics are unstable, electrical cardioversion with 100 to 200 Joules energy is the treatment of choice in an attempt to restore sinus rhythm.

There are two requisites before cardioversion is attempted. Firstly, the patient should not have received digitalis in the previous 48 hours. Digitalis not only increases the threshold for defibrillation but also predisposes to the risk of life-threatening arrhythmias. Secondly, anti-coagulation should be initiated before cardioversion and continued for at least 4 weeks later since atrial thrombi are likely to dislodge as emboli, once sinus rhythm is restored. Cardioversion should not be attempted if there is a documented left atrial clot.

It is difficult to restore sinus rhythm with cardioversion if atrial fibrillation is of more than one year duration and the left atrium is enlarged beyond 4.5 cm in diameter.

- ❖ *Radiofrequency ablation (RFA)* When all conventional remedies have been exhausted and a number of investigational agents have failed to treat atrial fibrillation, a final option is of RFA.

Suitable candidates for RFA are those with significant symptoms who are refractory or intolerant to several antiarrhythmic agents.

Pre-requisites are age below 70 years, left atrial size less than 5 cm and absence of obesity or heart failure.

Advantage is not only freedom from symptoms but also from toxic effects of antiarrhythmic agents and the need to monitor anticoagulant therapy.

19

Fast Regular Rhythm with Wide QRS

FAST WIDE QRS RHYTHM

A regular cardiac rhythm that exceeds a rate of 100 beats per minute indicates rapid discharge of impulses from the pacemaker governing the rhythm of the heart.

If the QRS complexes during such a rhythm are wide, three possibilities have to be considered:

- ❖ The rhythm is ventricular in origin in which case ventricular activation is through myocardium and not the specialized conduction system.
- ❖ The rhythm is supraventricular in origin but impulses are conducted aberrantly to the ventricles through one of the two branches of the His bundle.
- ❖ The rhythm is supraventricular in origin but there are preexisting wide QRS complexes.

Let us go into the individual features of these rhythms.

VENTRICULAR TACHYCARDIA

Ventricular tachycardia is a fast regular rhythm produced by two possible mechanisms:

- ❖ Enhanced automaticity of a latent ventricular pacemaker producing rapid discharge of impulses.
- ❖ Repetitive circus movement of an impulse in a closed re-entrant circuit around a fixed anatomical substrate in the ventricular myocardium.

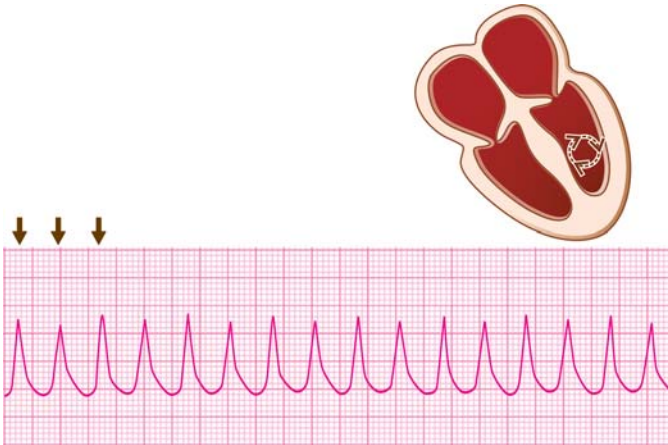


Fig. 19.1: Monomorphic ventricular tachycardia:
Similar QRS complexes

Ventricular tachycardia may be sustained (lasting > 30 sec) or non-sustained (lasting < 30 sec). It may be monomorphic (similar QRS complexes) or polymorphic (variable QRS complexes).

The heart rate in ventricular tachycardia is generally 150 to 200 beats per minute. The rhythm is usually slightly irregular in contrast to the perfect regularity of an atrial tachycardia.

The QRS complexes are bizarre and wide, exceeding 0.14 sec in width and do not conform to a bundle branch block pattern (**Fig. 19.1**).

The atria may continue to be activated by the S-A node but the P-waves are generally not visible as they are buried in the wide QRS complexes.

During ventricular tachycardia, the QRS pattern in all precordial leads is similar (concordant pattern) and the R/S ratio in lead V_6 is less than 1. Moreover, there is left axis deviation or a north-west QRS axis.

186 ECG Made Easy

A ventricular tachycardia closely resembles an atrial tachycardia that is conducted aberrantly to the ventricles. Features that favor the diagnosis of ventricular tachycardia are:

- ❖ Slight irregularity of rhythm
- ❖ Lack of P-QRS relationship
- ❖ QRS width > 0.14 sec with bizarre shape
- ❖ Compromised hemodynamic parameters
- ❖ Presence of serious organic heart disease
- ❖ No response to carotid sinus pressure.

A peculiar variety of ventricular tachycardia called polymorphic ventricular tachycardia is characterized by phasic variation of the QRS complex amplitude and direction (**Fig. 19.2**). Polymorphic VT is often associated with a prolonged Q-T interval and rarely with a normal Q-T interval.

A series of ventricular complexes are up-pointing and then down-pointing. This phenomena occurs in a repetitive continuum.

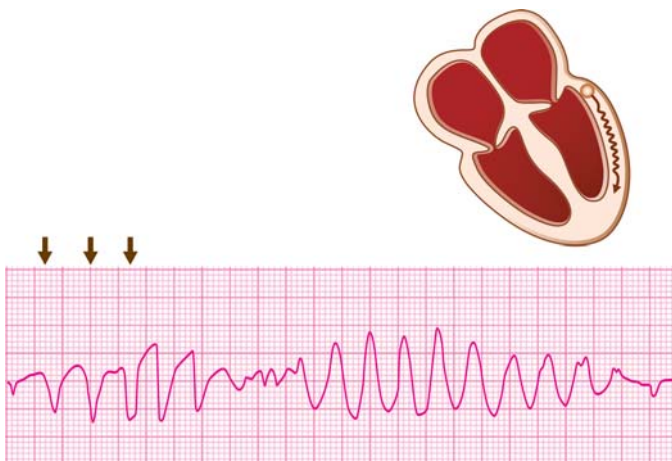


Fig. 19.2: Polymorphic ventricular tachycardia:
Changing QRS configuration

Since this sometimes gives the appearance of rotation of QRS complexes around the isoelectric line, it is designated as *Torsades de pointes*, a ballet term which literally means “twisting of points”.

Torsade de pointes is, as a rule, associated with prolongation of the Q-T interval. The prolonged Q-T interval favors the occurrence of a ventricular premature beat that coincides with the T-wave of the preceding beat (R-on-T phenomenon) and initiates the ventricular tachycardia.

SUPRAVENTRICULAR TACHYCARDIA WITH ABERRANT VENTRICULAR CONDUCTION

Most often, a supraventricular tachycardia is characterized by narrow QRS complexes as a result of synchronized ventricular activation through the specialized conduction system.

Occasionally, the supraventricular impulses find one of the two bundle branches refractory to conduction. In that case, the impulses are conducted only through the other bundle branch producing a situation of aberrant ventricular conduction. Understandably, the QRS complexes conform to a bundle branch block pattern.

The differences between ventricular tachycardia and supraventricular tachycardia with aberrant ventricular conduction are given in **Table 19.1**.

Essentially, the hallmark of ventricular tachycardia is evidence of dissociation between the atria and the ventricles.

The intensity of the first heart sound (S_1) is variable because of variability of the ventricular filling time. Cannon ‘a’ waves are seen in the neck veins because of atrial contraction on a closed tricuspid valve.

Capture beats and fusion beats are produced by an atrial stimulus occasionally finding the ventricular conduction system receptive to depolarization. A capture beat “captures” the

Table 19.1: Differences between ventricular tachycardia and SVT with aberrant conduction

	<i>Ventricular tachycardia</i>	<i>SVT with aberrancy</i>
Regularity of rhythm	Slightly irregular	Clock-like regularity
P-QRS relationship	A-V dissociation	Maintained
Heart sounds	Variable S ₁	Constant S ₁
Cannon waves	May be seen	Never seen
Capture/fusion beats	May be seen	Never seen
QRS-width	>0.14 sec.	0.12-0.14 sec.
QRS-morphology	Bizarre	Triphasic
Precordial leads	rS V ₁ to V ₆	rS to Rs
QRS in lead V ₆	rS; R<S	Rs; R>S
QRS axis	North-west	Normal
Hemodynamics	Compromised	Stable
Organic heart disease	Often present	Often absent
Response to carotid sinus pressure	No response elicited	Slowing or termination

ventricle completely to produce a normal narrow QRS complex in the midst of a ventricular tachycardia.

A fusion beat “captures” the ventricle partially to produce a QRS complex which is a blend of normal narrow QRS and a VPC-like QRS complex.

SUPRAVENTRICULAR TACHYCARDIA WITH PRE-EXISTING QRS ABNORMALITY

It is known that certain conditions produce an abnormality of ventricular conduction even in normal sinus rhythm, causing an abnormality of QRS morphology.

Three well known examples are:

- ❖ Bundle branch block
- ❖ WPW syndrome
- ❖ Intraventricular conduction defect.

If a supraventricular tachycardia occurs in the presence of a pre-existing QRS abnormality, it is naturally expected to have wide QRS complexes.

A bundle branch block produces a triphasic QRS contour while an intraventricular conduction defect results in bizarre QRS morphology. The WPW syndrome is characterized by a delta wave on the ascending limb of the QRS complex.

Clinical Relevance of Fast Regular Wide QRS Rhythm

Ventricular Tachycardia

A series of three or more successive ventricular ectopic beats constitutes a ventricular tachycardia.

A ventricular tachycardia that lasts for more than 30 seconds and requires cardioversion for termination is called sustained ventricular tachycardia. A non-sustained ventricular tachycardia lasts for less than 30 seconds and ends spontaneously.

Ventricular tachycardia is considered repetitive or recurrent if three or more discrete episodes are documented, while chronic ventricular tachycardia is that in which recurrent episodes occur for over a month.

As three or more ventricular premature complexes (VPCs) constitute ventricular tachycardia (VT), the causes of VT are similar to those of VPCs.

Causes of non-sustained ventricular tachycardia are:

- ❖ Pharmacological agents
 - Theophylline
 - Sympathomimetics

190 ECG Made Easy

- ❖ Acute myocardial insult
 - Ischemia
 - Reperfusion
- ❖ Metabolic disorder
 - Hypoxia
 - Acidosis
 - Hypokalemia
- ❖ Cardiac trauma
 - Surgical
 - Accidental
 - Catheterization
- ❖ Drug intoxication
 - Digitalis
 - Quinidine.

Sustained ventricular tachycardia (scar VT) is more often based on structural heart disease where a fixed anatomical substrate facilitates a reentrant mechanism.

Causes of sustained ventricular tachycardia are:

- ❖ Myocardial scar
 - Infarction
 - Aneurysm
- ❖ Myocardial disease
 - Cardiomyopathy
 - Myocarditis
 - RV dysplasia
- ❖ Congestive failure
 - Ischemic
 - Hypertensive

- ❖ Valvular abnormality
 - Rheumatic heart disease
 - Mitral valve prolapse.

Symptoms due to ventricular tachycardia depend on:

- ❖ The ventricular rate
- ❖ The duration of tachycardia
- ❖ Presence or absence of heart disease
- ❖ Severity of heart disease, if it is present.

Symptoms of sustained ventricular tachycardia with underlying heart disease and their causation are:

- ❖ Palpitation (fast heart rate).
- ❖ Angina (increased oxygen demand and shortened coronary filling time).
- ❖ Dyspnea (pulmonary edema due to loss of atrial contribution to ventricular filling).
- ❖ Syncope (low cardiac output state).

Clinical signs often observed during sustained ventricular tachycardia are:

- ❖ *Pulse* Fast and irregular pulse.
- ❖ *BP* Low systolic blood pressure.
- ❖ *JVP* Raised jugular venous pressure.
- ❖ *Heart sounds* Systolic murmur and S₃ gallop.

The prognosis of sustained ventricular tachycardia depends upon the seriousness of the underlying cardiac disease particularly severity of coronary disease and degree of left ventricular dysfunction. The prognosis is particularly poor in ventricular tachycardia developing after acute myocardial infarction.

Markers of electrical instability in survivors of acute myocardial infarction are:

192 ECG Made Easy

- ❖ Documented serious ventricular arrhythmias on 24 hour ambulatory Holter monitoring or detected by an implantable loop recorder (ILR).
- ❖ Reproducible sustained ventricular tachycardia on programmed electrical stimulation (PES).
- ❖ Late depolarization potentials detected on signal averaged electrocardiogram (SAECG).
- ❖ Q-T dispersion and T wave alternans.

The management of ventricular tachycardia depends upon the following factors:

- ❖ Sustained/non-sustained tachycardia
- ❖ Symptomatic/asymptomatic tachycardia
- ❖ Presence/absence of heart disease
- ❖ Presence/absence of cardiac decompensation.

The modalities of treatment of ventricular tachycardia are pharmacological, electrical and surgical.

- ❖ **Pharmacological therapy** Non-sustained ventricular tachycardia in an asymptomatic individual without organic heart disease only requires withdrawal of sympathomimetic drugs, and correction of any metabolic disorder or electrolyte imbalance.

If the ventricular tachycardia is sustained and symptomatic, sympathetic stimulation by stress, exercise or adrenergic drugs is the most common cause, in the absence of heart disease. This is known as catecholaminergic VT. Such patients respond well to beta blockade with metoprolol.

Polymorphic VT with normal Q-T interval is observed in myocardial ischemia, infarction, myocarditis and arrhythmogenic right ventricular dysplasia (ARVD). Such patients too respond well to beta blockers.

If sustained symptomatic ventricular tachycardia occurs in the presence of organic heart disease, the line of treatment depends upon the hemodynamic status. All such patients

are best managed in an intensive cardiac care unit under the expert guidance of a cardiologist.

If the hemodynamics are stable, pharmacological anti-arrhythmic therapy is initiated (chemical cardioversion). The drugs of choice are lidocaine and amiodarone. First, a bolus dose of the drug is administered intravenously to be followed by a maintenance infusion.

The protocol of IV drug therapy of VT is:

Amiodarone 150 mg IV over 10 min (15 mg/min); repeat 150 mg IV every 10 min as needed.

OR

Lidocaine 0.5-0.75 mg/kg IV; repeat 0.5-0.75 mg/kg IV every 5-10 min as needed to a maximum of 3 mg/kg.

Once sinus rhythm is restored, an infusion of the rhythm converting drug is initiated as:

Amiodarone 360 mg IV over next 6 hrs (1 mg/min); maintain at 540 mg IV over next 18 hrs (0.5 mg/min)

OR

Lidocaine 2-4 mg/min (30-60 μ g/kg/min).

Once the crisis period has been tided over, oral maintenance treatment with amiodarone may be instituted to prevent recurrence. Alternative drugs are flecainide, ibutilide, propafenone and sotalol.

Although one of these drugs may be used empirically, the ideal method is to select one of these drugs after an electrophysiological study.

The drug that renders the ventricular tachycardia non-inducible by programmed electrical stimulation, is the one most likely to prevent recurrence of ventricular tachycardia.

- ❖ **Electrical cardioversion** If the hemodynamics are compromised with hypotension, myocardial ischemia, congestive heart failure and cerebral hypoperfusion, the ventricular tachycardia needs prompt termination by cardioversion.

A non-synchronized electrical shock of 50 to 100 J is the procedure of choice. It may be repeated with increasing energy of shock till sinus rhythm is restored. If to begin with, there is circulatory collapse and the peripheral pulses are not palpable, the initial dose of the DC shock should be 200 to 360 J.

Once sinus rhythm has been restored, long-term oral pharmacological treatment may be initiated.

- ❖ **Surgical treatment** Since a fixed anatomic substrate such as myocardial scar from previous infarction is often the basis of recurrent ventricular tachycardia, a surgical procedure can be offered for permanent cure.

Surgical techniques available are endocardial resection and encircling ventriculotomy.

The modalities of treating polymorphic VT with Q-T prolongation, are quite different from those employed for monomorphic VT.

- ❖ In the acute setting, drug therapy which is useful is the infusion of magnesium sulphate or isoproterenol (beta-blocker). If the patient responds to beta-blockade, long-term antiadrenergic therapy is initiated or cervical sympathetic ganglionectomy is offered.
- ❖ If the patient does not respond to the above measures, overdrive ventricular pacing can be attempted. Alternatively electrical cardioversion is performed, particularly in the presence of ischemia, heart failure or hypotension.
- ❖ An implantable cardioverter defibrillator (ICD) device is offered to those with history of recurrent syncope, family history of sudden cardiac death (SCD) or to survivors of cardiac arrest and non-responders to beta-blocker therapy.

20

Normal Regular Rhythm with Wide QRS

NORMAL WIDE QRS RHYTHM

A regular cardiac rhythm at a rate of 60 to 100 beats per minute is considered to be a normal rhythm.

If the QRS complexes during such a rhythm are wide, it indicates abnormal intraventricular conduction of the impulses from the S-A node. The P waves and the QRS complexes during sinus rhythm maintain a 1:1 relationship with each other.

The well-known causes of wide QRS complexes during sinus rhythm are bundle branch block, intraventricular conduction defect and WPW syndrome. There is one more condition where wide QRS complexes arise from a ventricular pacemaker at a rate of 60 to 100 beats/min and is known as accelerated idioventricular rhythm (AIVR).

Let us see how this rhythm differs from sinus rhythm with wide QRS complexes.

ACCELERATED IDIOVENTRICULAR RHYTHM

Accelerated idioventricular rhythm (AIVR) is an ectopic rhythm originating from a latent subsidiary pacemaker located in the ventricular myocardium. Normally, such a pacemaker is subdued when the cardiac rhythm is governed by the S-A node.

However, when a ventricular pacemaker undergoes enhancement of its inherent automaticity, it produces an idioventricular rhythm. Since the heart rate during such rhythm exceeds the

inherent ventricular rate, it is known as accelerated idioventricular rhythm (AIVR).

AIVR produces a regular rhythm at a rate of 60 to 100 beats/min that is greater than the inherent rate of the ventricular pacemaker which is 20-40 beats/min. The QRS complexes are bizarre and wide because of ventricular origin of the rhythm (Fig. 20.1).

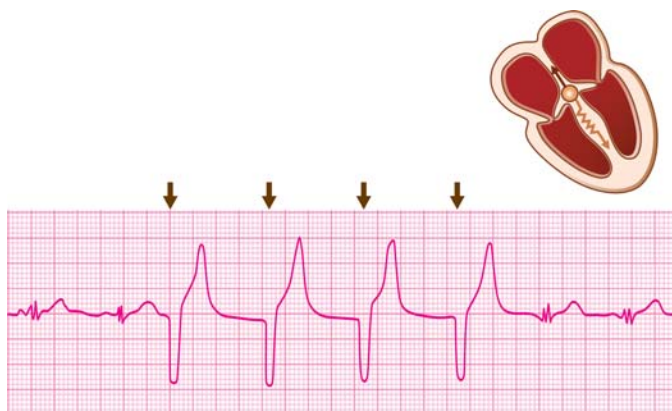


Fig. 20.1: Accelerated idioventricular rhythm (AIVR):
Slow rhythm; wide QRS complexes

The distinctive feature of AIVR is atrioventricular dissociation or lack of relationship between the P waves and the QRS complexes. This is because, while the ventricles are activated by the ventricular pacemaker, the atria continue to be activated by the S-A node.

AIVR can be differentiated from ventricular tachycardia only by the ventricular rate. The rate is 60 to 100 beats/min in AIVR and 150 to 200 beats/min in VT, although both rhythms originate from the ventricles.

Clinical Relevance of Regular Wide QRS Rhythm

Sinus Rhythm with Wide QRS Complexes

A normal sinus rhythm, when associated with a conduction abnormality in the ventricles, produces wide QRS complexes. The morphology of the QRS complex depends upon the cause of the conduction abnormality. Importantly, the 1:1 P-QRS relationship is maintained during sinus rhythm.

The significance of wide QRS complexes during sinus rhythm depends upon the cause of QRS widening. Causes of wide QRS complexes are:

- ❖ Complete bundle branch block
- ❖ Intraventricular conduction defect
- ❖ Ventricular pre-excitation syndrome.

Accelerated Idioventricular Rhythm

AIVR is most often observed in coronary care units in a setting of acute myocardial infarction. It either occurs spontaneously or as a reperfusion arrhythmia after thrombolytic therapy.

Other infrequent causes of AIVR are:

- ❖ Digitalis toxicity
- ❖ Rheumatic carditis
- ❖ Cardiac surgery.

The above causes of AIVR are quite akin to those of a junctional tachycardia or accelerated idiojunctional rhythm. Both are examples of an idiofocal tachycardia.

AIVR is most often picked up from the monitor screen of an intensive coronary care unit (ICCU). It needs to be differentiated from its more serious counterpart ventricular tachycardia that often produces hemodynamic embarrassment, carries a poor prognosis and requires aggressive management. AIVR differs from VT, only in terms of the ventricular rate.

AIVR also needs to be differentiated from bundle branch block of recent onset, which is not uncommon in an ICCU setting. While AIVR produces bizarre and wide QRS complexes unrelated to P waves, bundle branch block is associated with a triphasic QRS contour and a maintained P-QRS relationship.

AIVR is usually asymptomatic as it occurs at the same rate-range as sinus rhythm. It rarely causes serious hemodynamic embarrassment. Only the loss of atrial contribution to ventricular filling (A-V dissociation) causes slight fall in cardiac output.

AIVR is usually transient and does not herald the onset of serious ventricular arrhythmias. Therefore, it is considered to be a benign arrhythmia with an excellent prognosis.

Active treatment of AIVR is generally not required as it is transient, asymptomatic and has few hemodynamic consequences. The hallmark of management of AIVR is constant observation. If treatment is required, it is only in patients with poor left ventricular function.

Atropine can be administered to accelerate the sinus rate, overdrive the ventricular rhythm and eliminate atrioventricular dissociation. Antiarrhythmic drugs, DC cardioversion and artificial pacing are unnecessary in the management of accelerated idioventricular rhythm.

21

Fast Irregular Rhythm with Bizarre QRS

IRREGULAR WIDE QRS RHYTHM

A cardiac rhythm that exceeds a rate of 100 beats per minute indicates a rapid discharge of impulses from the pacemaker governing the rhythm of the heart.

If the QRS complexes during such a rhythm are wide, bizarre looking and occur irregularly, it indicates a grossly abnormal pattern of intraventricular conduction and that the pacemaker is located in the ventricular myocardium.

Let us examine the specific arrhythmias that are associated with these features.

VENTRICULAR FLUTTER

Ventricular flutter is a fast ventricular rhythm produced either due to rapid discharge of impulses from a ventricular pacemaker or repetitive circus movement of an impulse in a reentrant circuit. Therefore, ventricular flutter is quite akin to ventricular tachycardia in terms of its mechanism.

The heart rate in ventricular flutter is 250 to 350 beats per minute and is irregular. The QRS complexes are very wide and bizarre in morphology while the P waves and T waves are not discernible (**Fig. 21.1**).

In fact, merging of QRS complexes and T deflections produces a sine waveform. This is the differentiating feature from

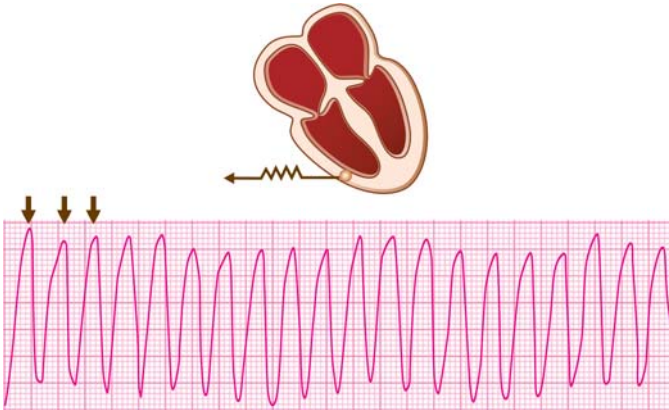


Fig. 21.1: Ventricular flutter: Undulating large waves; no QRS-T distinction

ventricular tachycardia where QRS complexes and T waves are identifiable separately.

The deflections in ventricular flutter although wide and bizarre, they are large, constant in morphology and occur with slight irregularity. On the other hand, the deflections in ventricular fibrillation are relatively small, grossly variable in shape, height and width occurring in a totally chaotic fashion.

VENTRICULAR FIBRILLATION

Ventricular fibrillation is a grossly irregular rapid ventricular rhythm produced by a series of incoordinated and chaotic ventricular depolarizations at a rate of more than 350 beats per minute.

Instead of the ventricles being activated systematically through the conduction system to produce coordinated pumping, the ventricular myocardium is functionally fractionated into numerous tissue islets in various stages of excitation and recovery.

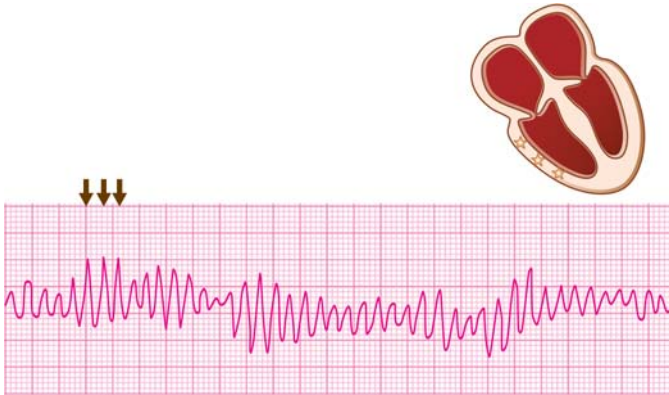

Fig. 21.2: Ventricular fibrillation: Irregular, bizarre and chaotic deflections

Ventricular depolarization is thus chaotic and ineffectual in producing hemodynamic pumping.

Ventricular fibrillation manifests with rapidly and irregularly occurring small deformed deflections that are grossly variable in shape, height and width. The regular waveforms of P waves, QRS complexes and T waves cannot be identified and the isoelectric line seems to waver unevenly (**Fig. 21.2**).

Ventricular fibrillation can be differentiated from ventricular flutter by the fact that in the latter condition, although the QRS complexes are bizarre and wide, they are relatively large, constant in morphology and occur only with slight irregularity.

Ventricular fibrillation needs to be differentiated from complete cardiac arrest or asystole in which no ECG deflections are recorded. This is possible by the fact that no matter how small, some definite deflections are always recorded in ventricular fibrillation.

Clinical Relevance of Fast Irregular Bizarre QRS Rhythm

Ventricular Flutter

Ventricular flutter is very similar to ventricular tachycardia in terms of mechanism and causation. In fact, even their ECG features closely resemble each other and at times they are indistinguishable.

Nevertheless, conversion of ventricular tachycardia to ventricular flutter is often associated with a precipitous fall in cardiac output and blood pressure.

Most often, ventricular flutter is a very transient arrhythmia as it frequently and rapidly degenerates into ventricular fibrillation. Therefore, ventricular flutter is most often picked up during cardiac monitoring in intensive care units.

Since ventricular flutter almost always converts to ventricular fibrillation, it is the treatment of the latter condition that is required.

Ventricular Fibrillation

Ventricular fibrillation is the most feared of all arrhythmias. It is often a terminal catastrophic event with an exceedingly poor prognosis and invariable progression to death if untreated. It is also the most common cause of sudden cardiac death.

Primary ventricular fibrillation occurs in a patient who does not have pre-existing hypotension or heart failure while secondary ventricular fibrillation occurs in those who have these abnormalities. Underlying advanced myocardial disease is invariable in those who develop secondary ventricular fibrillation.

Local cellular and metabolic factors that predispose to ventricular fibrillation are hypoxia, acidosis, hypoglycemia, hyperkalemia, catecholamine excess and accumulation of free fatty acids or lactates.

Frequent causes of ventricular fibrillation are:

- ❖ Myocardial infarction
 - Acute
 - Old
- ❖ Severe cardiomyopathy
 - Idiopathic
 - Ischemic
- ❖ Drug intoxication
 - Digitalis
 - Quinidine
- ❖ Metabolic derangement
 - Hypoxia
 - Acidosis
- ❖ Accidental event
 - Electrical shock
 - Hypothermia.

Arrhythmias that are potentially serious as they may degenerate into ventricular fibrillation are:

- ❖ Ventricular tachycardia at more than 180 beats/min
- ❖ Ventricular tachycardia with supervening ischemia
- ❖ Torsade de pointes due to prolonged Q-T interval
- ❖ VPCs demonstrating 'R-on-T' phenomenon
- ❖ Atrial fibrillation with an accessory pathway.

Differentiation between ventricular flutter and ventricular fibrillation is generally a futile exercise as flutter is transient and almost always degenerates into ventricular fibrillation.

Clinically, it may be difficult to differentiate between ventricular fibrillation and cardiac standstill or asystole as both conditions cause absence of peripheral pulses and heart sounds with loss of consciousness.

Nevertheless, their distinction is crucial, since defibrillation is required for ventricular fibrillation while external pacing is the mainstay of treatment for cardiac asystole.

The prognosis of ventricular fibrillation is exceedingly poor with invariable progress to death unless promptly treated. Prompt recognition and institution of defibrillation within a minute is the cornerstone of successful resuscitation.

Therefore, the prognosis of ventricular fibrillation is better for witnessed cardiac arrest in an intensive care unit or an operation theater with cardiac monitoring facility, than in the community.

Many victims of acute myocardial infarction can be salvaged by training paramedical personnel and even laymen in the technique of cardiopulmonary resuscitation (CPR).

Moreover, mortality from myocardial infarction has declined in recent years through availability of intensive coronary care units (ICCU) including mobile CCUs. These units are equipped with facilities for prompt recognition and cardioversion of serious ventricular arrhythmias such as ventricular fibrillation.

The moment ventricular fibrillation is recognized, the immediate goal should be to restore an effective cardiac rhythm. If defibrillation equipment is not available, a vigorous blow may be given to the precordium. This is popularly known as 'thump version' and may occasionally succeed in restoring sinus rhythm.

If not, CPR should be begun immediately. Cardiac massage is done at a rate of 100 compresses per minute. After every 30 compresses, 2 artificial breaths are delivered to complete 5 such cycles in 2 minutes. The patient should be shifted to a hospital with intensive care and defibrillation facility, in the minimum possible time.

The likelihood of success of defibrillation declines rapidly with time and irreversible brain damage occurs within four minutes of circulatory collapse.

Electrical defibrillation with 200 to 360 Joules of DC shock is the procedure of choice for the treatment of ventricular fibrillation.

Longer the duration of fibrillation, higher is the energy level of shock required.

If one attempt fails, defibrillation may be repeated after intravenous bicarbonate 1 mEq/kg to correct the underlying acidosis, which increases the success rate of cardioversion.

If repeated attempts at defibrillation fail, intravenous drugs should be given 30-60 sec after each attempt. The dose of antiarrhythmic drugs that can be given is amiodarone 300 mg or lidocaine 1.0-1.5 mg/kg.

Recurrence of ventricular fibrillation can be prevented by antiarrhythmic drugs used for prevention of ventricular tachycardia. Drugs that are used include flecainide, phenytoin, propafenone and sotalol.

Implantable defibrillators are now available, which when given to an ambulatory patient, can automatically sense ventricular fibrillation and deliver an electrical shock. The device is known as Automatic Implantable Cardioverter Defibrillator or AICD.

22

Slow Regular Rhythm with Narrow QRS

REGULAR SLOW RHYTHM

A regular cardiac rhythm that occurs at a rate of less than 60 beats per minute indicates two broad possibilities:

- ❖ Slow discharge of impulses from the pacemaker governing the rhythm of the heart.
- ❖ Block of alternate beats so that the conducted beats appear to occur at a slow rate.

If the discharge rate of impulses is slow, the focus of impulse origin is:

- ❖ Sinoatrial (S-A) node
- ❖ Junctional pacemaker.

If alternate beats are blocked, the block is:

- ❖ Sinoatrial (S-A) block
- ❖ Atrioventricular (A-V) block
- ❖ Blocked atrial ectopic beats.

Narrow QRS complexes during such a rhythm indicate normal intraventricular conduction of impulses from a supraventricular pacemaker.

Let us examine the specific arrhythmias that are associated with these features.

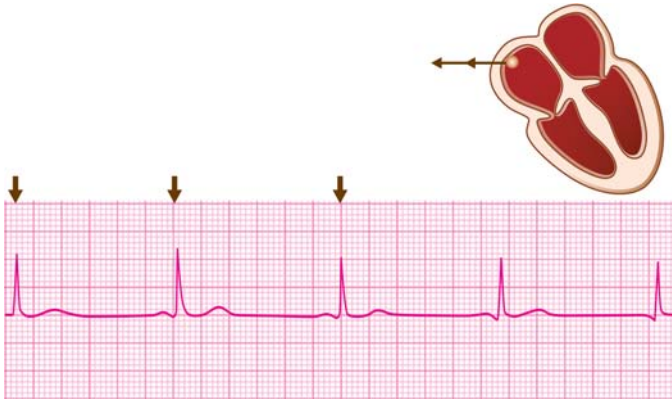


Fig. 22.1: Sinus bradycardia: Heart rate less than 60/min (R-R > 25 mm)

SINUS BRADYCARDIA

The occurrence of sinus node discharge at a rate of less than 60 beats/min constitutes sinus bradycardia (**Fig. 22.1**).

In other words, the R-R interval exceeds 25 mm (heart rate = $1500 / >25 = < 60$). The rhythm is regular and the P wave and QRS morphology as well as P-QRS relationship are obviously as in normal sinus rhythm.

In case of hypothermia, there is wavering of the isoelectric line due to muscle twitching with shivering (**Fig. 22.2**). The small hump at the end of the QRS complex or the beginning of the S-T segment, is known as the J wave or the Osborne wave. Another cause of the J wave or Osborne wave is the early repolarization variant.

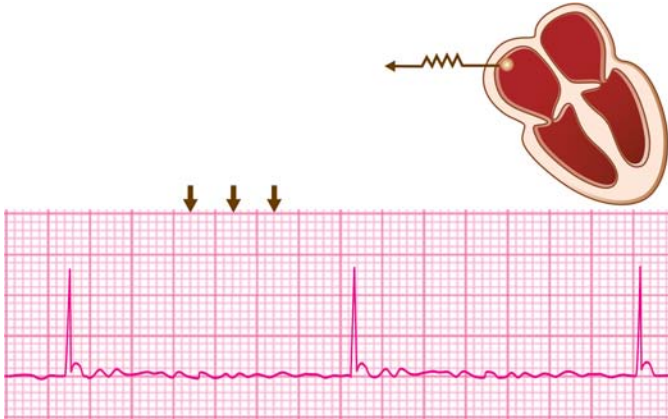


Fig. 22.2: Hypothermia: Bradycardia, shivering, Osborne wave

JUNCTIONAL ESCAPE RHYTHM

Junctional rhythm originates from a latent subsidiary pacemaker located in the A-V junction. Normally, this pacemaker is subdued, when the cardiac rhythm is governed by the S-A node. However, if the S-A node is at fault (sinus pause or sinus arrest), this junctional pacemaker takes charge of the cardiac rhythm.

Junctional rhythm is an example of escape rhythm since the junctional pacemaker escapes the subduing influence of the S-A node on the expression of its automaticity.

A junctional rhythm occurs at a rate of 40 to 60 beats/min which is the inherent rate of the junctional pacemaker (**Fig. 22.3**).

The distinctive feature of a junctional rhythm is the typical relationship between P waves and QRS complexes. As the atria are activated retrogradely, the P waves are inverted. They may just precede, just follow or be buried in the QRS complexes because of nearly simultaneous atrial and ventricular activation.

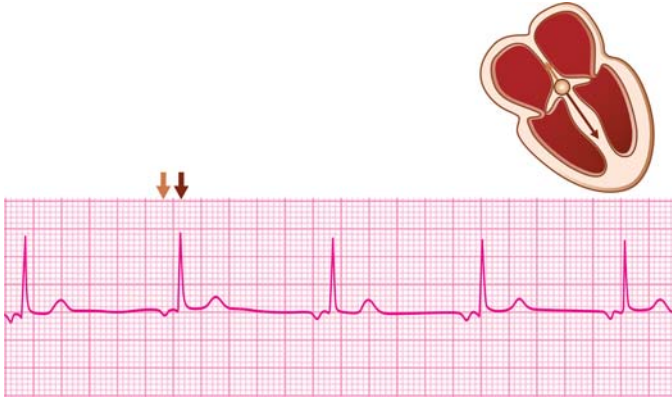

Fig. 22.3: Junctional rhythm: Inverted P-waves precede the QRS complexes

These characteristics of a junctional rhythm help to differentiate it from sinus bradycardia where the P waves are upright and always precede the QRS complexes by a fixed P-R interval.

SINUS RHYTHM WITH 2:1 S-A BLOCK

In second-degree sinoatrial block (2° S-A block), there is intermittent dropping of beats, resulting in pauses. In a dropped beat, the entire P-QRS-T complex is missing as neither atrial nor ventricular activation occurs.

If the pattern of dropped beats is such that an alternate beat is missing (2:1 S-A block), the conducted beats resemble a slow regular rhythm such as sinus bradycardia.

The only difference is that if atropine is administered in 2:1 S-A block, there is a sudden doubling of the heart rate while in sinus bradycardia the heart rate accelerates gradually.

SINUS RHYTHM WITH 2:1 A-V BLOCK

In second-degree atrioventricular block (2° A-V block), there is intermittent dropping of ventricular complexes, resulting in pauses. In a dropped beat, the P-wave is not followed by a QRS complex as atrial activation is not followed by ventricular activation.

If the pattern of dropped beats is such that an alternate QRS complex is missing (2:1 A-V block), the normally conducted beats resemble a slow regular rhythm such as sinus bradycardia or 2:1 S-A block.

A 2:1 A-V block can be differentiated from 2:1 S-A block by the fact that P waves are recorded normally and only the QRS complexes are missing in alternate beats.

BLOCKED ATRIAL ECTOPICS IN BIGEMINY

An atrial premature complex (APC) inscribes a premature P-wave followed by a normal QRS complex and then a compensatory pause before the next sinus beat is recorded.

A very premature APC may find the A-V node still refractory to ventricular conduction and may consequently get blocked. Such an APC inscribes a P-wave that deforms the T-wave of the preceding beat, is not followed by a QRS complex but followed by a compensatory pause.

If such blocked APCs alternate with normal beats, the normal sinus beats resemble a slow regular rhythm such as sinus bradycardia or 2:1 S-A block.

The distinctive feature of blocked atrial ectopics in bigeminal rhythm is the occurrence of premature bizarre P-waves deforming the T-waves.

A 2:1 A-V block also produces blocked P-waves but they are not premature and are normal in morphology.

Clinical Relevance of Slow Regular Narrow QRS Rhythm

Sinus Bradycardia

Sinus bradycardia represents response of the S-A node to a variety of physiological and pathological stimuli mediated by the nervous and hormonal control over the rate of pacemaker discharge.

The causes of sinus bradycardia are:

- ❖ Advanced age and athletic built
- ❖ Deep sleep and hypothermia
- ❖ Intracranial tension and glaucoma
- ❖ Hypopituitarism and hypothyroidism
- ❖ Obstructive jaundice and uremia
- ❖ Beta blockers and amiodarone
- ❖ Sick sinus syndrome
- ❖ Vasovagal syncope.

Sinus bradycardia is usually observed in young healthy persons, conditioned athletes and marathon runners who have parasympathetic dominance. It is also seen in elderly patients with sinus node dysfunction.

Sinus bradycardia during strenuous activity and in the absence of medical conditions or drugs likely to cause a slow heart rate is a sign of sinus-node dysfunction, the so called "sick sinus syndrome".

Sinus bradycardia is not a primary arrhythmia and therefore, treatment should be directed towards the basic underlying condition. Examples are hormone replacement in endocrinal disorders, decongestive therapy in high intracranial/intraocular tension, medical treatment of hepatic/renal disease and withdrawal of the offending drug in drug-induced sinus bradycardia.

Symptomatic sinus bradycardia in the absence of these conditions should be managed as sick sinus syndrome. Atropine and sympathomimetic drugs can temporarily accelerate the ventricular rate.

212 ECG Made Easy

Junctional Rhythm

A junctional escape rhythm is a 'rescue' rhythm in which the junctional pacemaker is asked to govern the rhythm of the heart when the sinus node produces insufficient impulses due to severe bradycardia or S-A block.

The term 'escape' rhythm signifies that the junctional pacemaker has escaped the subduing influence of the dominant pacemaker, the S-A node. A junctional bradycardia after sinus arrest is the body's defence mechanism against prolonged asystole.

The causes of junctional bradycardia are:

- ❖ Normal in athletes
- ❖ Sinus node dysfunction
- ❖ Drug therapy
 - digoxin
 - amiodarone
 - diltiazem
 - beta-blockers.

Sinus Rhythm with 2:1 Block

A sinus rhythm in which alternate beats are blocked (2:1 block) closely resembles sinus bradycardia as the conducted beats appear to occur at a slow rate. The block may be either sinoatrial (S-A block) or atrioventricular (A-V block).

Sick sinus syndrome is a frequent cause of 2:1 S-A block next only to drugs that reduce the pacemaker discharge rate (e.g. propranolol, diltiazem).

The causes of 2:1 A-V block are acute carditis, drugs that cause 2:1 S-A block (see above) and inferior wall myocardial infarction.

In the management of symptomatic 2:1 block, drugs like atropine and adrenaline can temporarily accelerate the ventricular rate.

Temporary cardiac pacing is effective in tiding over the crisis in acute carditis, drug toxicity or myocardial infarction.

Permanent cardiac pacing is the answer to the management of sick sinus syndrome when symptoms are severe, recurrent and long-standing.

Blocked APCs in Bigeminal Rhythm

Atrial premature complexes that are blocked in the A-V node and alternate with sinus beats, resemble a slow rhythm. This occurs because of the compensatory pause that follows each premature beat.

Such a rhythm needs to be differentiated from other slow rhythms, the management of which is entirely different.

Blocked or non-conducted atrial premature beats are frequently observed in elderly patients who have advanced A-V nodal disease and in the presence of digitalis toxicity.

23

Slow Irregular Rhythm with Narrow QRS

IRREGULAR SLOW RHYTHM

An irregular cardiac rhythm that occurs at a rate of less than 60 beats per minute indicates three possibilities:

- ❖ Slow and variable rate of pacemaker discharge.
- ❖ Beat-to-beat variability of the focus of origin.
- ❖ Varying degree of conduction block of regular beats.

Narrow QRS complexes during such a rhythm indicate normal intraventricular conduction of impulses from a supraventricular pacemaker.

Let us examine the specific arrhythmias that are associated with these features.

SINUS ARRHYTHMIA

Sinus arrhythmia is an irregular rhythm characterized by periods of slow and fast heart rate due to variation in the rate of SA node discharge.

When the periodic change in sinus rate is related to the phases of respiration, it is known as respiratory sinus arrhythmia. Non-respiratory sinus arrhythmia is where the sinus rate variability is uninfluenced by the respiratory cycle.

Sinus arrhythmia is characterized by alternating periods of long and short P-P and R-R intervals reflecting a variable heart rate (**Fig. 23.1**).

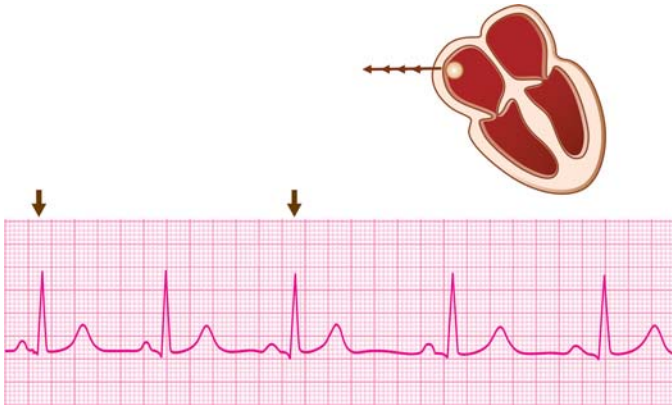


Fig. 23.1: Sinus arrhythmia: Heart rate varies with respiration

In respiratory sinus arrhythmia, about four complexes occur at one rate while the next four complexes occur at a different rate. The figure of 4 presumes that the respiratory rate is one-fourth of the heart rate. The rate is faster in inspiration and slower in expiration.

In non-respiratory sinus arrhythmia, the variability of heart rate is non-phasic and unrelated to respiration.

Since, all beats arise from the S-A node, the P-wave shape, QRS complex morphology and P-R interval are constant. Sinus arrhythmia is frequently associated with sinus bradycardia.

WANDERING PACEMAKER RHYTHM

Wandering pacemaker is a rhythm wherein, impulses take origin from different foci besides the S-A node. The pacemaker, so to say, wanders from one focus to the other, from beat-to-beat. The focus of origin may be the S-A node, the atrial myocardium or the A-V junction.

Wandering pacemaker rhythm is characterized by a beat-to-beat variability of the P-wave morphology (**Fig. 23.2**).

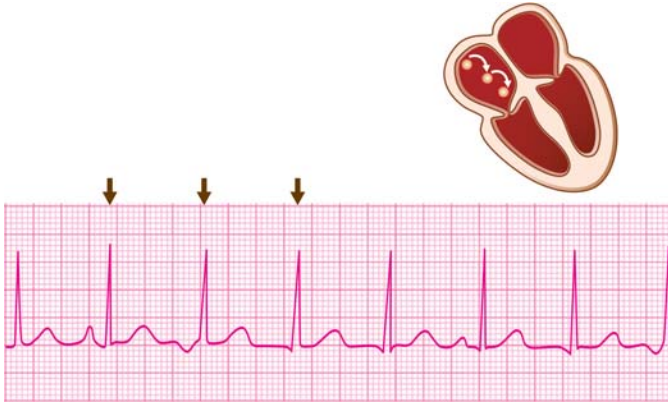


Fig. 23.2: Wandering pacemaker rhythm: Variable P-wave; changing P-R interval

Upright P-waves arise from the SA node or upper atrium while inverted P waves arise from the lower atrium or A-V junction.

The P-R interval also varies from beat-to-beat due to variability of the A-V conduction time. Lower atrial or junctional beats have a shorter P-R interval because of shorter conduction time.

Multifocal atrial tachycardia (MAT) is also characterized by variability of P-wave morphology but the heart rate is 100-150 beats per minute. In wandering pacemaker rhythm, the heart rate ranges from 60 to 100 beats/min.

Wandering pacemaker rhythm can be differentiated from sinus arrhythmia by the fact that the variability of heart rate is not phasic but on a beat-to-beat basis. Moreover, in sinus arrhythmia, the P-wave morphology and P-R interval are constant, since all beats arise from the S-A node.

SINUS RHYTHM WITH VARYING S-A BLOCK

In second-degree sinoatrial block (2° S-A block), there is intermittent dropping of beats, resulting in pauses. In a dropped

beat, the entire P-QRS-T complex is missing as neither atrial nor ventricular activation occurs.

The pattern of dropped beats determines the conduction ratio such as 2:1 S-A block if alternate beats are dropped, 3:2 if every third beat is dropped and so on. If the conduction ratio is variable, it produces a slow irregular rhythm.

SINUS RHYTHM WITH VARYING A-V BLOCK

In second-degree atrioventricular block (2° A-V block), there is intermittent dropping of ventricular complexes, resulting in pauses. In a dropped beat, the P-wave is not followed by a QRS complex as atrial activation is not followed by ventricular activation.

The ratio of the number of P waves to number of QRS complexes determines the conduction sequence such as 2:1 A-V block if alternate P-wave is blocked, 3:2 if every third P-wave is blocked and so on. If the conduction ratio is variable, it produces a slow irregular rhythm.

Varying A-V block can be differentiated from varying S-A block by the fact that P waves are recorded normally in A-V block. They are altogether missing along with the QRS complexes, in case of S-A block.

Clinical Relevance of Slow Irregular Narrow QRS Rhythm

Sinus Arrhythmia

Respiratory sinus arrhythmia is produced by variation in the vagal tone in relation to the respiratory cycle, caused by reflex mechanisms in the pulmonary and systemic vasculature. It is a normal physiological phenomenon often observed in children and young athletic individuals.

Non-respiratory sinus arrhythmia is an irregularity of heart rate produced by a dysfunctional S-A node in elderly patients, the so called sick sinus syndrome.

218 ECG Made Easy

Since sinus arrhythmia results from variation in the vagal influence on the S-A node, it is accentuated by vagotonic procedures like carotid sinus massage and abolished by vagolytic procedures such as exercise and atropine administration.

Absence of sinus arrhythmia with a clock-like regularity of the heart rate indicates absence of vagal influence on the S-A node and is a feature of cardiac autonomic neuropathy.

Lack of heart rate variability with a resting tachycardia is a feature of sympathetic dominance and carries high mortality in diabetic autonomic neuropathy.

It is also absent in atrial septal defect because of equalized left and right atrial pressures, with no effect of respiration on the vagal tone.

Respiratory sinus arrhythmia in children and young adults merits no active treatment. Non-respiratory sinus arrhythmia in the elderly is managed as sick sinus syndrome.

Wandering Pacemaker Rhythm

A cardiac rhythm due to a wandering pacemaker is a striking but benign electrocardiographic abnormality. It is often observed in young, asymptomatic and healthy individuals.

Occasionally, wandering pacemaker rhythm is observed during the course of digitalis treatment or acute rheumatic fever.

No active treatment is indicated in young asymptomatic persons in whom a wandering pacemaker rhythm is observed incidentally.

Management of digitalis toxicity or rheumatic carditis is indicated if these causes are implicated. Symptomatic bradycardia due to this rhythm is managed with atropine or sympathomimetics.

Sinus Rhythm with Varying Block

A sinus rhythm, when complicated by sinoatrial or atrioventricular block of a variable degree, produces an irregular heart rate.

Sick sinus syndrome is a frequent cause of varying S-A block. Variable A-V block is often due to rheumatic carditis or acute inferior wall infarction.

Slow Atrial Fibrillation

Atrial fibrillation generally produces a fast irregular ventricular rhythm. This is because, out of the large number of fibrillatory waves, only a few can randomly penetrate the A-V node and activate the ventricles producing a ventricular rate of 100 to 150 beats per minute.

In other words, atrial fibrillation is associated with a variable degree of physiological A-V block. If this physiological A-V block is advanced, the ventricular rate is slow, resulting in slow atrial fibrillation.

Slow atrial fibrillation is observed, if there is pre-existing A-V nodal disease or during treatment with drugs like propranolol, verapamil or diltiazem that block the AV node.

Atropine and sympathomimetic agents can temporarily accelerate the ventricular rate in symptomatic S-A or A-V block.

Temporary pacing is useful in the acute phase of carditis, drug intoxication or myocardial infarction. Permanent cardiac pacing is the answer to recurrent and severe symptoms due to sick sinus syndrome.

24

Slow Regular Rhythm with Wide QRS

SLOW WIDE QRS RHYTHM

A regular cardiac rhythm that occurs at a rate of less than 60 beats per minute indicates slow discharge of impulses from the pacemaker governing the rhythm of the heart.

If the QRS complexes during such a rhythm are wide, two possibilities have to be considered:

- ❖ The rhythm is ventricular in origin in which case ventricular activation is through myocardium and not the specialized conduction system.
- ❖ The rhythm is supraventricular in origin but there is a pre-existing abnormality causing wide QRS complexes.

A slow ventricular rhythm occurs in these situations:

- ❖ Complete A-V block with an idioventricular rhythm
- ❖ Complete S-A block with ventricular escape rhythm
- ❖ Ventricular rhythm from an external pacemaker.

Let us go into the classical features of these rhythms.

COMPLETE A-V BLOCK

In complete or third-degree atrioventricular block (3° A-V block), there is a total interruption of A-V conduction with the result that no sinus beat is able to activate the ventricles.

Therefore, the ventricles are governed by a subsidiary pacemaker in the ventricular myocardium. The inherent rate of

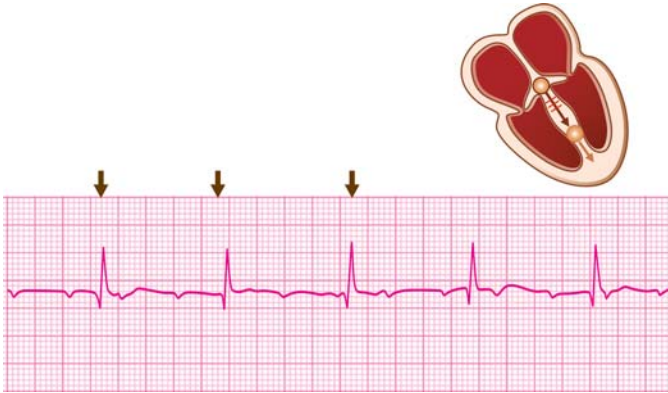


Fig. 24.1: Third-degree (complete) AV block: Wide QRS complexes

this pacemaker is 20 to 40 beats per minute and hence, the wide QRS complexes occur at this rate (**Fig. 24.1**).

However, since the atria continue to be activated by the S-A node, the P waves occur at a rate of 70 to 80 beats per minute. Since, the S-A node and the ventricular pacemaker are asynchronous and produce independent rhythms, there is no relationship between the P waves and QRS complexes. This is known as A-V dissociation.

The ventricular rhythm at its inherent rate of 20 to 40 beats per minute is called idioventricular rhythm.

Occasionally in complete A-V block, the ventricles are governed by a subsidiary pacemaker in the His bundle. The inherent rate of this pacemaker is 40 to 60 beats per minute and hence, the QRS complexes occur at this rate.

Moreover, since ventricular conduction proceeds through normal pathway, the QRS complexes are narrow (**Fig. 24.2**).

A His bundle rhythm closely resembles a junctional rhythm as both occur at the same rate and produce narrow QRS complexes.

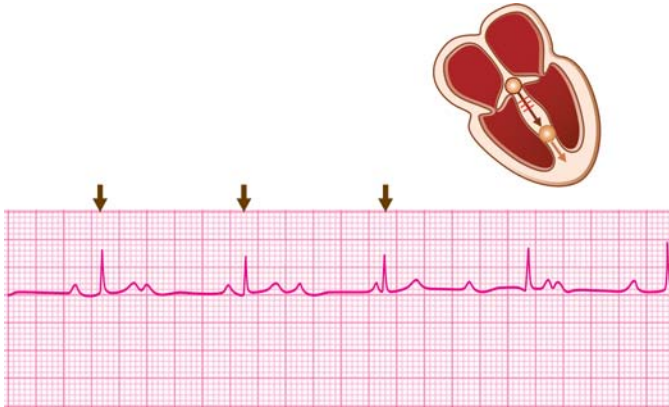


Fig. 24.2: Third-degree (complete) AV block: Narrow QRS complexes

The differentiating feature is that in His bundle rhythm of complete A-V block, the QRS complexes are unrelated to the P waves. In a junctional rhythm, the P waves just precede, just follow or are merged with the QRS complexes.

COMPLETE S-A BLOCK

In complete or third-degree sinoatrial block (3° S-A block), there is sinus node arrest or total atrial standstill with the result that ventricular activation is not possible.

Therefore, a subsidiary pacemaker comes to rescue by taking over the rhythm of the heart. Generally, it is the junctional pacemaker which governs the cardiac rhythm in this situation, known as junctional escape (**Fig. 24.3**).

However, if the A-V node is diseased, a ventricular pacemaker is called upon to govern the heart, producing a ventricular rhythm. The inherent rate of this pacemaker is 20 to 40 beats per minute and wide QRS complexes occur at this rate.

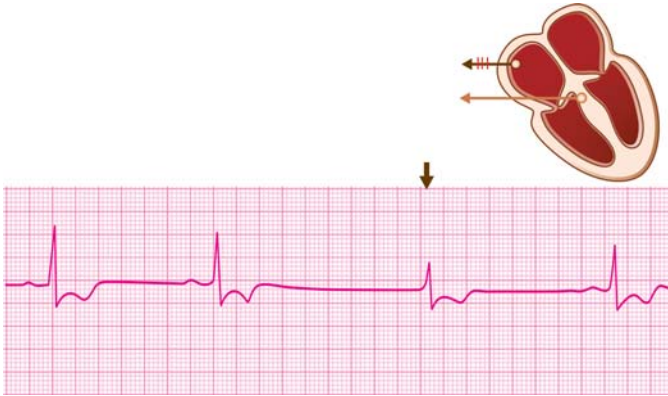

Fig. 24.3: Sinoatrial block followed by junctional escape

Since the ventricular pacemaker escapes the subduing influence of the S-A node on the expression of its automaticity, the rhythm is known as ventricular escape rhythm.

A ventricular escape rhythm in complete S-A block resembles the idioventricular rhythm in complete A-V block as both occur at a similar rate and produce wide QRS complexes.

They can be differentiated by the fact that normal P-waves at a rate of 70 to 80 beats continue to occur in A-V block. No signs of atrial activation are observed in S-A block and therefore P-waves are altogether absent.

EXTERNAL PACEMAKER RHYTHM

In complete S-A block or A-V block with a very slow heart rate, the definitive form of treatment is implanting an external pacemaker. Artificial pacing is generally done from the right ventricle. The pacemaker is programmed to deliver impulses at a predetermined rate of around 60 beats per minute.

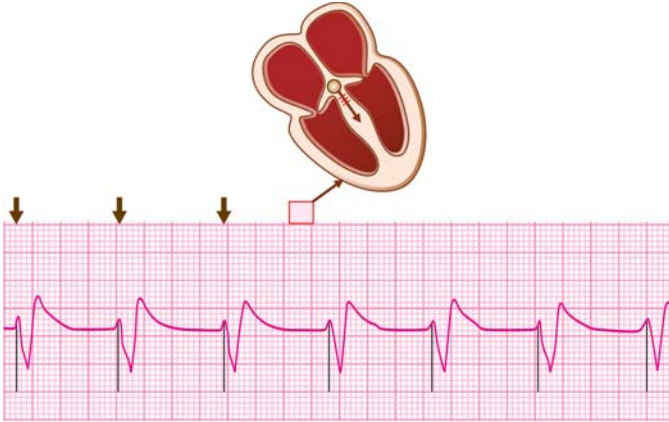


Fig. 24.4: External pacemaker rhythm: Spike before each QRS

These impulses are generated either continuously (fixed mode pacing) or intermittently (demand mode pacing) that is, only when the pacemaker senses an insufficient number of intrinsic impulses.

In either case, the pacemaker beats produce wide QRS complexes as the ventricles are activated asynchronously, right ventricular activation preceding the left. The heart rate depends upon the rate to which the pacemaker has been programmed.

The rhythm from an external pacemaker resembles an idioventricular rhythm of complete A-V block. The differentiating feature is a spike-like deflection before each “captured” cardiac response, known as pacemaker artefact (**Fig. 24.4**).

SLOW RHYTHM WITH EXISTING WIDE QRS

It is known that certain conditions produce an abnormality of ventricular conduction even in sinus rhythm causing an alteration of QRS morphology.

Three well known examples are:

- ❖ Bundle branch block (complete)
- ❖ WPW syndrome (pre-excitation)
- ❖ Intraventricular conduction defect.

If a slow supraventricular rhythm such as sinus bradycardia occurs in the presence of a pre-existing QRS abnormality, it is naturally associated with wide QRS complexes.

A bundle branch block produces a triphasic QRS contour while an intraventricular conduction defect results in a bizarre QRS morphology. The WPW syndrome is characterized by a delta wave on the ascending limb of the QRS complex.

Clinical Relevance of Slow Regular Wide QRS Rhythm

Complete A-V Block

The causes of complete or third-degree AV block are:

- ❖ Congenital heart disease, e.g. septal defect
- ❖ Coronary disease, e.g. anteroseptal infarction
- ❖ Cardiac surgery, e.g. atrial septal repair
- ❖ Aortic valve disease, e.g. calcific stenosis
- ❖ Fibrocalcerous degeneration, e.g. Lev's disease.

In complete A-V block, the ventricles are governed by a subsidiary pacemaker in the His bundle or the ventricular myocardium. While a His bundle rhythm produces narrow QRS complexes at 40 to 60 beats/min, a ventricular rhythm produces wide QRS complexes at 20 to 40 beats/min.

A His bundle rhythm is more stable, reliable to sustain ventricular function, can be accelerated by atropine and rarely causes symptoms. On the other hand, a ventricular rhythm is unstable, unreliable to sustain ventricular function, cannot be accelerated by atropine and often causes syncope.

226 ECG Made Easy

Clinical importance of A-V block depends upon:

- ❖ Causes of the A-V block: reversible or irreversible
- ❖ Site of the lower pacemaker: His bundle or ventricle
- ❖ Symptomatology of the patient: present or absent.

The most common symptom of complete A-V block is spells of dizziness or fainting due to transient ventricular asystole with sudden decline in cardiac output. Such episodes or syncopal attacks are known as Stokes-Adams attacks.

Other causes of Stokes-Adams attacks are:

- ❖ Complete sinoatrial block
- ❖ Serious ventricular arrhythmia
- ❖ Carotid sinus hypersensitivity
- ❖ Subclavian steal syndrome.

It is extremely important to differentiate Stokes-Adams attack due to complete A-V block from that due to a ventricular arrhythmia as their management is entirely different. While asystole requires atropine or cardiac pacing, ventricular arrhythmia requires antiarrhythmic drugs or electrical cardioversion.

Complete A-V block produces the following clinical signs that help to differentiate it from other slow rhythms:

- ❖ Dissociation of jugular venous waves from carotid arterial pulsations, due to A-V dissociation.
- ❖ Variable intensity of the first heart sound, due to variable duration of diastolic filling period.

Cardiac pacing is the definitive form of treatment in complete A-V block. While temporary pacing may be enough to tide over a transient situation such as an acute myocardial infarction or a postoperative complication, permanent pacing is the answer to a chronic condition like calcific degeneration of the A-V node.

Pacing is invariably required in these situations:

- ❖ Wide QRS rhythm at less than 40 beats/min
- ❖ History of recurrent Stokes-Adams attacks
- ❖ Setting of an acute myocardial infarction.

Complete S-A Block

The causes of complete or third-degree S-A block are:

- ❖ Drug therapy, e.g. propranolol, digitalis, diltiazem
- ❖ Vagal stimulation, e.g. by carotid sinus pressure
- ❖ Sinus node dysfunction, e.g. sick sinus syndrome.

In complete S-A block, the ventricles are governed by a subsidiary pacemaker in the A-V junction or the ventricular myocardium. While a junctional rhythm produces narrow QRS complexes at 40 to 60 beats/min, a ventricular rhythm produces wide QRS complexes at 20 to 40 beats/min.

Both these rhythms are examples of an escape rhythm, since the subsidiary pacemaker escapes the subduing influence of the S-A node on the expression of its automaticity. A ventricular escape rhythm occurs only if the A-V node is diseased and cannot govern the cardiac rhythm.

Sinoatrial block may co-exist with atrioventricular block and even right or left bundle branch block especially in elderly individuals with a diffuse fibrocalcerous or degenerative process involving the entire conduction system.

The escape rhythm in complete S-A block is a “rescue” rhythm in the absence of which prolonged asystole would invariably result in death.

The most common symptom of complete S-A block is spells of dizziness or fainting due to transient ventricular asystole along with sudden decline in cardiac output. S-A block is one of the causes of Stokes-Adams attacks.

228 ECG Made Easy

Treatment of symptomatic individuals involves administration of drugs like atropine and sympathomimetic drugs to accelerate the heart rate. The dosages of these drugs used are:

Atropine 0.6 mg IV; repeat every 3-5 min upto response or a total dose of 0.03-0.04 mg/kg

OR

Epinephrine 1 mg IV (10 ml of 1:10,000 solution)

Cardiac pacing remains the definitive form of treatment of complete S-A block. When the S-A block is a part of sick sinus syndrome, the management of that condition is indicated.

External Pacemaker Rhythm

The artificial pacemaker is an electronic device that can generate impulses to activate the heart, if the intrinsic rhythm is slow or unstable. Generally, the pacemaker lead with the electrode at its tip is implanted on the endocardial surface of the right ventricle.

External pacing may be employed temporarily to tide over an acute transient situation or permanently in a chronic condition.

There are two modes of cardiac pacing namely, fixed-mode pacing and demand-mode pacing.

In fixed-mode pacing, impulses are generated at a predetermined rate, irrespective of the intrinsic rhythm. In demand-mode pacing, the pacemaker generates impulses intermittently on demand, when it senses a slow intrinsic rhythm.

When an external pacemaker governs the cardiac rhythm, the ventricles are not activated synchronously but sequentially. The right ventricle is activated before the left since the pacing electrode is located in the right ventricle.

Therefore, an artificial pacemaker rhythm is characterized by wide QRS complexes. The rate of the pacemaker rhythm is the rate at which the pacemaker has been programmed.

Slow Rhythm with Existing Wide QRS

The occurrence of a slow rhythm in a patient who has a pre-existing condition causing wide QRS complexes such as bundle branch block or conduction defect, understandably simulates an idioventricular rhythm.

The availability of a previous ECG during normal sinus rhythm that reveals wide QRS complexes can settle the issue.

Moreover, the triphasic contour of a bundle branch block or the delta wave of WPW syndrome are too characteristic to be mistaken for the wide QRS complexes of a ventricular rhythm.

INDEX

Page numbers followed by *f* refer to figure and *t* refer to table

A

Abnormalities of

P-R

- interval 118
- segment 103

QRS

- axis 38
- complex 59

Q-T interval 124

S-T segment 105

Accelerated

- idioventricular rhythm 196*f*, 197
- junctional rhythm 170*f*

Acidosis 203

Acute

- alcoholic intoxication 180
- inferior myocardial infarction 98*f*, 110*f*
- myocardial infarction 112*f*
- insult 190
- myocarditis 81, 126, 161
- non-Q anterior wall myocardial infarction 92*f*, 109*f*
- pericarditis 104, 112, 115*f*
- pulmonary embolism 81, 83, 95
- respiratory failure 166
- rheumatic fever or diphtheria 119

Adipose tissue in obesity 61

Adrenergic drugs 161

Air in pulmonary emphysema 61

Alcohol intoxication 179

Alternate

- atrial premature beats 152
- ventricular premature beats 152

Alternating fast and slow rhythms 150

Amiodarone 78, 84*f*

Anemia 160

Aneurysm of left ventricular apex 64

Anterolateral infarction 64

Anteroseptal ischemia/infarction 95

Antiarrhythmic drugs 78, 126, 181

Aortic

- regurgitation 76
- stenosis 76
- valve disease 81, 225

Arrhythmogenic right ventricular dysplasia 83, 140

Atrial

- enlargement 104
- fibrillation 49, 53, 83, 84, 176, 177*f*, 179
- flutter 53, 158*f*, 166
- and atrial fibrillation 179*t*
- and atrial tachycardia 158*t*

232 ECG Made Easy

- infarction 104
 - muscle 5
 - premature
 - beats 129, 130*f*
 - complex 129, 210
 - rhythm 46, 47
 - septal defect 81
 - tachycardia 46, 161, 172
 - Atrioventricular dissociation 51*f*
 - Atropine resistant
 - bradyarrhythmias 150
 - Attenuation phenomenon 114
 - Augmented limb leads 16, 18
 - A-V re-entrant tachycardia 155*f*
- B**
- Beta blockers and amiodarone 211
 - Biatrial chamber 6
 - Biventricular chamber 6
 - Bradyarrhythmias 127
 - Bradycardia 42
 - Brady-tachy syndrome 150
 - Brugada syndrome 82
 - Bundle
 - branch block 78, 79, 88, 94, 106, 112, 189, 225
 - of His 8
 - of Kent 121
 - By-pass tract 54
- C**
- Calcification from aortic valve 65
 - Calculation of heart rate from R-R interval 41*f*
 - Cardiac
 - pacing 39
 - surgery 136, 161, 166, 172, 197, 225
 - trauma 81, 190
 - Cardiomyopathy 81, 138
 - Carotid sinus hypersensitivity 226
 - Causes of secondary
 - S-T depression 112*f*
 - T wave inversion 94*f*
 - Cerebrovascular accident 106
 - Chest wall trauma 104
 - Chronic
 - coronary insufficiency 65
 - dilated cardiomyopathy 65
 - lung disease 38, 64, 67
 - obstructive pulmonary disease 83
 - pulmonary disease 72, 81, 83
 - Coarctation of aorta 76
 - Complete
 - A-V block 220, 225
 - bundle branch block 197
 - sinoatrial block 226
 - Congenital
 - heart disease 39, 72, 179, 225
 - Q-T syndromes 126
 - Congestive heart failure 138
 - Constrictive pericarditis 60, 179
 - Coronary
 - artery disease 111, 119, 179
 - disease 126, 225
 - insufficiency 93*f*
 - Couplet of ventricular ectopic beats 136*f*
- D**
- Deep sleep and hypothermia 211
 - Determination of
 - electrical axis 33
 - heart rate 40
 - QRS axis 36
 - Determining heart rate from R-R interval 43*f*

- Diffuse
 - myocardial disease 60, 67
 - myocarditis 62
 - Digitalis toxicity 136, 161, 172, 197
 - Dilated cardiomyopathy 140
 - Diltiazem 151
 - Diphtheria 150
 - Direction of myocardial activation
 - in atrium and ventricle 5*f*
 - Dressler's syndrome 112
 - Drug intoxication 190
 - Duchenne muscular dystrophy 71
- E**
- Einthoven triangle 21
 - Electrical
 - axis 33
 - cardioversion 193
 - defibrillation 183
 - shock 203
 - wiring network of heart 8*f*
 - Electrocardiogram 1
 - Electrocardiographic leads 15
 - Electrolyte
 - deficiency 126
 - imbalance 78, 179
 - Excessive beta-blocker sensitivity 150
 - External
 - cardiac pacing 64
 - pacemaker rhythm 223, 224*f*, 228
 - Extra-cardiac disorders 88
 - Extrasystolic
 - atrial bigeminy 152
 - ventricular
 - bigeminy 135*f*, 152
 - trigeminy 135*f*
 - Extreme right axis deviation 39
- F**
- Fallot's tetralogy 72
 - Fast irregular rhythm with
 - bizarre QRS 199
 - narrow QRS 174
 - Fast regular rhythm with
 - narrow QRS 153
 - wide QRS 184
 - Fever and volume depletion 160
 - Fibrocalcerous
 - degeneration 65, 225
 - disease 81
 - Fluid in pericardial effusion 61
- H**
- Hammock-like S-T segment 109
 - Heart
 - rate 40, 44, 61
 - rhythm 43
 - sounds 181, 191
 - Hemorrhage 160
 - Hexaxial system 33
 - from unipolar and limb leads 22, 34
 - Hibernating myocardium 114
 - Hyperacute infarction 96
 - Hypercapnia 179
 - Hyperkalemia 54, 78, 85*f*, 96
 - Hypertension 138
 - Hypertensive heart disease 179
 - Hypertrophic
 - apical cardiomyopathy 94*f*
 - cardiomyopathy 76
 - obstructive cardiomyopathy 140
 - Hyperventilation 106
 - Hypoglycemia 160
 - Hypotension and heart failure 160
 - Hypothermia 203
 - Hypoxemia 160
 - Hypoxia 179, 203

234 ECG Made Easy

I

- Idiopathic cardiomyopathy 179
- Incomplete bundle branch block 79
- Indeterminate QRS axis 39
- Inferior wall infarction 39, 64, 65, 151, 172
- Intracardiac shunt 72
- Intracranial tension and glaucoma 211
- Intraventricular conduction defect 78, 79, 84, 189, 197, 225
- Irregular
 - rhythm 49
 - slow rhythm 214
- Irregularly irregular rhythm 49
- Ischemia 138
- Ischemic

- cardiomyopathy 62
- heart disease 166

J

- Jerwell-Lange-Nielson syndrome 126
- Junctional
 - escape rhythm 150
 - pacemaker rhythm 123
 - premature beats 129
 - rhythm 46, 47, 54, 170*t*, 209*f*, 212
 - tachycardia 46, 170*t*, 172

L

- Lateral wall
 - infarction 38
 - ischemia 95
- Left
 - anterior
 - fascicular block 66*f*
 - hemiblock 39, 64, 65

- axis deviation 38, 63, 66*f*
- bundle branch block 67, 72, 76, 78, 79, 95
- circumflex disease 114
- posterior
 - fascicular block 66*f*
 - hemiblock 38, 64
- ventricular
 - aneurysm 39
 - diastolic overload 77
 - hypertrophy 39, 64, 67, 72, 74, 75*f*, 95, 140
- Lone atrial fibrillation 180
- Low voltage QRS complexes 84
- Lown-Ganong-Levine syndrome 122

M

- Magnitude of deflection on ECG 4*f*
- Massive pulmonary embolism 160
- Metabolic disorder 190
- Mirror-image dextrocardia 71, 74
- Mitral valve
 - disease 72
 - prolapse syndrome 95
- Monomorphic ventricular tachycardia 185*f*
- Multifocal atrial tachycardia 55, 84, 123, 175*f*, 176, 178, 216
- Muscle in thick chest wall 61
- Myocardial
 - activation during fibrillation 49*f*
 - disease 78, 190
 - infarction 81, 111, 136
 - injury 96
 - ischemia 161
 - scar 190
- Myocarditis 78, 138, 160, 166

N

Normal

ECG

- deflections 9*f*
- intervals 12*f*, 30*f*
- segments 14*f*, 31*f*
- values 24

P wave 24, 53

P-R

- interval 29, 118
- segment 31

QRS complex 26, 59

Q-T interval 30, 124

- regular rhythm with
 - narrow QRS 168
 - wide QRS 195

sinus rhythm 168, 171

S-T segment 32

T wave 28, 87

U wave 29, 100

wide QRS rhythm 195

North-west QRS axis 39

O

Obese stocky built 38, 64

Obstructive jaundice and uremia
211

Old anteroseptal infarction 67

Origin of cardiac rhythm 47*f*

Ostium

primum 39, 64, 81

secundum 38, 64, 81

P

Paroxysmal atrial tachycardia 161

Partial intraventricular conduction
defect 78

Patent ductus arteriosus 76

Pericarditis 136, 160, 166

Persistent juvenile pattern 71, 73,
95

Polymorphic ventricular
tachycardia 186*f*

Positive deflection 4

Posterior wall infarction 74

P-R

interval 12

segment 14

Precise determination of heart rate
44*t*

Primary pulmonary hypertension
72

Prinzmetal's angina 96, 112

Prolonged P-R interval 119*f*

Pseudo-prolonged Q-T interval in
hypokalemia 127*f*

Pulmonary

embolism 106

hypertension 72

stenosis 72

Purkinje system repolarization 28

Q

QRS

axis 34

vector projected on hexaxial
system 35

Q-T interval 13

Quinidine 203

R

Radiofrequency ablation 183

Recurrent pulmonary embolism
180

Regular

fast rhythm 153

normal rhythm 168

rhythm 49

slow rhythm 206

- Regularly irregular rhythm 49
 - Respiratory tract infection 179
 - Rheumatic
 - carditis 136, 172, 197
 - fever 150, 161
 - heart disease 166, 179
 - Right
 - atrial enlargement 84
 - axis deviation 63, 66
 - bundle branch block 8, 65, 71, 73, 79, 80*f*, 83, 95
 - coronary artery spasm 151
 - ventricular hypertrophy 38, 64, 71, 73*f*, 84, 95
 - Rightward QRS axis deviation 84
 - Romano-Ward syndrome 126
- S**
- Sagging depression 109
 - Second-degree A-V block 146*f*, 147*f*
 - Serious ventricular arrhythmia 226
 - Severe right ventricular hypertrophy 64
 - Shortened
 - P-R interval 120,
 - Q-T interval 125
 - Sick sinus syndrome 180, 211
 - Signal averaged electrocardiogram 192
 - Significance of ECG deflections 10
 - Sinoatrial block 150
 - Sinus
 - and atrial tachycardia 156*t*
 - arrhythmia 214, 215*f*, 217
 - bradycardia 150, 207*f*, 211
 - rhythm 47, 209, 210
 - tachycardia 83, 104, 153, 154*f*, 160
 - Slow
 - atrial fibrillation 150, 219
 - irregular rhythm with narrow QRS 214
 - regular rhythm with
 - narrow QRS 206
 - wide QRS 220
 - rhythm with existing wide QRS 229
 - wide QRS rhythm 220
 - Small deflection 4
 - Spread of impulse 7*f*
 - S-T segment 14
 - Standard limb leads 16
 - Subclavian steal syndrome 226
 - Supraventricular
 - premature complexes 135
 - rhythm 48
 - tachycardia 187, 188
 - Systemic hypertension 76, 81
 - Systolic LV overload 76
- T**
- Tachycardia 42, 106
 - Tall deflection 4
 - Thick chest 4
 - Thin chest 4
 - Thyrotoxicosis 136, 161, 166, 172, 180
 - Triaxial reference system 21
 - Triplet of ventricular ectopic beats 136*f*
 - True posterior wall infarction 71
- V**
- Vagal dominance in athletes 119
 - Valvular abnormality 191
 - Variation of heart rate 42*f*
 - Vasovagal syncope 211

Ventricular

- activation pattern 48*f*
- aneurysm 112, 138
- fibrillation 49, 200, 201*f*
- flutter 199, 200*f*, 202
- hypertrophy 88, 94, 106, 112
- pre-excitation syndrome 79, 197
- premature
 - beats 129
 - complexes 137
- rhythm 46-48, 51
- septal defect 76
- tachycardia 46, 54, 184, 189*f*

W

- Wandering pacemaker rhythm 55, 123, 215, 216*f*, 218
- Wide QRS
 - arrhythmias 78, 79
 - complex 86
- WPW syndrome 38, 64, 71, 74, 78, 85, 88, 95, 106, 112, 120, 180, 189, 225

Z

- Zones of myocardial infarction 69*f*