




F. A. Davis Company

Always at your side...

ECG Notes



Interpretation and Management Guide

Shirley A. Jones

**Waterproof
and
Reusable**

Includes...

- ✓ **Wipe-Free Forms**
- ✓ **Cardiac A&P**
- ✓ **ECG Basics**
- ✓ **60+ Arrhythmias Analyzed**
- ✓ **Easy-to-Read 6-Second ECG Strips**
- ✓ **Emergency Meds**
- ✓ **Latest Cardiac Markers**
- ✓ **12-Lead Interpretation**
- ✓ **Clinical Tips**
- ✓ **CPR Guidelines**
- ✓ **ACLS Protocols**
- ✓ **50+ Test-Yourself ECG Strips**
- ✓ **ECG Heart Rate Ruler**

and more!

Contacts • Phone/E-Mail

Name:

Ph:

e-mail:

Name:

Ph:

e-mail:

Name:

Ph:

e-mail:

Name:

Ph:

e-mail:

Name:

Ph:

e-mail:

Name:

Ph:

e-mail:

Name:

Ph:

e-mail:

Name:

Ph:

e-mail:

Name:

Ph:

e-mail:

Name:

Ph:

e-mail:

Name:

Ph:

e-mail:

Name:

Ph:

e-mail:

ECG Notes

Interpretation and Management Guide

Shirley A. Jones, MS Ed, MHA, EMT-P

Purchase additional copies of this book at your health science bookstore or directly from F. A. Davis by shopping online at www.fadavis.com or by calling 800-323-3555 (US) or 800-665-1148 (CAN)

A Davis's Notes Book



F. A. Davis Company • Philadelphia

F. A. Davis Company
1915 Arch Street
Philadelphia, PA 19103
www.fadavis.com

Copyright © 2005 by F. A. Davis Company

All rights reserved. This book is protected by copyright. No part of it may be reproduced, stored in a retrieval system, or transmitted in any form or by any means, electronic, mechanical, photocopying, recording, or otherwise, without written permission from the publisher.

Printed in China by Imago

Last digit indicates print number: 10 9 8 7 6 5 4 3 2 1

Publisher, Nursing: Lisa Deitch
Project Editor: Ilysa H. Richman
Developmental Editor: Anne-Adele Wight
Design Manager: Joan Wendt
Cover Design: Paul Fry
Consultant: Dawn McKay, RN, MSN, CCRN

As new scientific information becomes available through basic and clinical research, recommended treatments and drug therapies undergo changes. The author(s) and publisher have done everything possible to make this book accurate, up to date, and in accord with accepted standards at the time of publication. The author(s), editors, and publisher are not responsible for errors or omissions or for consequences from application of the book, and make no warranty, expressed or implied, in regard to the contents of the book. Any practice described in this book should be applied by the reader in accordance with professional standards of care used in regard to the unique circumstances that may apply in each situation. The reader is advised always to check product information (package inserts) for changes and new information regarding dose and contraindications before administering any drug. Caution is especially urged when using new or infrequently ordered drugs.

Authorization to photocopy items for internal or personal use, or the internal or personal use of specific clients, is granted by F. A. Davis Company for users registered with the Copyright Clearance Center (CCC) Transactional Reporting Service, provided that the fee of \$.10 per copy is paid directly to CCC, 222 Rosewood Drive, Danvers, MA 01923. For those organizations that have been granted a photocopy license by CCC, a separate system of payment has been arranged. The fee code for users of the Transactional Reporting Service is: 8036-1347-4/05 0 + \$.10.

Place $2\frac{7}{8} \times 2\frac{7}{8}$ **Sticky Notes** here
for a convenient and refillable note pad

- ✓ HIPAA Compliant
- ✓ OSHA Compliant

**Waterproof and Reusable
Wipe-Free Pages**

Write directly onto any page of *ECG Notes* with a ballpoint pen. Wipe old entries off with an alcohol pad and reuse.

BASICS

ECGS

12-LEAD

**MEDS/
SKILLS**

CPR

ACLS

**TEST
STRIPS**

TOOLS

Look for our other Davis's Notes titles

Available Now!

RNotes[®]: *Nurse's Clinical Pocket Guide*
ISBN: 0-8036-1060-2

LPN Notes: *Nurse's Clinical Pocket Guide*
ISBN: 0-8036-1132-3

MedNotes: *Nurse's Pharmacology Pocket Guide*
ISBN: 0-8036-1109-9

MedSurg Notes: *Nurse's Clinical Pocket Guide*
ISBN: 0-8036-1115-3

NutriNotes: *Nutrition & Diet Therapy Pocket Guide*
ISBN: 0-8036-1114-5

IV Therapy Notes: *Nurse's Clinical Pocket Guide*
ISBN: 0-8036-1288-5

PsychNotes: *Clinical Pocket Guide*
ISBN: 0-8036-1286-9

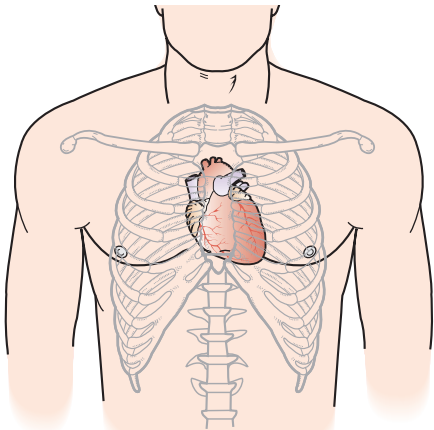
LabNotes: *Pocket Guide to Lab & Diagnostic Tests*
ISBN: 0-8036-1265-6

OrthoNotes: *A Clinical Examination Pocket Guide*
ISBN: 0-8036-1350-4

MA Notes: *Medical Assistant's Pocket Guide*
ISBN: 0-8036-1281-8

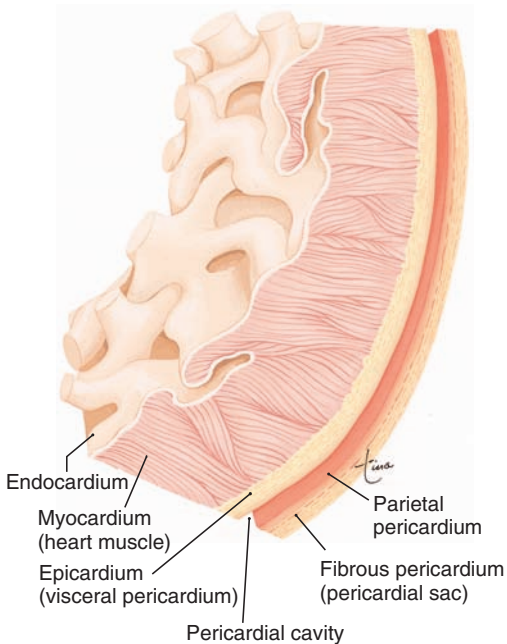
Anatomy of the Heart

The heart, located in the mediastinum, is the central structure of the cardiovascular system. It is protected by the bony structures of the sternum anteriorly, the spinal column posteriorly, and the rib cage.



♥ **Clinical Tip:** The cone-shaped heart has its tip (apex) just above the diaphragm to the left of the midline. This is why we may think of the heart as being on the left side, since the strongest beat can be heard or felt here.

Layers of the Heart

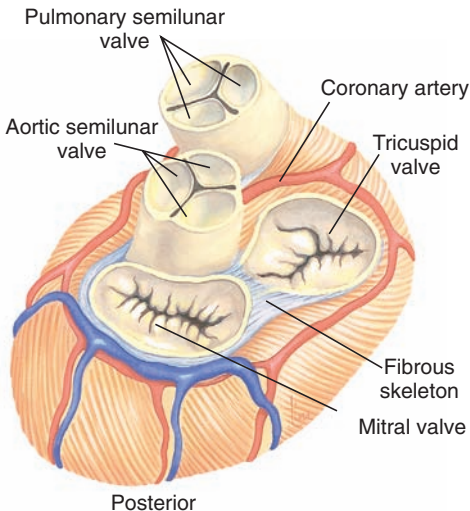


The pericardial cavity contains a small amount of lubricating fluid to prevent friction during heart contraction.

Heart Valves

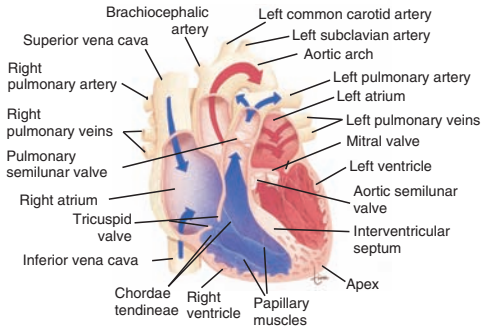
Properties of Heart Valves

- Fibrous connective tissue prevents enlargement of valve openings and anchors valve flaps.
- Valve closure prevents backflow of blood during and after contraction.

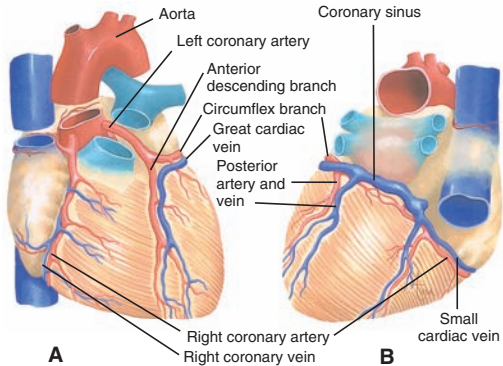


The atria have been removed in this superior view.

Heart Chambers and Great Vessels



Coronary Arterial Circulation



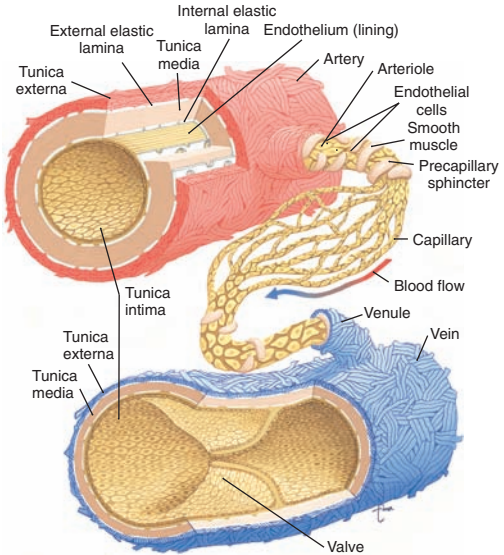
(A) Anterior view

(B) Posterior view

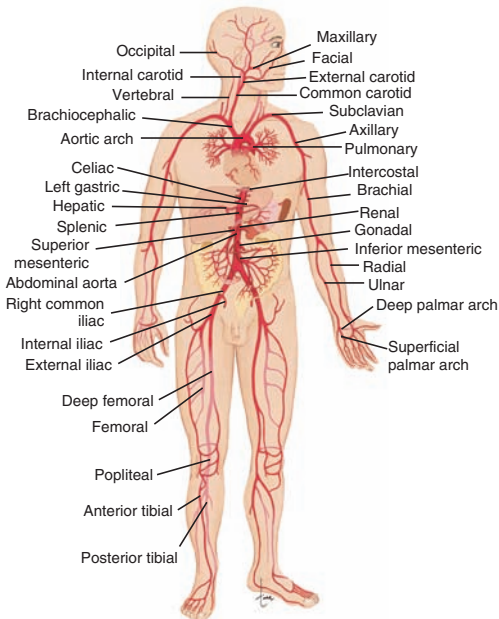
Anatomy of the Cardiovascular System

The cardiovascular system is a closed system consisting of blood vessels and the heart. Arteries and veins are connected by smaller structures in which electrolytes are exchanged across cell membranes.

Blood Vessel Structures

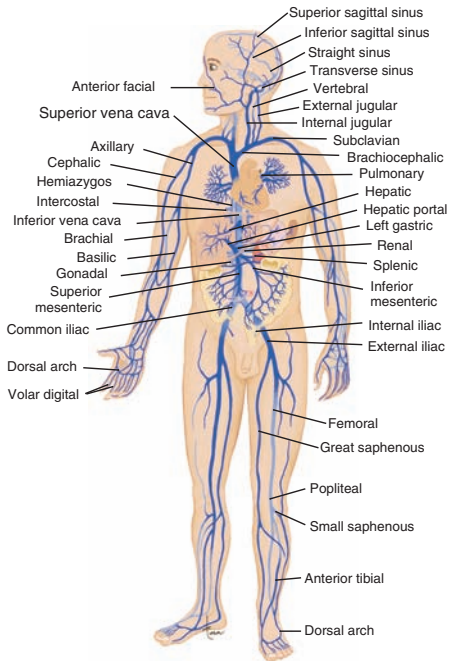


Arterial Circulation



Arteries (excluding the pulmonary artery) transport oxygenated blood.

Venous Circulation



Veins (excluding the pulmonary vein) carry blood low in oxygen and high in carbon dioxide.

Physiology of the Heart

Mechanics of Heart Function

| Process | Action |
|---------------------|---|
| Cardiac cycle | Sequence of events in 1 heartbeat. Blood is pumped through the entire cardiovascular system. |
| Systole | Contraction phase—usually refers to ventricular contraction. |
| Diastole | Relaxation phase—the atria and ventricles are filling. Lasts longer than systole. |
| Stroke volume (SV) | Amount of blood ejected from either ventricle in a single contraction. Starling's Law of the Heart states that degree of cardiac muscle stretch can increase force of ejected blood. More blood filling the ventricles \uparrow SV. |
| Cardiac output (CO) | Amount of blood pumped through the cardiovascular system per min. $CO = SV \times \text{Heart rate (HR)}$ |

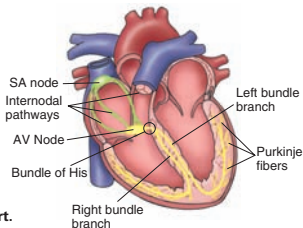
Properties of Cardiac Cells

| Property | Ability |
|---------------|---|
| Automaticity | Generates electrical impulse independently, without involving the nervous system. |
| Excitability | Responds to electrical stimulation. |
| Conductivity | Passes or propagates electrical impulses from cell to cell. |
| Contractility | Shortens in response to electrical stimulation. |

Electrical Conduction System of the Heart

Conduction System Structures and Functions

| Structure | Function and Location |
|----------------------------|--|
| Sinoatrial (SA) node | Dominant pacemaker of the heart, located in upper portion of right atrium. Intrinsic rate 60–100 bpm. |
| Internodal pathways | Direct electrical impulses between SA and AV nodes. |
| Atrioventricular (AV) node | Part of AV junctional tissue. Slows conduction, creating a slight delay before impulses reach ventricles. Intrinsic rate 40–60 bpm. |
| Bundle of His | Transmits impulses to bundle branches. Located below AV node. |
| Left bundle branch | Conducts impulses that lead to left ventricle. |
| Right bundle branch | Conducts impulses that lead to right ventricle. |
| Purkinje system | Network of fibers that spreads impulses rapidly throughout ventricular walls. Located at terminals of bundle branches. Intrinsic rate 20–40 bpm. |



Conduction system of the heart.

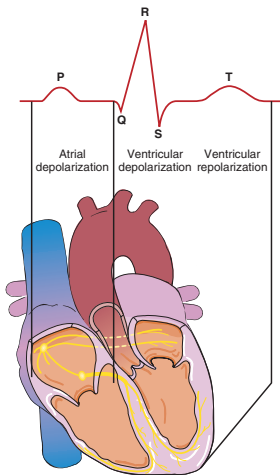
Electrical Conduction System of the Heart

Electrophysiology

| Action | Effect |
|----------------|---|
| Depolarization | The electrical charge of a cell is altered by a shift of electrolytes on either side of the cell membrane. This change stimulates muscle fiber to contract. |
| Repolarization | Chemical pumps re-establish an internal negative charge as the cells return to their resting state. |

Depolarization and repolarization of the heart.

♥ **Clinical Tip:** Mechanical and electrical functions of the heart are influenced by proper electrolyte balance. Important components of this balance are sodium, calcium, potassium, and magnesium.



The Electrocardiogram (ECG)

- An ECG is a series of waves and deflections recording the heart's electrical activity from a certain "view."
- Many views, each called a lead, monitor voltage changes between electrodes placed in different positions on the body.
- Leads I, II, and III are bipolar leads, which consist of two electrodes of opposite polarity (positive and negative). The third (ground) electrode minimizes electrical activity from other sources.
- Leads aVR, aVL, and aVF are unipolar leads and consist of a single positive electrode and a reference point (with zero electrical potential) that lies in the center of the heart's electrical field.
- Leads V₁–V₆ are unipolar leads and consist of a single positive electrode with a negative reference point found at the electrical center of the heart.
- Voltage changes are amplified and visually displayed on an oscilloscope and graph paper.
- An ECG tracing looks different in each lead because the recorded angle of electrical activity changes with each lead.
- Several different angles allow a more accurate perspective than a single one would.
- The ECG machine can be adjusted to make any skin electrode positive or negative. The polarity depends on which lead the machine is recording.
- A cable attached to the patient is divided into several different-colored wires: three, four, or five for monitoring purposes, or ten for a 12-lead ECG.
- Incorrect placement of electrodes may turn a normal ECG tracing into an abnormal one.

♥ **Clinical Tip:** Patients should be treated according to their symptoms, not merely their ECG.

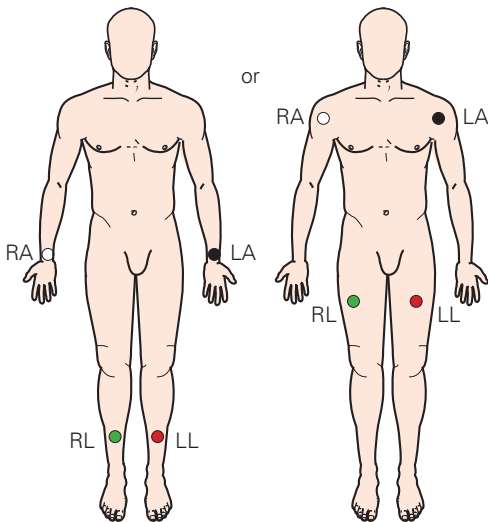
♥ **Clinical Tip:** To obtain a 12-lead ECG, four wires are attached to each limb and six wires are attached at different locations on the chest. The total of ten wires provides twelve views (12 leads).

Limb Leads

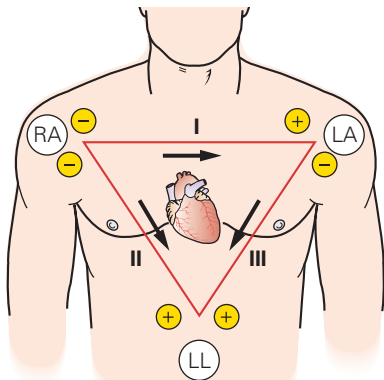
Electrodes are placed on the right arm (RA), left arm (LA), right leg (RL), and left leg (LL). With only four electrodes, six leads are viewed.

- Standard leads: I, II, III
- Augmented leads: aVR, aVL, aVF

Standard Limb Lead Electrode Placement



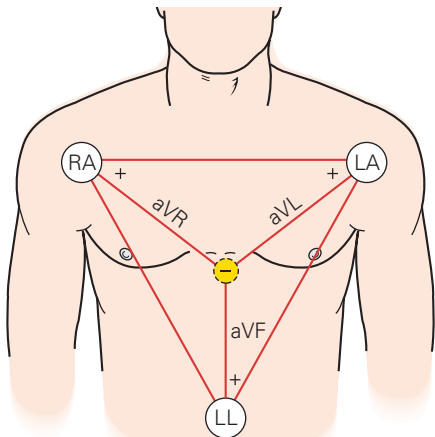
Standard Limb Leads



Elements of Standard Limb Leads

| Lead | Positive Electrode | Negative Electrode | View of Heart |
|------|--------------------|--------------------|---------------|
| I | LA | RA | Lateral |
| II | LL | RA | Inferior |
| III | LL | LA | Inferior |

Augmented Limb Leads

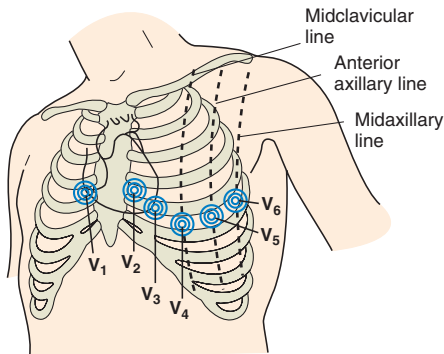


Elements of Augmented Limb Leads

| Lead | Positive Electrode | View of Heart |
|------|--------------------|---------------|
| aVR | RA | None |
| aVL | LA | Lateral |
| aVF | LL | Inferior |

Chest Leads

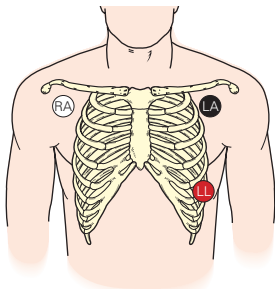
Standard Chest Lead Electrode Placement



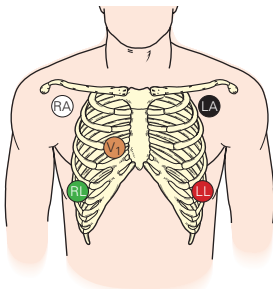
Elements of Chest Leads

| Lead | Positive Electrode Placement | View of Heart |
|----------------|--|---------------|
| V ₁ | 4th Intercostal space to right of sternum | Septum |
| V ₂ | 4th Intercostal space to left of sternum | Septum |
| V ₃ | Directly between V ₂ and V ₄ | Anterior |
| V ₄ | 5th Intercostal space at left midclavicular line | Anterior |
| V ₅ | Level with V ₄ at left anterior axillary line | Lateral |
| V ₆ | Level with V ₅ at left midaxillary line | Lateral |

Electrode Placement Using a 3-Wire Cable



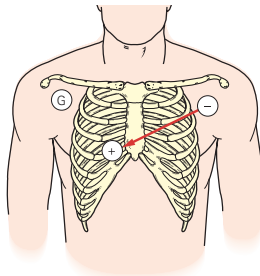
Electrode Placement Using a 5-Wire Cable



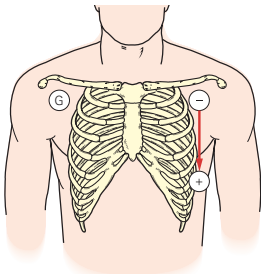
♥ **Clinical Tip:** Five-wire telemetry units are commonly used to monitor leads I, II, III, aVR, aVL, aVF, and V₁ in critical care settings.

Modified Chest Leads

- Modified chest leads (MCL) are useful in detecting bundle branch blocks and premature beats.
- Lead MCL₁ simulates chest lead V₁ and views the ventricular septum.
- Lead MCL₆ simulates chest lead V₆ and views the lateral wall of the left ventricle.



Lead MCL₁ electrode placement.

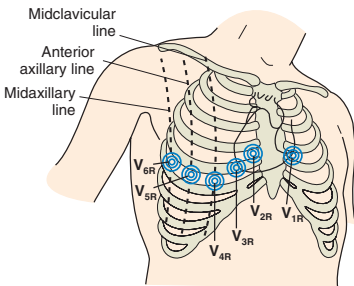


Lead MCL₆ electrode placement.

♥ **Clinical Tip:** Write on the rhythm strip which simulated lead was used.

The Right-Sided 12-Lead ECG

- The limb leads are placed as usual but the chest leads are a mirror image of the standard 12-lead chest placement.
- The ECG machine cannot recognize that the leads have been reversed. It will still print "V₁-V₆" next to the tracing. Be sure to cross this out, and write the new lead positions on the ECG paper.



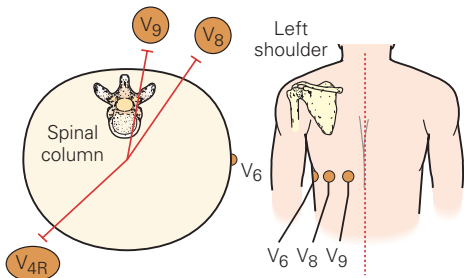
The Right-Sided 12-Lead ECG

| Chest Leads | Position |
|-----------------|--|
| V _{1R} | 4th Intercostal space to left of sternum |
| V _{2R} | 4th Intercostal space to right of sternum |
| V _{3R} | Directly between V _{2R} and V _{4R} |
| V _{4R} | 5th Intercostal space at right midclavicular line |
| V _{5R} | Level with V _{4R} at right anterior axillary line |
| V _{6R} | Level with V _{5R} at right midaxillary line |

♥ **Clinical Tip:** Patients with an acute inferior MI should have right-sided ECGs to assess for possible right ventricular infarction.

The 15-Lead ECG

Areas of the heart that are not well visualized by the six chest leads include the wall of the right ventricle and the posterior wall of the left ventricle. A 15-lead ECG, which includes the standard 12 leads plus leads V_{4R} , V_8 , and V_9 , increases the chance of detecting an MI in these areas.

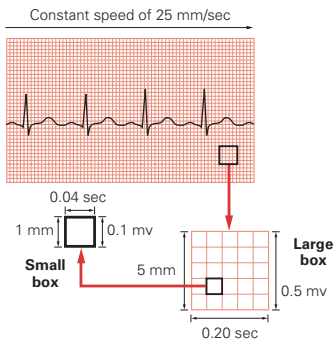


The 15-Lead ECG

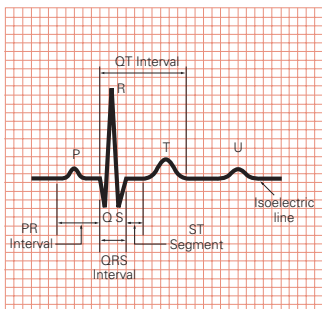
| Chest Leads | Electrode Placement | View of Heart |
|-------------|---|----------------------------------|
| V_{4R} | 5th Intercostal space in right anterior midclavicular line | Right ventricle |
| V_8 | Posterior 5th intercostal space in left midscapular line | Posterior wall of left ventricle |
| V_9 | Directly between V_8 and spinal column at posterior 5th intercostal space | Posterior wall of left ventricle |

♥ **Clinical Tip:** Use a 15-lead ECG when the 12-lead is normal but the history is still suggestive of an acute infarction.

Recording of the ECG



Components of an ECG Tracing



Electrical Components

| Deflection | Description |
|-------------------|--|
| P Wave | First wave seen Small rounded, upright (positive) wave indicating atrial depolarization (and contraction) |
| PR Interval | Distance between beginning of P wave and beginning of QRS complex Measures time during which a depolarization wave travels from the atria to the ventricles |
| QRS Interval | Three deflections following P wave Indicates ventricular depolarization (and contraction) Q Wave: First negative deflection R Wave: First positive deflection S Wave: First negative deflection after R wave |
| ST Segment | Distance between S wave and beginning of T wave Measures time between ventricular depolarization and beginning of repolarization |
| T Wave | Rounded upright (positive) wave following QRS Represents ventricular repolarization |
| QT Interval | Measured from beginning of QRS to end of T wave. Represents total ventricular activity. |
| U Wave | Small rounded, upright wave following T wave Most easily seen with a slow HR. Represents repolarization of Purkinje fibers. |

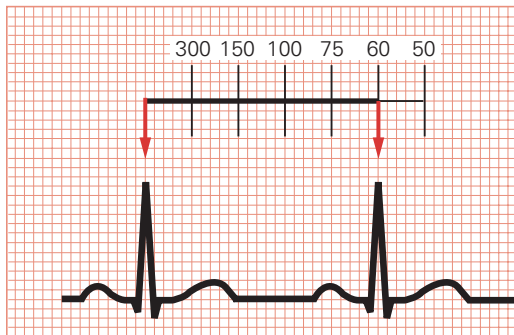Methods for Calculating Heart Rate

Heart rate is calculated as the number of times the heart beats per minute. It usually measures ventricular rate (the number of QRS complexes) but can refer to atrial rate (the number of P waves). The method chosen to calculate HR varies according to rate and regularity on the ECG tracing.

Method 1: Count Large Boxes

Regular rhythms can be quickly determined by counting the number of large graph boxes between two R waves. That number is divided into 300 to calculate bpm. The rates for the first one to six large boxes can be easily memorized.

Remember: $60 \text{ sec/min} \div 0.20 \text{ sec/large box} = 300 \text{ large boxes/min}$.



Counting large boxes for heart rate. The rate is 60 bpm.

Method 2: Count Small Boxes

Sometimes it is necessary to count the number of small boxes between two R waves for fast heart rates. That number is divided into 1500 to calculate bpm. Remember: 60 sec/min divided by 0.04 sec/small box = 1500 small boxes/min.

Examples: If there are six small boxes between two R waves:
 $1500/6 = 250$ bpm.

If there are ten small boxes between two R waves:
 $1500/10 = 150$ bpm.

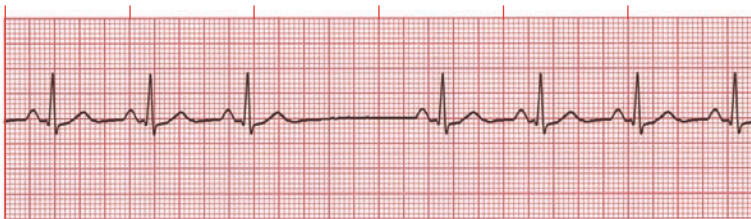Methods 1 and 2 for Calculating Heart Rate

| Number of Large Boxes | Rate/Min | Number of Small Boxes | Rate/Min |
|-----------------------|----------|-----------------------|----------|
| 1 | 300 | 2 | 750 |
| 2 | 150 | 3 | 500 |
| 3 | 100 | 4 | 375 |
| 4 | 75 | 5 | 300 |
| 5 | 60 | 6 | 250 |
| 6 | 50 | 7 | 214 |
| 7 | 43 | 8 | 186 |
| 8 | 38 | 9 | 167 |
| 9 | 33 | 10 | 150 |
| 10 | 30 | 11 | 136 |
| 11 | 27 | 12 | 125 |
| 12 | 25 | 13 | 115 |
| 13 | 23 | 14 | 107 |
| 14 | 21 | 15 | 100 |
| 15 | 20 | 16 | 94 |

♥ **Clinical Tip:** Approximate rate/min is rounded to the next-highest number.

Method 3: Six-Second ECG Rhythm Strip

The best method for measuring irregular rates with varying R-R intervals is to count the number of R waves in a 6-sec strip and multiply by 10. This gives the average number of bpm.



Using 6-sec ECG rhythm strip to calculate heart rate. Formula: $7 \times 10 = 70$ bpm

♥ **Clinical Tip:** If a rhythm is extremely irregular, it is best to count the number of R-R intervals per 60 sec (1 min).

ECG Interpretation

Analyzing a Rhythm

| Component | Characteristic |
|---------------|--|
| Rate | <p>The bpm is commonly the ventricular rate. If atrial and ventricular rates differ, as in a 3rd-degree block, measure both rates.</p> <p>Normal: 60–100 bpm Slow (bradycardia): <60 bpm Fast (tachycardia): >100 bpm</p> |
| Regularity | <p>Measure R-R intervals and P-P intervals.</p> <p>Regular: Intervals consistent Regularly irregular: Repeating pattern Irregular: No pattern</p> |
| P Waves | <p>If present: Same in size, shape, position? Does each QRS have a P wave?</p> <p>Normal: Upright (positive) and uniform Inverted: Negative Notched: P' None: Rhythm is junctional or ventricular.</p> |
| PR Interval | <p>Constant: Intervals are the same. Variable: Intervals differ.</p> <p>Normal: 0.12–0.20 sec and constant</p> |
| QRS Interval | <p>Normal: 0.06–0.10 sec Wide: >0.10 sec None: Absent</p> |
| QT Interval | <p>Beginning of R wave to end of T wave Varies with HR.</p> <p>Normal: Less than half the R-R interval</p> |
| Dropped beats | <p>Occur in AV blocks. Occur in sinus arrest.</p> |

| Component | Characteristic |
|----------------------|---|
| Pause | <p>Compensatory: Complete pause following a premature atrial contraction (PAC), premature junctional contraction (PJC), or premature ventricular contraction (PVC)</p> <p>Noncompensatory: Incomplete pause following a PAC, PJC, or PVC</p> |
| QRS Complex grouping | <p>Bigeminy: Repeating pattern of normal complex followed by a premature complex</p> <p>Trigeminy: Repeating pattern of 2 normal complexes followed by a premature complex</p> <p>Quadrigeminy: Repeating pattern of 3 normal complexes followed by a premature complex</p> <p>Couplets: 2 Consecutive premature complexes</p> <p>Triplets: 3 Consecutive premature complexes</p> |

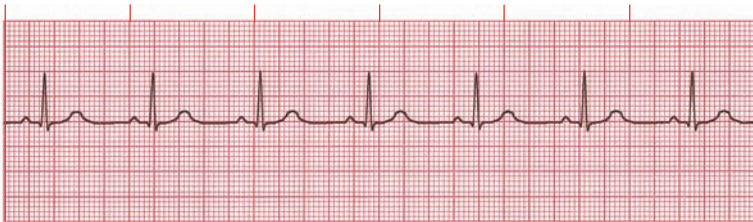
Notes:

Sinoatrial (SA) Node Arrhythmias

- Upright P waves all look similar.
- PR intervals and QRS complexes are of normal duration.

Note: All ECG strips in this tab were recorded in lead II.

Normal Sinus Rhythm (NSR)



Rate: Normal (60–100 bpm)

Rhythm: Regular

P Waves: Normal (upright and uniform)

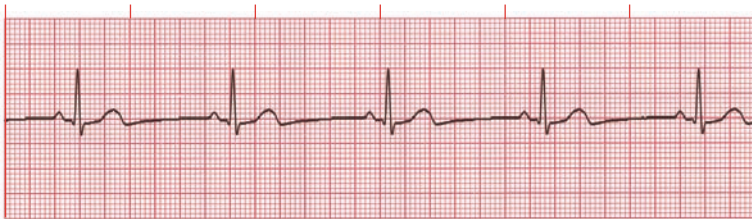PR Interval: Normal (0.12–0.20 sec)

QRS: Normal (0.06–0.10 sec)

♥ **Clinical Tip:** A normal ECG does not exclude heart disease.

Sinus Bradycardia

■ Results from slowing of the SA node.



Rate: Slow (<60 bpm)

Rhythm: Regular

P Waves: Normal (upright and uniform)

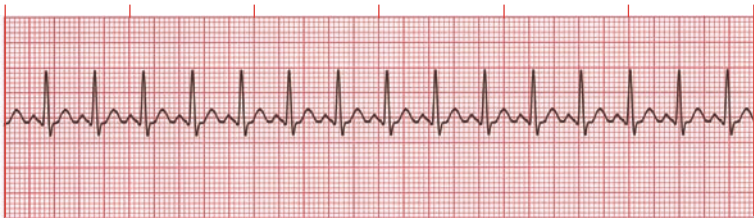
PR Interval: Normal (0.12–0.20 sec)

QRS: Normal (0.06–0.10 sec)

♥ **Clinical Tip:** Sinus bradycardia is normal in athletes and during sleep. In acute MI, it may be protective and beneficial or the slow rate may compromise cardiac output. Certain medications, such as beta blockers, may also cause sinus bradycardia.

Sinus Tachycardia

- Results from increased SA node discharge.



Rate: Fast (> 100 bpm)

Rhythm: Regular

P Waves: Normal (upright and uniform)

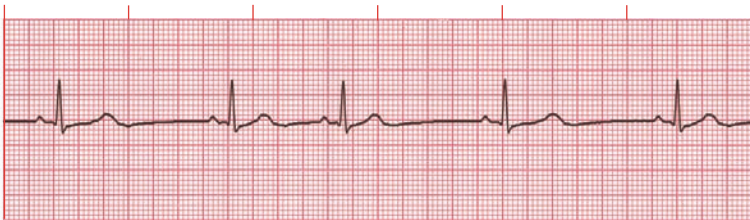
PR Interval: Normal (0.12–0.20 sec)

QRS: Normal (0.06–0.10 sec)

♥ **Clinical Tip:** Sinus tachycardia may be caused by exercise, anxiety, fever, hypoxemia, hypovolemia, or cardiac failure.

Sinus Arrhythmia

- The SA node discharges irregularly.
- The R-R interval is irregular.



Rate: Usually normal (60–100 bpm); frequently increases with inspiration and decreases with expiration

Rhythm: Irregular; varies with respiration

P Waves: Normal (upright and uniform)

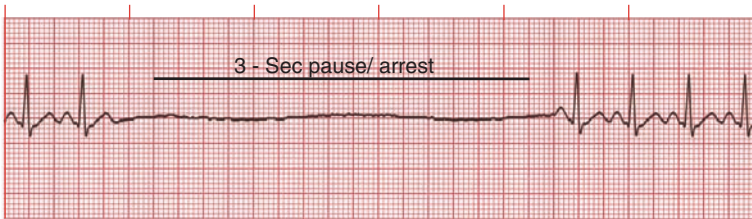PR Interval: Normal (0.12–0.20 sec)

QRS: Normal (0.06–0.10 sec)

♥ **Clinical Tip:** The pacing rate of the SA node varies with respiration, especially in children and elderly people.

Sinus Pause (Sinus Arrest)

- The SA node fails to discharge and then resumes.
- Electrical activity resumes either when the SA node resets itself or when a lower latent pacemaker begins to discharge.
- The pause (arrest) time interval is not a multiple of the normal P-P interval.



Rate: Normal to slow; determined by duration and frequency of sinus pause (arrest)

Rhythm: Irregular whenever a pause (arrest) occurs

P Waves: Normal (upright and uniform) except in areas of pause (arrest)

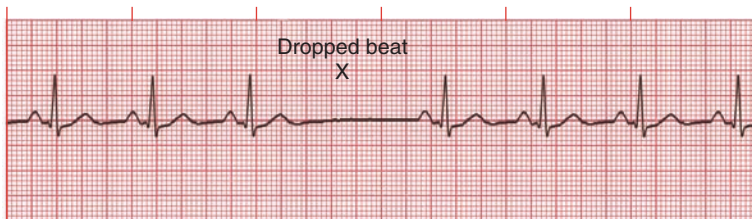
PR Interval: Normal (0.12–0.20 sec)

QRS: Normal (0.06–0.10 sec)

♥ **Clinical Tip:** Cardiac output may decrease, causing syncope or dizziness.

Sinoatrial (SA) Block

- The block occurs in some multiple of the P-P interval.
- After the dropped beat, cycles continue on time.



Rate: Normal to slow; determined by duration and frequency of SA block

Rhythm: Irregular whenever an SA block occurs

P Waves: Normal (upright and uniform) except in areas of dropped beats

PR Interval: Normal (0.12–0.20 sec)

QRS: Normal (0.06–0.10 sec)

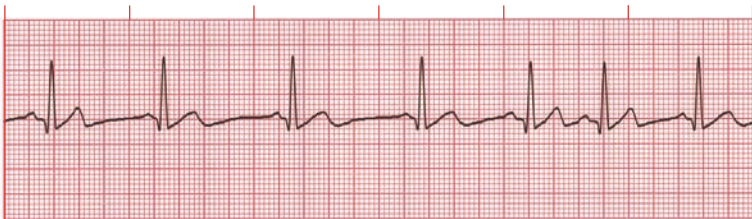♥ **Clinical Tip:** Cardiac output may decrease, causing syncope or dizziness.

Atrial Arrhythmias

- P Waves differ in appearance from sinus P waves.
- QRS Complexes are of normal duration.

Wandering Atrial Pacemaker (WAP)

- Pacemaker site transfers from the SA node to other latent pacemaker sites in the atria and the AV junction and then moves back to the SA node.



Rate: Normal (60–100 bpm)

Rhythm: Irregular

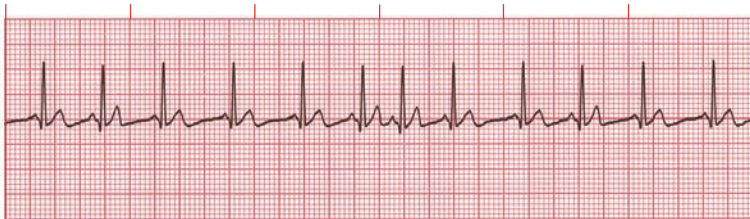
P Waves: At least three different forms, determined by the focus in the atria

PR Interval: Variable; determined by focus

QRS: Normal (0.06–0.10 sec)

Multifocal Atrial Tachycardia (MAT)

- This form of WAP is associated with a ventricular response of >100 bpm.
- MAT may be confused with atrial fibrillation (A-fib); however, MAT has a visible P wave.



Rate: Fast (>100 bpm)

Rhythm: Irregular

P Wave: At least three different forms, determined by the focus in the atria

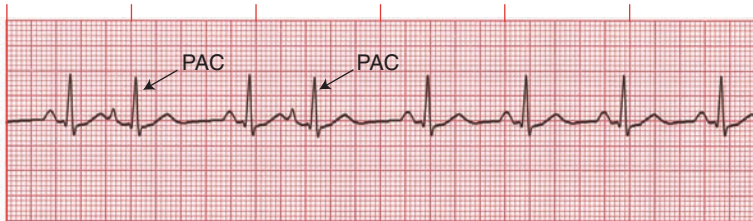
PR Interval: Variable; depends on focus

QRS: Normal (0.06–0.10 sec)

♥ **Clinical Tip:** MAT is commonly seen in patients with COPD but may also occur in acute MI.

Premature Atrial Contraction (PAC)

- A single complex occurs earlier than the next expected sinus complex.
- After the PAC, sinus rhythm usually resumes.



Rate: Depends on rate of underlying rhythm

Rhythm: Irregular whenever a PAC occurs

P Waves: Present; in the PAC, may have a different shape

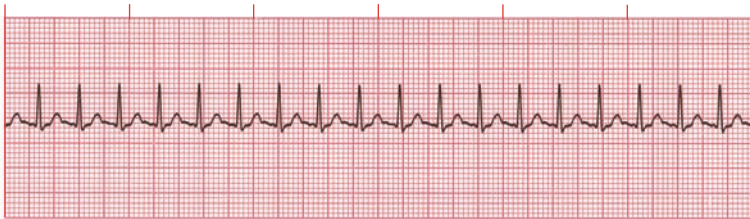PR Interval: Varies in the PAC; otherwise normal (0.12–0.20 sec)

QRS: Normal (0.06–0.10 sec)

♥ **Clinical Tip:** In patients with heart disease, frequent PACs may precede paroxysmal supraventricular tachycardia (PSVT), A-fib, or A-flutter.

Atrial Tachycardia

- A rapid atrial rate overrides the SA node and becomes the dominant pacemaker.
- Some ST wave and T wave abnormalities may be present.



Rate: 150–250 bpm

Rhythm: Regular

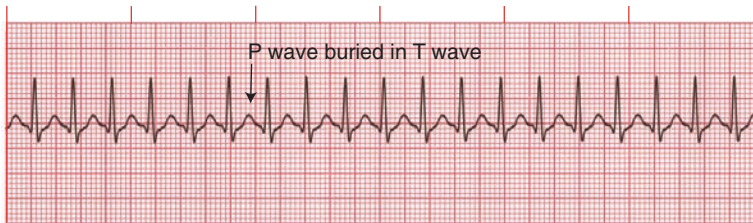
P Waves: Normal (upright and uniform) but differ in shape from sinus P waves

PR Interval: May be short (<0.12 sec) in rapid rates

QRS: Normal (0.06–0.10 sec) but can be aberrant at times

Supraventricular Tachycardia (SVT)

- This arrhythmia has such a fast rate that the P waves may not be seen.



Rate: 150–250 bpm

Rhythm: Regular

P Waves: Frequently buried in preceding T waves and difficult to see

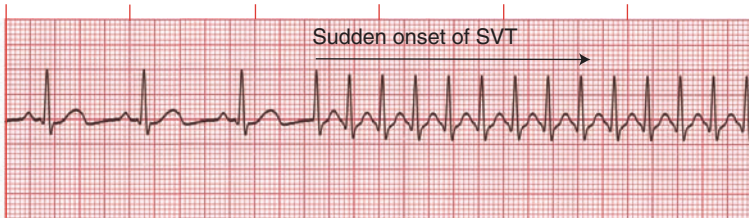
PR Interval: Usually not possible to measure

QRS: Normal (0.06–0.10 sec) but may be wide if abnormally conducted through ventricles

♥ **Clinical Tip:** SVT may be related to caffeine intake, nicotine, stress, or anxiety in healthy adults.

Paroxysmal Supraventricular Tachycardia (PSVT)

- PSVT is a rapid rhythm that starts and stops suddenly.
- For accurate interpretation, the beginning or end of the PSVT must be seen.
- PSVT is sometimes called paroxysmal atrial tachycardia (PAT).



Rate: 150–250 bpm

Rhythm: Regular

P Waves: Frequently buried in preceding T waves and difficult to see

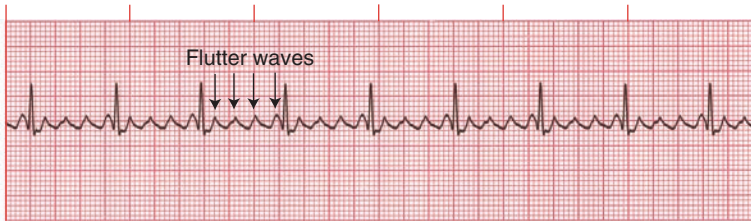
PR Interval: Usually not possible to measure

QRS: Normal (0.06–0.10 sec) but may be wide if abnormally conducted through ventricles

♥ **Clinical Tip:** The patient may feel palpitations, dizziness, lightheadedness, or anxiety.

Atrial Flutter (A-flutter)

- AV node conducts impulses to the ventricles at a 2:1, 3:1, 4:1, or greater ratio (rarely 1:1).
- Degree of AV block may be consistent or variable.



Rate: Atrial: 250–350 bpm; ventricular: slow or fast

Rhythm: Usually regular but may be variable

P Waves: Flutter waves have a saw-toothed appearance

PR Interval: Variable

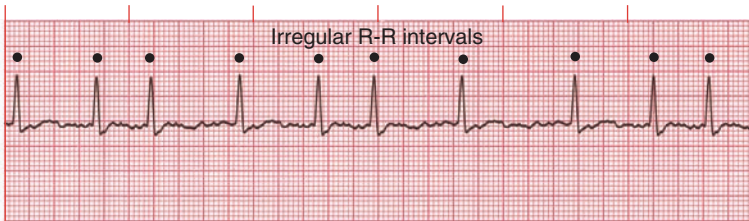
QRS: Usually normal (0.06–0.10 sec), but may appear widened if flutter waves are buried in QRS

♥ **Clinical Tip:** The presence of A-flutter may be the first indication of cardiac disease.

♥ **Clinical Tip:** Signs and symptoms depend on ventricular response rate.

Atrial Fibrillation (A-fib)

- Rapid, erratic electrical discharge comes from multiple atrial ectopic foci.
- No organized atrial contractions are detectable.



Rate: Atrial: 350 bpm or greater; ventricular: slow or fast

Rhythm: Irregular

P Waves: No true P waves; chaotic atrial activity

PR Interval: None

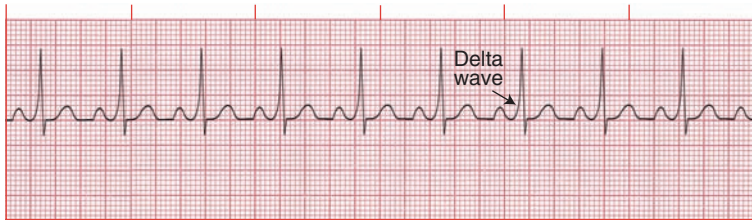
QRS: Normal (0.06–0.10 sec)

♥ **Clinical Tip:** A-fib is usually a chronic arrhythmia associated with underlying heart disease.

♥ **Clinical Tip:** Signs and symptoms depend on ventricular response rate.

Wolff-Parkinson-White (WPW) Syndrome

- In WPW an accessory conduction pathway is present between the atria and the ventricles. Electrical impulses are rapidly conducted to the ventricles.
- These rapid impulses create a slurring of the initial portion of the QRS called the delta wave.



Rate: Depends on rate of underlying rhythm

Rhythm: Regular unless associated with A-fib

P Waves: Normal (upright and uniform) unless A-fib is present

PR Interval: Short (<0.12 sec) if P wave is present

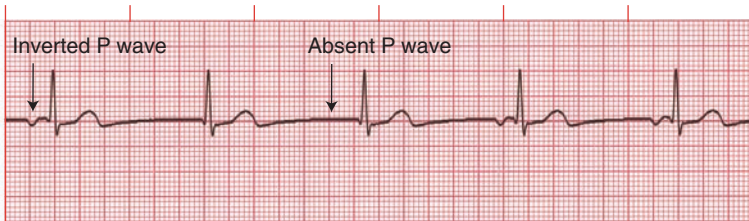
QRS: Wide (>0.10 sec); delta wave present

♥ **Clinical Tip:** WPW is associated with narrow-complex tachycardias, including A-flutter and A-fib.

Junctional Arrhythmias

- The atria and SA node do not perform their normal pacemaking functions.
- A junctional escape rhythm begins.

Junctional Rhythm



Rate: 40–60 bpm

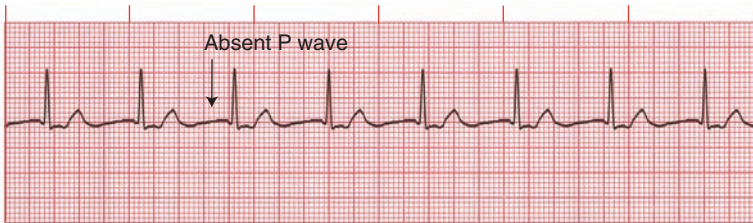
Rhythm: Regular

P Waves: Absent, inverted, buried, or retrograde

PR Interval: None, short, or retrograde

QRS: Normal (0.06–0.10 sec)

Accelerated Junctional Rhythm



Rate: 61–100 bpm

Rhythm: Regular

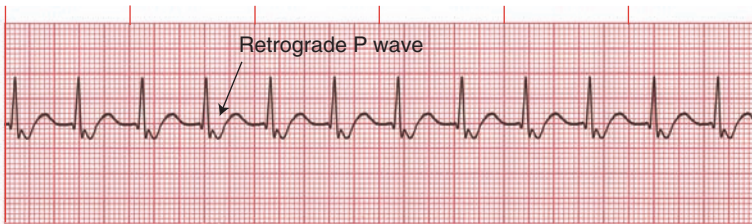
P Waves: Absent, inverted, buried, or retrograde

PR Interval: None, short, or retrograde

QRS: Normal (0.06–0.10 sec)

♥ **Clinical Tip:** Monitor the patient, not just the ECG, for clinical improvement.

Junctional Tachycardia



45

Rate: 101–180 bpm

Rhythm: Regular

P Waves: Absent, inverted, buried, or retrograde

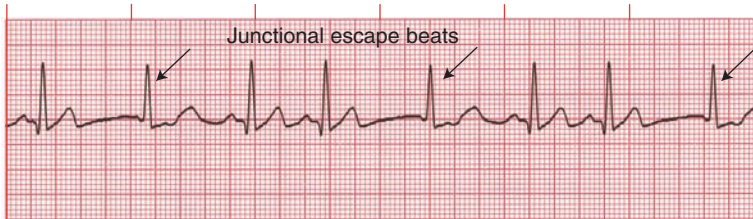
PR Interval: None, short, or retrograde

QRS: Normal (0.06–0.10 sec)

♥ **Clinical Tip:** Signs and symptoms of decreased cardiac output may be seen in response to the rapid rate.

Junctional Escape Beat

- An escape complex comes later than the next expected sinus complex.



Rate: Depends on rate of underlying rhythm

Rhythm: Irregular whenever an escape beat occurs

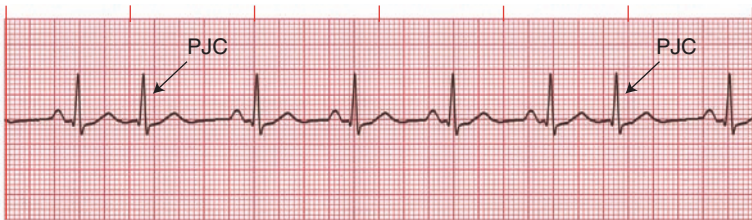P Waves: None, inverted, buried, or retrograde in the escape beat

PR Interval: None, short, or retrograde

QRS: Normal (0.06–0.10 sec)

Premature Junctional Contraction (PJC)

- Enhanced automaticity in the AV junction produces PJCs.



Rate: Depends on rate of underlying rhythm

Rhythm: Irregular whenever a PJC occurs

P Waves: Absent, inverted, buried, or retrograde in the PJC

PR Interval: None, short, or retrograde

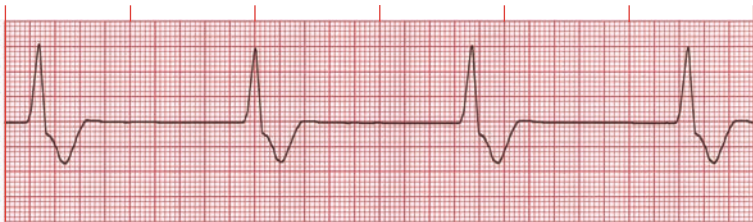
QRS: Normal (0.06–0.10 sec)

♥ **Clinical Tip:** Before deciding that isolated PJCs may be insignificant, consider the cause.

Ventricular Arrhythmias

- QRS complex is >0.10 sec. P Waves are absent or, if visible, have no consistent relationship to the QRS complex.

Idioventricular Rhythm



Rate: 20–40 bpm

Rhythm: Regular

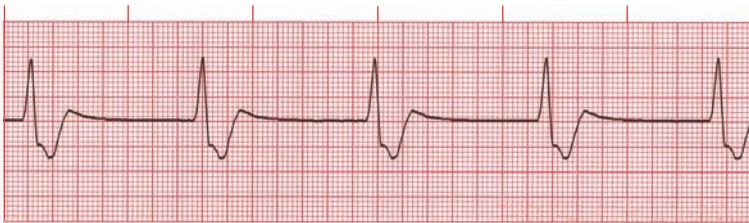P Waves: None

PR Interval: None

QRS: Wide (>0.10 sec), bizarre appearance

♥ **Clinical Tip:** Idioventricular rhythm may also be called agonal rhythm.

Accelerated Idioventricular Rhythm



49

Rate: 41–100 bpm

Rhythm: Regular

P Waves: None

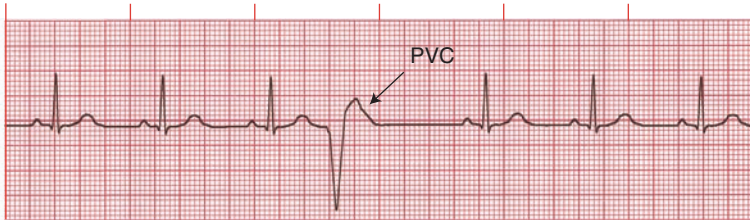
PR Interval: None

QRS: Wide (>0.10 sec), bizarre appearance

♥ **Clinical Tip:** Idioventricular rhythms appear when supraventricular pacing sites are depressed or absent. Diminished cardiac output is expected if the heart rate is slow.

Premature Ventricular Contraction (PVC)

- Usually PVCs result from an irritable ventricular focus.
- PVCs may be uniform (same form) or multiform (different forms).
- The pause following a PVC may be compensatory or noncompensatory.



Rate: Depends on rate of underlying rhythm

Rhythm: Irregular whenever a PVC occurs

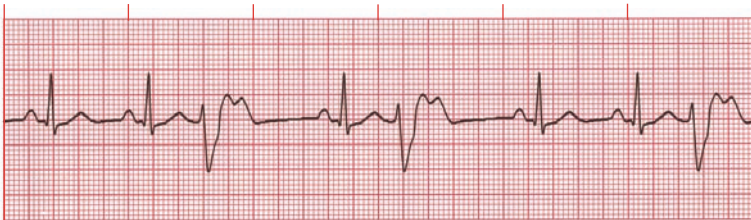P Waves: None associated with the PVC

PR Interval: None associated with the PVC

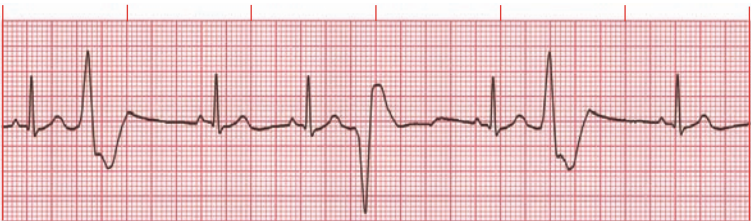QRS: Wide (>0.10 sec), bizarre appearance

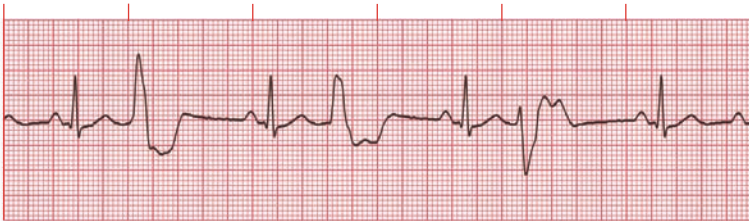
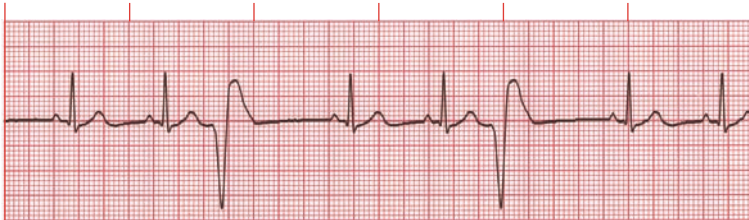
♥ **Clinical Tip:** Patients may sense the occurrence of PVCs as skipped beats. Because the ventricles are only partially filled, the PVC frequently does not generate a pulse.

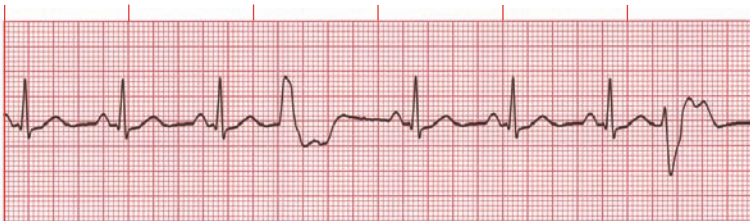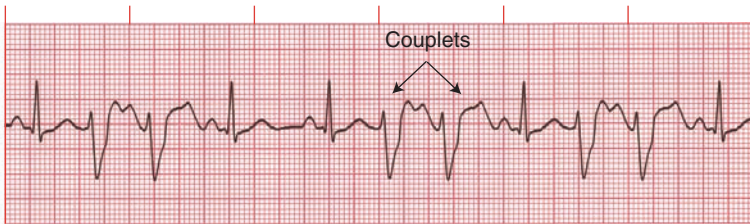
Premature Ventricular Contraction: Uniform (same form)



Premature Ventricular Contraction: Multiform (different forms)

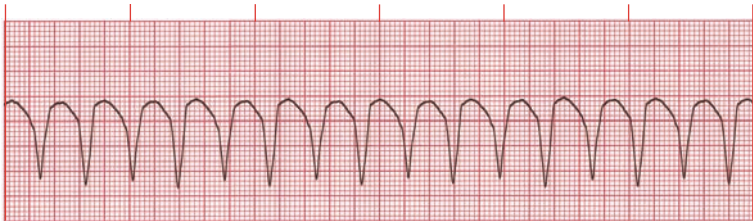


Premature Ventricular Contraction: Ventricular Bigeminy (PVC every other beat)**Premature Ventricular Contraction: Ventricular Trigeminy (PVC every 3rd beat)**

Premature Ventricular Contraction: Ventricular Quadrigeminy (PVC every 4th beat)**Premature Ventricular Contraction: Couplets (paired PVCs)**

Ventricular Tachycardia (VT): Monomorphic

- QRS complexes in monomorphic VT have the same shape and amplitude.



Rate: 100–250 bpm

Rhythm: Regular

P Waves: None or not associated with the QRS

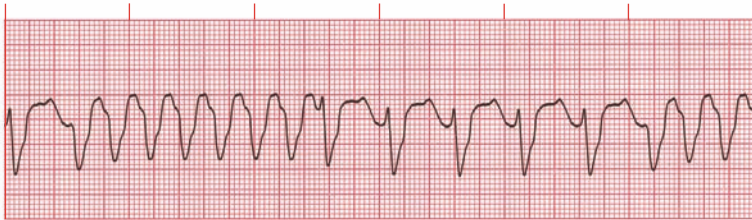PR Interval: None

QRS: Wide (>0.10 sec), bizarre appearance

- ♥ **Clinical Tip:** It is important to confirm the presence or absence of pulses because monomorphic VT may be perfusing or nonperfusing.
- ♥ **Clinical Tip:** Monomorphic VT will probably deteriorate into VF or unstable VT if sustained and not treated.

Ventricular Tachycardia (VT): Polymorphic

- QRS complexes in polymorphic VT vary in shape and amplitude.
- The QT interval is normal or long.



Rate: 100–250 bpm

Rhythm: Regular or irregular

P Waves: None or not associated with the QRS

PR Interval: None

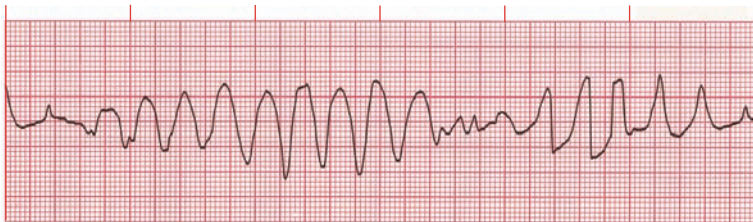
QRS: Wide (>0.10 sec), bizarre appearance

♥ **Clinical Tip:** It is important to confirm the presence or absence of pulses because polymorphic VT may be perfusing or nonperfusing.

♥ **Clinical Tip:** Consider electrolyte abnormalities as a possible etiology.

Torsade de Pointes

- The QRS reverses polarity and the strip shows a spindle effect.
- This rhythm is an unusual variant of polymorphic VT with normal or long QT intervals.
- In French the term means "twisting of the points."



Rate: 200–250 bpm

Rhythm: Irregular

P Waves: None

PR Interval: None

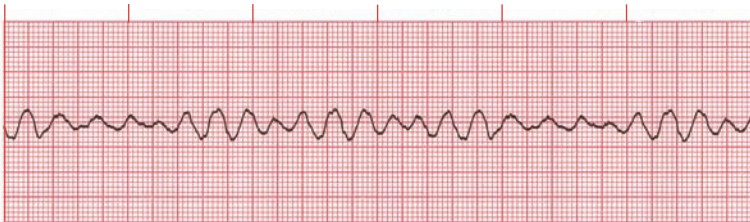QRS: Wide (>0.10 sec), bizarre appearance

♥ **Clinical Tip:** Torsade de pointes may deteriorate to VF or asystole.

♥ **Clinical Tip:** Frequent causes are drugs that prolong QT interval and electrolyte abnormalities such as hypomagnesemia.

Ventricular Fibrillation (VF)

- Chaotic electrical activity occurs with no ventricular depolarization or contraction.
- The amplitude and frequency of the fibrillatory activity can be used to define the type of fibrillation as coarse, medium, or fine.



Rate: Indeterminate

Rhythm: Chaotic

P Waves: None

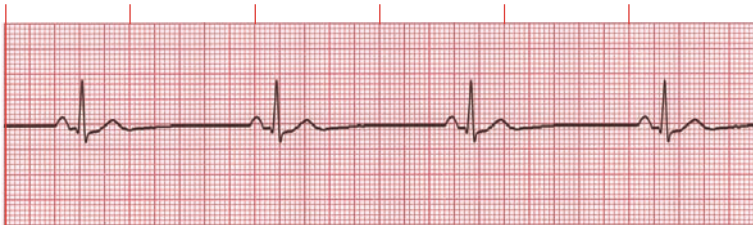
PR Interval: None

QRS: None

♥ **Clinical Tip:** There is no pulse or cardiac output. Rapid intervention is critical. The longer the delay, the less the chance of conversion.

Pulseless Electrical Activity (PEA)

- Monitor shows an identifiable electrical rhythm, but no pulse is detected.
- Rhythm may be sinus, atrial, junctional, or ventricular in origin.
- PEA is also called electromechanical dissociation (EMD).

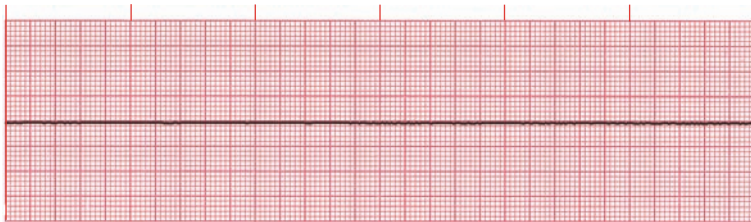

Rate, rhythm, P waves, P-R interval, and QRS: Reflect underlying rhythm.

♥ **Clinical Tip:** Potential causes of PEA are pulmonary embolism, MI, acidosis, tension pneumothorax, hyper- and hypokalemia, cardiac tamponade, hypovolemia, hypoxia, hypothermia, and drug overdose (i.e., cyclic antidepressants, beta blockers, calcium channel blockers, digoxin).

Asystole

- Electrical activity in the ventricles is completely absent.



Rate: None

Rhythm: None

P Waves: None

PR Interval: None

QRS: None

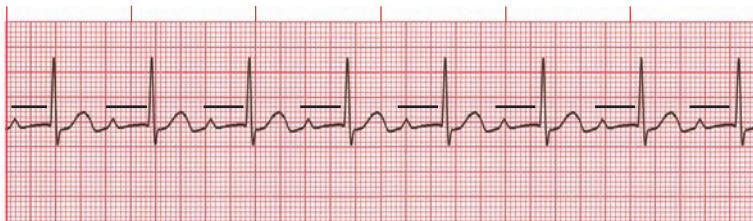♥ **Clinical Tip:** Always confirm asystole by checking the ECG in two different leads. Also, search to identify underlying ventricular fibrillation.

♥ **Clinical Tip:** Seek to identify the underlying cause as in PEA.

Atrioventricular (AV) Blocks

- AV blocks are divided into three categories: first-, second-, and third-degree.

First-Degree AV Block



60

Rate: Depends on rate of underlying rhythm

Rhythm: Regular

P Waves: Normal (upright and uniform)

PR Interval: Prolonged (>0.20 sec)

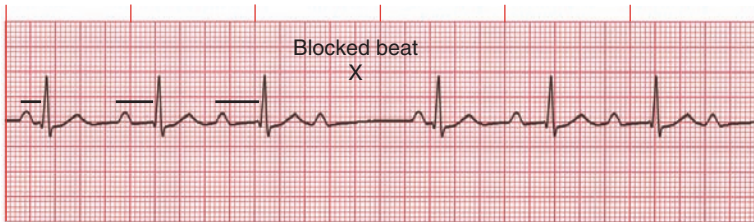
QRS: Normal (0.06–0.10 sec)

♥ **Clinical Tip:** Usually AV block is benign, but if associated with an acute MI, it may lead to further AV defects.

Second-Degree AV Block

Type I (Mobitz I or Wenckebach)

- P-R intervals become progressively longer until one P wave is totally blocked and produces no QRS. After a pause, during which the AV node recovers, this cycle is repeated.



Rate: Depends on rate of underlying rhythm

Rhythm: Irregular

P Waves: Normal (upright and uniform)

PR Interval: Progressively longer until one P wave is blocked and a QRS is dropped

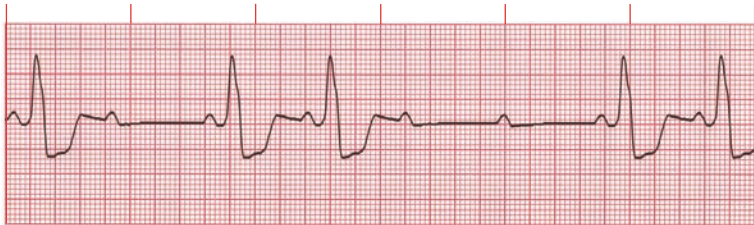QRS: Normal (0.06–0.10 sec)

♥ **Clinical Tip:** This rhythm may be caused by medication such as beta blockers, digoxin, and calcium channel blockers. Ischemia involving the right coronary artery is another cause.

Second-Degree AV Block

Type II (Mobitz II)

- Conduction ratio (P waves to QRS complexes) is commonly 2:1, 3:1, or 4:1.
- QRS complexes are usually wide because this block usually involves both bundle branches.



Rate: Atrial rate (usually 60–100 bpm); faster than ventricular rate

Rhythm: Atrial regular and ventricular irregular

P Waves: Normal (upright and uniform); more P waves than QRS complexes

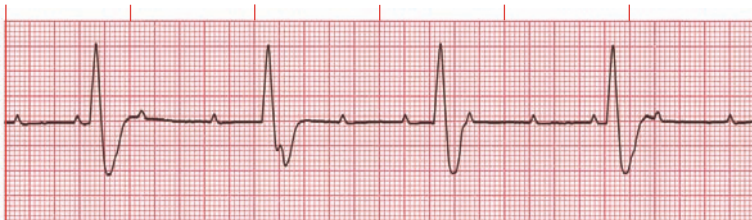
PR Interval: Normal or prolonged but constant

QRS: Usually wide (>0.10 sec)

♥ **Clinical Tip:** Resulting bradycardia can compromise cardiac output and lead to complete AV block. This rhythm often occurs with cardiac ischemia or an MI.

Third-Degree AV Block

- Conduction between atria and ventricles is absent because of electrical block at or below the AV node.
- "Complete heart block" is another name for this rhythm.



Rate: Atrial: 60–100 bpm; ventricular: 40–60 bpm if escape focus is junctional, <40 bpm if escape focus is ventricular

Rhythm: Usually regular, but atria and ventricles act independently

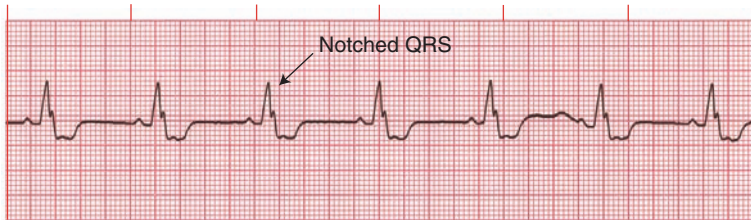
P Waves: Normal (upright and uniform); may be superimposed on QRS complexes or T waves

PR Interval: Varies greatly

QRS: Normal if ventricles are activated by junctional escape focus; wide if escape focus is ventricular

Bundle Branch Block (BBB)

- Either the left or the right ventricle may depolarize late, creating a “notched” QRS complex.



Rate: Depends on rate of underlying rhythm

Rhythm: Regular

P Waves: Normal (upright and uniform)

PR Interval: Normal (0.12–0.20 sec)

QRS: Usually wide (>0.10 sec) with a notched appearance

♥ **Clinical Tip:** Commonly, BBB occurs in coronary artery disease.

Artificial Cardiac Pacemakers

- Electronically stimulate the heart in place of the heart's own pacemaker.
- May be preset to stimulate the heart's activity continuously or intermittently.

Temporary Pacemaker

- Paces the heart through epicardial, transvenous, or transcutaneous routes. The pulse generator is located externally.

Permanent Pacemaker

- Its circuitry sealed in an airtight case, the pacemaker is implanted in the body. Uses sensing and pacing device leads.

Single-Chamber Pacemaker

- One lead is placed in the heart and paces a single heart chamber (either atrium or ventricle).

Dual-Chamber Pacemaker

- One lead is placed in the right atrium and the other in the right ventricle. The atrial electrode generates a spike that should be followed by a P wave, and the ventricular electrode generates a spike followed by a wide QRS complex.

Pacemaker Modes

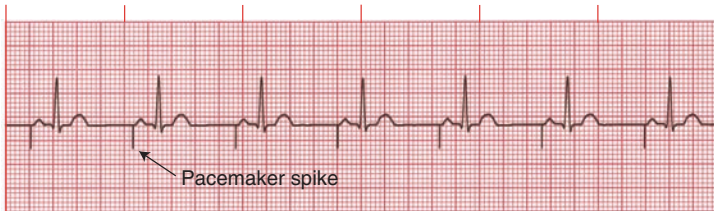
- Fixed rate (asynchronous): Discharges at a preset rate (usually 70–80 bpm) regardless of the patient's own electrical activity.
- Demand (synchronous): Discharges only when the patient's heart rate drops below the pacemaker's preset (base) rate.

♥ **Clinical Tip:** Pacemaker patients may receive defibrillation, but avoid placing the defibrillator paddles or pads closer than 5 inches from the pacemaker battery pack.

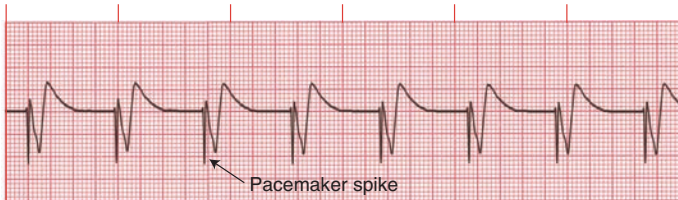
Artificial Pacemaker Rhythm

| | |
|---------------|--|
| Rate: | Varies according to preset pacemaker rate |
| Rhythm: | Regular for asynchronous pacemaker; irregular for demand pacemaker |
| P waves: | None produced by ventricular pacemaker. Sinus P waves may be seen but are unrelated to QRS. Atrial or dual-chamber pacemaker should have P waves following each atrial spike. |
| P-R interval: | None for ventricular pacer. Atrial or dual-chamber pacemaker produces ventricular spike at constant interval from P wave. |
| QRS: | Wide (>0.10 sec) following each ventricular spike in paced rhythm. Patient's own electrical activity may generate QRS that looks different from paced QRS complexes. If atrially paced only, may be within normal limits. |

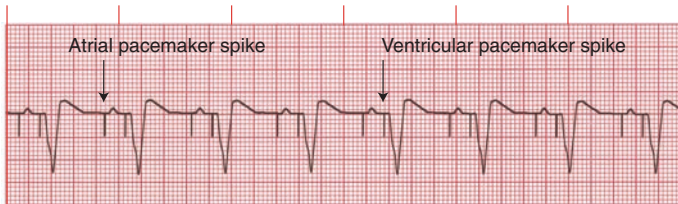
Single-Chamber Pacemaker Rhythm—Atrial



Single-Chamber Pacemaker Rhythm – Ventricular



Dual-Chamber Pacemaker Rhythm – Atrial and Ventricular



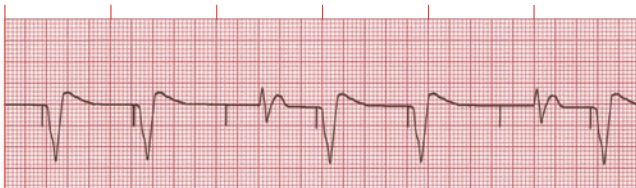Pacemaker Malfunctions

| Malfunction | Reason |
|--------------------|---|
| Failure to fire | Pacemaker spikes are absent. The cause may be a dead battery or a disruption in the connecting wires. |
| Failure to capture | Pacemaker spikes are present, but no P wave or QRS complex follows the spike. Turning up the pacemaker's voltage often corrects this problem. |
| Failure to sense | The pacemaker fires because it fails to detect the heart's intrinsic beats, resulting in abnormal complexes. The cause may be a dead battery, decrease of P wave or QRS voltage, or damage to a pacing lead wire. |

♥ **Clinical Tip:** A pacemaker spike—a mark on the ECG projecting upward or downward from the baseline—indicates that the pacemaker has fired.

♥ **Clinical Tip:** A pacemaker is said to be in capture when a spike produces an ECG wave or complex.

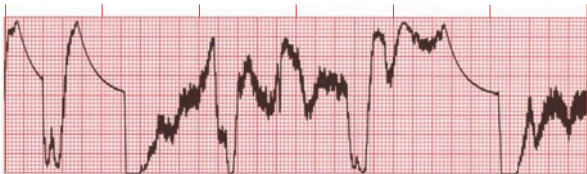
Pacemaker Failure to Sense



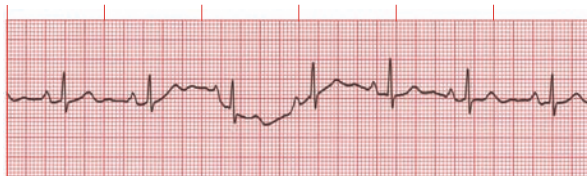Artifact

- Artifacts are ECG deflections caused by influences other than the heart's electrical activity.

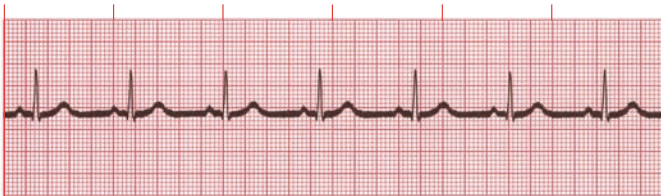
Loose Electrodes



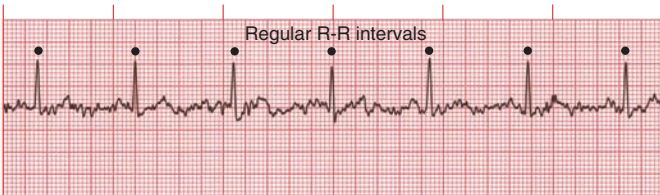
Baseline Varies with Respiration



60-Cycle Interference



Muscle Artifact



♥ **Clinical Tip:** Never confuse muscle artifact with A-fib if the rhythm is regular.

Notes:

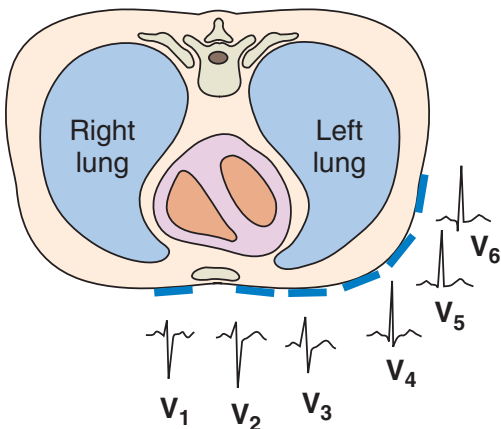
The 12-Lead ECG

- The most commonly used clinical ECG system is the 12-lead ECG. It consists of the following leads: I, II, III, aVR, aVL, aVF, V₁, V₂, V₃, V₄, V₅, and V₆. Both limb and chest electrodes are used to record 12-lead ECGs.
- Measurements are central to 12-lead ECG analysis. The height and depth of waves can be important in the diagnosis of certain conditions, including MI or ventricular hypertrophy.
- The direction of ventricular depolarization is an important factor in determining the axis of the heart.
- In the case of MI, multiple leads are necessary to recognize its presence and determine its location. If large areas of the heart are affected, the patient can develop cardiogenic shock.
- ECG signs of an MI are best seen in the reflecting leads—those facing the affected surface of the heart. Reciprocal leads are in the same plane but opposite the area of the MI; they show a “mirror image” of the electrical complex.
- Prehospital EMS systems may use 12-lead ECGs to discover signs of acute myocardial infarction, such as ST segment elevation, in preparation for in-hospital administration of thrombolytic drugs.
- Once a 12-lead ECG is performed, a 15-lead, or right-sided, ECG may be used for an even more comprehensive view if it appears that the right ventricle or posterior portion of the heart has been affected.

♥ **Clinical Tip:** Always compare the patient’s current 12-lead ECG with the previous one.

R Wave Progression

- Normal ventricular depolarization in the heart progresses from right to left and from front to back.
- In a normal heart the R wave becomes taller and the S wave becomes smaller as electrical activity moves across the heart from right to left. This phenomenon is called R wave progression.
- Alteration in the normal progression of the R wave may be seen in left ventricular hypertrophy, COPD, left bundle branch block, or anteroseptal MI.

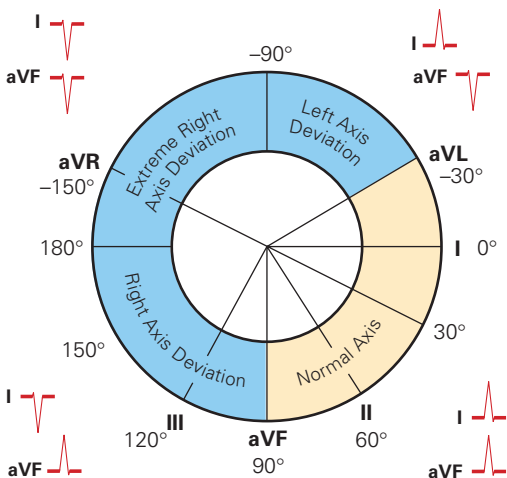


Normal R wave progression in chest leads V₁-V₆.

Electrical Axis of the Heart

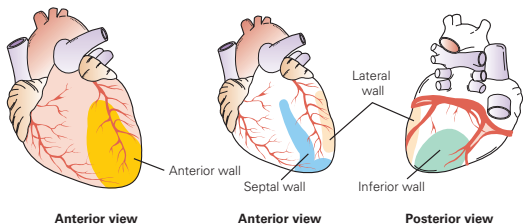
The electrical axis is the sum total of all electrical currents generated by the ventricular myocardium during depolarization. Analysis of the axis may help to determine the location and extent of cardiac injury, such as ventricular hypertrophy, bundle branch block, or changes in the position of the heart in the chest (from, e.g., pregnancy or ascites).

The direction of the QRS complex in leads I and aVF determines the axis quadrant in relation to the heart.



♥ **Clinical Tip:** Extreme right axis deviation is also called indeterminate, "no man's land," and "northwest."

Ischemia, Injury, or Infarction in Relation to the Heart



Location of MI by ECG Leads

| | | | |
|--------------|--------------|-------------------------|-------------------------|
| I lateral | aVR | V ₁ septal | V ₄ anterior |
| II inferior | aVL lateral | V ₂ septal | V ₅ lateral |
| III inferior | aVF inferior | V ₃ anterior | V ₆ lateral |

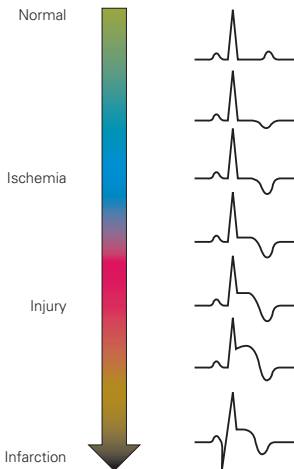
♥ **Clinical Tip:** Lead aVR is a nondiagnostic lead and does not show any change in an MI.

♥ **Clinical Tip:** An MI may not be limited to just one region of the heart. For example, if there are changes in leads V₃ and V₄ (anterior) and in I, aVL, V₅, and V₆ (lateral), the MI is called an anterolateral infarction.

Progression of an Acute Myocardial Infarction

An acute MI is a continuum that extends from the normal state to a full infarction:

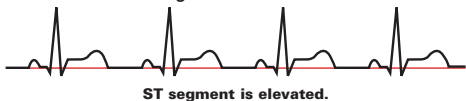

- Ischemia—Lack of oxygen to the cardiac tissue, represented by ST segment depression, T wave inversion, or both
- Injury—An arterial occlusion with ischemia, represented by ST segment elevation
- Infarction—Death of tissue, represented by a pathological Q wave



♥ **Clinical Tip:** Once the acute MI has ended, the ST segment returns to baseline and the T wave becomes upright, but the Q wave remains abnormal because of scar formation.

ST Segment Elevation and Depression

- A normal ST segment represents early ventricular repolarization.
- Displacement of the ST segment can be caused by various conditions listed below.



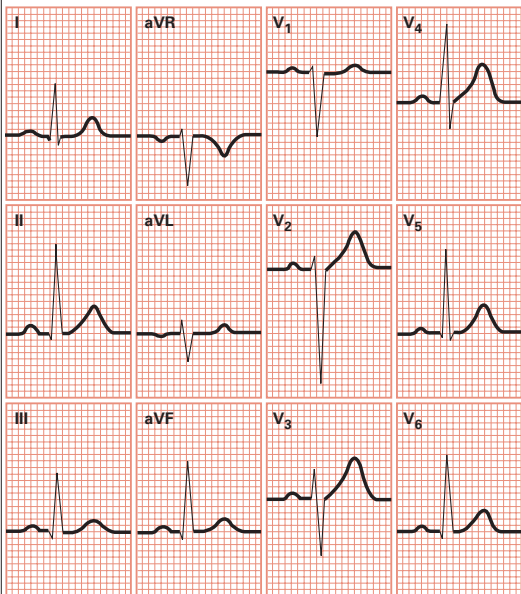
Primary Causes of ST Segment Elevation

- ST segment elevation >1 mm in the limb leads and >2 mm in the chest leads indicates an evolving acute MI until there is proof to the contrary. Other primary causes:
 - ◆ Early repolarization (normal variant in young adults)
 - ◆ Pericarditis
 - ◆ Ventricular aneurysm
 - ◆ Pulmonary embolism
 - ◆ Intracranial hemorrhage

Primary Causes of ST Segment Depression

- Myocardial ischemia
- Left ventricular hypertrophy
- Intraventricular conduction defects
- Medication (e.g., digitalis)
- Reciprocal changes in leads opposite the area of acute injury

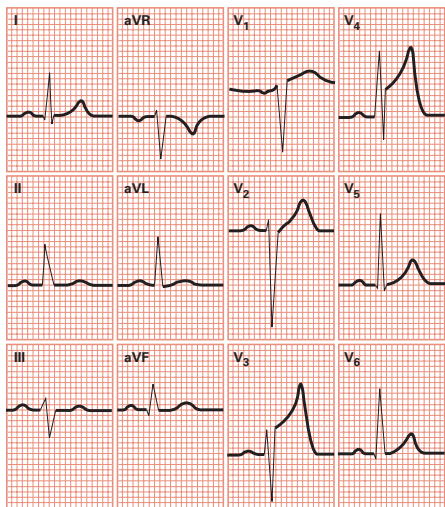
Normal 12-Lead ECG



♥ **Clinical Tip:** A normal ECG does not rule out any acute coronary syndrome.

Anterior Myocardial Infarction

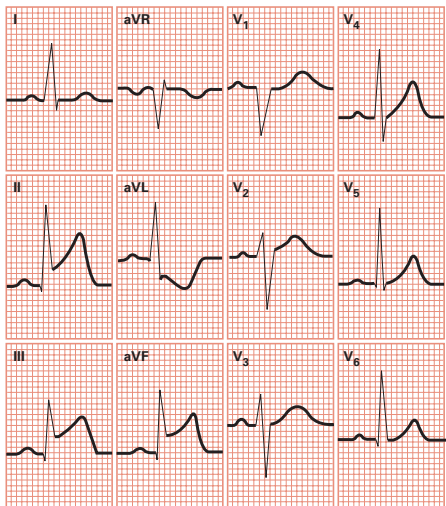
- Occlusion of the left coronary artery—left anterior descending branch
- ECG changes: ST segment elevation with tall T waves and taller-than-normal R waves in leads V₃ and V₄



♥ **Clinical Tip:** Anterior MI frequently involves a large area of the myocardium and can present with cardiogenic shock, second-degree AV block type II, or third-degree AV block.

Inferior Myocardial Infarction

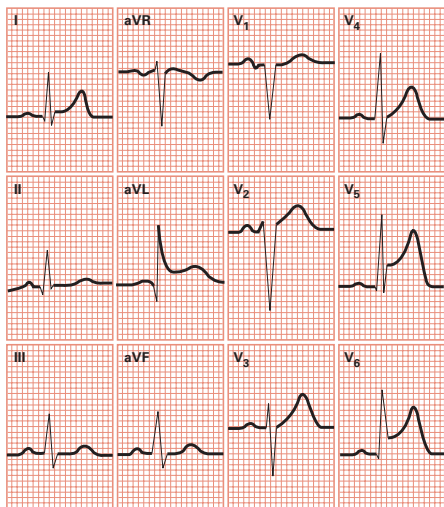
- Occlusion of the right coronary artery—posterior descending branch
- ECG changes: ST segment elevation in leads II, III, and aVF



♥ **Clinical Tip:** Be alert for symptomatic sinus bradycardia, AV blocks, hypotension, and hypoperfusion.

Lateral Myocardial Infarction

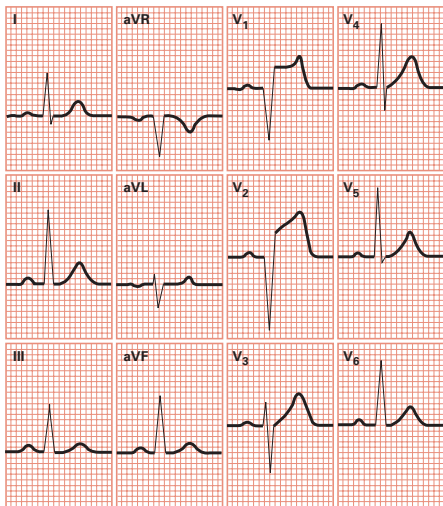
- Occlusion of the left coronary artery—circumflex branch
- ECG changes: ST segment elevation in leads I, aVL, V₅, and V₆



♥ **Clinical Tip:** Lateral MI is often associated with anterior or inferior wall MI. Be alert for changes that may indicate cardiogenic shock or congestive heart failure.

Septal Myocardial Infarction

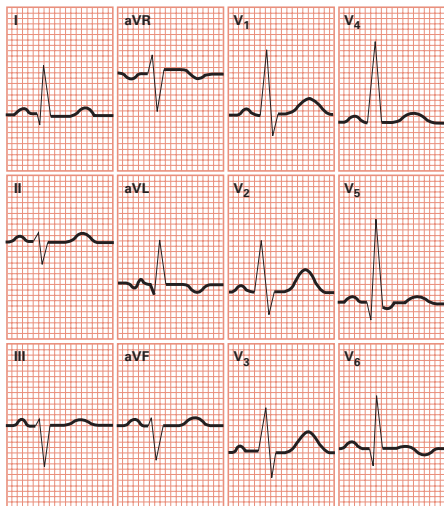
- Occlusion of the left coronary artery—left anterior descending branch
- ECG changes: pathological Q waves; absence of normal R waves in leads V₁ and V₂



♥ **Clinical Tip:** Septal MI is often associated with an anterior wall MI.

Posterior Myocardial Infarction

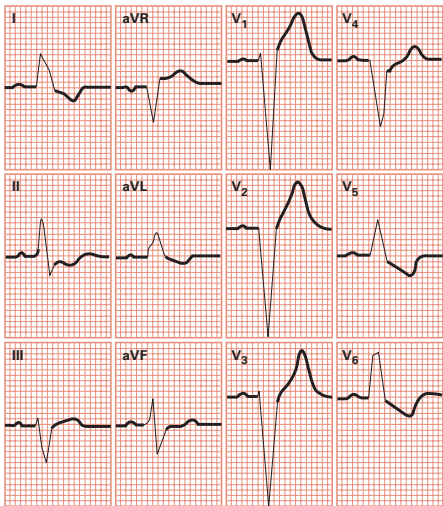
- Occlusion of the right coronary artery (posterior descending branch) or the left circumflex artery
- Tall R waves and ST segment depression possible in leads V₁, V₂, V₃, and V₄
- ST segment elevation in true posterior leads, V₈ and V₉



♥ **Clinical Tip:** Diagnosis may require a 15-lead ECG because a standard 12-lead does not look directly at the posterior wall.

Left Bundle Branch Block

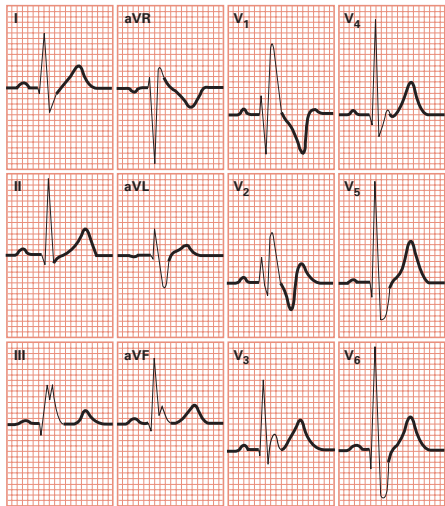
- QRS >0.10 sec
- QRS predominantly negative in leads V₁ and V₂
- QRS predominantly positive in V₅ and V₆ and often notched
- Absence of small, normal Q waves in I, aVL, V₅, and V₆
- Wide monophasic R waves in I, aVL, V₁, V₅, and V₆



♥ **Clinical Tip:** Patients may have underlying heart disease, including coronary artery disease, hypertension, cardiomyopathy, and ischemia.

Right Bundle Branch Block

- QRS >0.10 sec
- QRS normal or deviated to the right
- Slurred S wave in leads I and V_6
- RSR' pattern in lead V_1 with R' taller than R



♥ **Clinical Tip:** Patients may have underlying right ventricular hypertrophy, pulmonary edema, cardiomyopathy, congenital heart disease, or rheumatic heart disease.

Emergency Medications

This list is a reference list only. It is not meant to be exhaustive in clinical content.

♥ **Clinical Tip:** Always consult an authoritative, current reference about dose, dilution, route and rate of administration, and interactions before administering medications, especially IV medications. Have a second licensed person independently check dose calculations, preparation, original orders, and infusion pump programming.

ACE INHIBITORS (Angiotensin-converting Enzyme Inhibitors)
(Antihypertensive)

Common Agents: Captopril, enalapril, lisinopril, ramipril.

Indications: MI, hypertension (HTN), congestive heart failure (CHF), heart failure without hypotension, ST segment elevation, left ventricular dysfunction after MI.

Dose: See individual order and drug for route and dosage. Usually not started in emergency department, but within 24 hr after fibrinolytic therapy has been completed and blood pressure (BP) has stabilized.

Contraindications: Lactation, pregnancy, angioedema, hypersensitivity to ACE inhibitors, serum potassium >5 mEq/L.

Side Effects: Tachycardia, dizziness, headache, fatigue, hypotension, hyperkalemia.

Precautions: Reduce dose in renal failure.

ADENOSINE (Adenocard, Adenoscan) (Antiarrhythmic)

Indications: Narrow-complex tachycardias and PSVT.

Dose: 6 mg rapid intravenous push (IVP) over 1–3 sec followed by a 20-mL bolus of normal saline. Give 12 mg by IVP in 1–2 min if needed. A third dose of 12 mg IVP may be given in 1–2 min, max. 30 mg.

Contraindications: Hypersensitivity, sick sinus syndrome, 2nd- or 3rd-degree AV block (unless a functional artificial pacemaker is present), drug- or poison-induced tachycardia.

Side Effects: Flushing, dizziness, bronchospasm, chest pain or tightness, bradycardia, AV block, asystole, ventricular ectopic beats, VF.

Precautions: Ineffective in treating A-fib, A-flutter, or VT. Avoid in patients receiving dipyridamole and in patients with asthma or unstable angina.

AMIODARONE (Cordarone, Pacerone) (Antiarrhythmic)

Indications: Wide- and narrow-complex tachycardia, polymorphic VT, shock-refractory VF or pulseless VT, SVT, PSVT.

Dose: *Cardiac arrest* 300 mg (diluted in 20–30 mL D5W) IVP; consider additional 150 mg IVP in 3–5 min. *Wide- and narrow-complex tachycardia (stable)* 150 mg IVP over first 10 min (15 mg/min)—may repeat infusion of 150 mg IVP every 10 min as needed; slow infusion of 360 mg IV over next 6 hr (1 mg/min); maintenance infusion of 540 mg over next 18 hr (0.5 mg/min). Max. cumulative dose: 2.2 g IV in 24 hr.

Contraindications: Bradycardia, hypersensitivity, cardiogenic shock, 2nd- or 3rd-degree AV block.

Side Effects: Vasodilation, hypotension, visual impairment, hepatotoxicity, pulmonary toxicity, CHF; may prolong QT interval, producing torsade de pointes.

Precautions: Avoid concurrent use with procainamide. Correct hypokalemia and hypomagnesemia if possible before use. Draw up amiodarone through a large-gauge needle to reduce foaming. For slow or maintenance IV infusion, mix medication only in glass bottle containing D5W and administer through an in-line filter.

ASPIRIN (Acetylsalicylic Acid) (Antiplatelet)

Indications: Acute coronary syndrome, symptoms suggestive of cardiac ischemia.

Dose: 162–325 mg PO non-enteric coated for antiplatelet effect. Give within minutes of onset.

Contraindications: Known allergy to aspirin, pregnancy.

Side Effects: Anorexia, nausea, epigastric pain, anaphylaxis.

Precautions: Active ulcers and asthma, bleeding disorders, or thrombocytopenia.

ATROPINE (Antiarrhythmic, Anticholinergic)

Indications: Symptomatic sinus bradycardia, asystole, PEA with rate <60 bpm, cholinergic drug toxicity and mushroom poisoning (antidote).

Dose: *Cardiac arrest* 1 mg IVP every 3–5 min (may give through endotracheal (ET) tube at 2.0–3.0 mg diluted in 10 mL normal saline, max. 0.03–0.04 mg/kg. *Bradycardia* 0.5–1.0 mg IVP every 3–5 min, max. 0.03–0.04 mg/kg.

Contraindications: A-fib, A-flutter, glaucoma, asthma.

Side Effects: Tachycardia, headache, dry mouth, dilated pupils, VF or VT.

Precautions: Use caution in myocardial ischemia and hypoxia. Avoid in hypothermic bradycardia and in 2nd-degree (Mobitz type II) and 3rd-degree AV block.

BETA BLOCKERS (Antihypertensive)

Common Agents: Atenolol, esmolol, labetalol, metoprolol, propranolol.

Indications: MI, unstable angina, PSVT, A-fib, A-flutter, HTN.

Dose: See individual order and drug for route and dosage.

Contraindications: HR <60 bpm, systolic BP <100 mm Hg, 2nd- or 3rd-degree AV block, left ventricular failure.

Side Effects: Hypotension, dizziness, bradycardia, headache, nausea and vomiting.

Precautions: Concurrent use with calcium channel blockers, such as verapamil or diltiazem, can cause hypotension. Use caution in patients with a history of bronchospasm or cardiac failure.

CALCIUM CHLORIDE (Minerals/Electrolytes/Calcium Salt)

Indications: Hyperkalemia, hypocalcemia, hypermagnesemia; antidote to calcium channel blockers and beta blockers; given prophylactically with calcium channel blockers to prevent hypotension.

Dose: *Hyperkalemia and antidote to calcium channel blocker* 8–16 mg/kg (usually 5–10 mL) slow IVP, may be repeated as needed. *Given prophylactically prior to IV calcium channel blockers* 2–4 mg/kg (usually 2 mL) slow IVP.

Contraindications: Hypercalcemia, VF, digoxin toxicity, renal calculi.

Side effects: Bradycardia, asystole, hypotension, VF, nausea and vomiting.

Precautions: Incompatible with sodium bicarbonate.

DIGOXIN IMMUNE FAB (Fragment Antigen Binding) (Digibind)
(Antidote to Digoxin, Digitoxin)

Indications: Symptomatic digoxin toxicity or acute ingestion of unknown amount of digoxin.

Dose: Dependent on serum digoxin levels. One 40-mg vial binds to approximately 0.6 mg of digoxin. Dose typically administered over 30 min.

Contraindications: Allergy only, otherwise none known.

Side Effects: Worsening of CHF, A-fib, hypokalemia; increased serum digoxin levels.

Precautions: Allergies to sheep proteins or other sheep products.

DIGOXIN (Lanoxin) (Inotropic, Antiarrhythmic)

Indications: To slow ventricular response in A-fib or A-flutter, as a positive inotrope in CHF, pulmonary edema. May be used as an alternative drug for PSVT.

Dose: Loading dose of 10–15 $\mu\text{g}/\text{kg}$, administered over 5 min. Maintenance dose determined by body size and renal function.

Contraindications: Hypersensitivity, uncontrolled ventricular arrhythmias, AV block, idiopathic hypertrophic subaortic stenosis (IHSS), constrictive pericarditis.

Side Effects: Arrhythmias, particularly VF and AV block; bradycardia; fatigue; nausea and vomiting; blurred or yellow vision; headache; hypersensitivity; hypokalemia.

Precautions: Avoid electrical cardioversion of stable patients. If the patient's condition is unstable, use lower current settings such as 10–20 J. Use cautiously in elderly patients. Correct electrolyte abnormalities, monitor digoxin levels, monitor for clinical signs of toxicity.

DILTIAZEM (Cardizem) (Calcium Channel Blocker)

Indications: A-fib, A-flutter, PSVT refractory to adenosine with narrow QRS complex and adequate BP.

Dose: 15–20 mg (0.25 mg/kg) IVP over 2 min. May repeat in 15 min at 20–25 mg (0.35 mg/kg) IVP over 2 min. Start maintenance drip at 5–15 mg/hr and titrate to HR.

Contraindications: Drug- or poison-induced tachycardia, wide-complex tachycardia of uncertain origin, rapid A-fib and A-flutter with Wolff-Parkinson-White syndrome, sick sinus syndrome, 2nd- and 3rd-degree AV block (unless a functional artificial pacemaker is present).

Side Effects: Hypotension, bradycardia (including AV block), chest pain, ventricular arrhythmias.

Precautions: Severe hypotension in patients receiving beta blockers, hepatic injury, renal disease.

DOPAMINE (INTROPIN) (Vasopressor, Inotropic)

Indications: Symptomatic bradycardia and hypotension, cardiogenic shock.

Dose: Continuous infusions (titrate to patient response): Low dose 1–5 $\mu\text{g}/\text{kg}/\text{min}$; moderate dose 5–10 $\mu\text{g}/\text{kg}/\text{min}$ (cardiac doses); high dose 10–20 $\mu\text{g}/\text{kg}/\text{min}$ (vasopressor doses). Mix 400 mg/250 mL in normal saline, lactated Ringer's solution, or D5W (1600 $\mu\text{g}/\text{mL}$).

Contraindications: Pheochromocytoma, uncorrected tachycardia, cardiogenic shock with CHF.

Side Effects: Tachyarrhythmias, angina, hypotension, palpitations, vasoconstriction, dyspnea, nausea and vomiting.

Precautions: Hypovolemia, MI. Adjust dosage in elderly patients and in those with occlusive vascular disease. Ensure adequate hydration prior to infusion. Taper slowly. Do not mix with sodium bicarbonate. Use care with peripheral administration; infiltration can cause tissue necrosis. Central line is preferred.

EPINEPHRINE (Adrenalin) (Adrenergic Agonist)

Indications: Cardiac arrest: PEA, asystole, pulseless VT, VF; severe hypotension; symptomatic bradycardia; anaphylaxis; severe allergic reactions.

Dose: *Cardiac arrest* 1 mg IVP (10 mL of 1:10,000 solution) every 3–5 min; follow each dose with 20 mL IV flush; higher doses (up to 0.2 mg/kg) may be used if 1-mg dose fails. Give 2.0–2.5 mg diluted in 10 mL normal saline if administering by ET tube. For continuous infusion add 30 mg (30 mL of 1:1000 solution) to 250 mL normal saline or D5W, run at 100 mL/hr, and titrate to response. *Profound bradycardia or hypotension* 2–10 $\mu\text{g}/\text{min}$ IV (add 1 mg of 1:1000 solution to 500 mL normal saline or D5W and infuse at 1–5 mL/min). *Anaphylaxis/asthma* 0.1–0.5 mg SC or IM of 1:1000 solution every 5–15 min, may be followed by 1–4 $\mu\text{g}/\text{min}$ continuous infusion.

Contraindications: Hypersensitivity to adrenergic amines, hypovolemic shock, coronary insufficiency.

EPINEPHRINE (Continued)

Side Effects: Angina, HTN, tachycardia, VT, VF, nervousness, restlessness, tremors, weakness, headache, nausea.

Precautions: Use caution in HTN and increasing heart rate (may cause increased myocardial oxygen demand). Higher doses can contribute to postarrest cardiac impairment, but they may be required to treat poison- or drug-induced shock.

FIBRINOLYTIC AGENTS (Thrombolytic, Fibrinolytic)

Common Agents: Alteplase (**Activase, t-PA**), anistreplase (**Eminase**), reteplase (**Retavase**), streptokinase (**Streptase**), tenecteplase (**TNKase**).

Indications: Within <12 hr from onset of symptoms of acute MI. Alteplase is the only fibrinolytic agent approved for acute ischemic stroke and must be started <3 hr from onset of symptoms.

Dose: See individual order and drug for route and dosage.

Contraindications: Active internal bleeding within 21 days (except menses), neurovascular event within 3 months, major surgery or trauma within 2 weeks, aortic dissection, severe (uncontrolled) HTN, bleeding disorders, prolonged cardiopulmonary resuscitation (CPR), lumbar puncture within 1 week.

Side Effects: Hypotension, reperfusion, arrhythmias, heart failure, headache, increased bleeding time, deep or superficial hemorrhage, flushing, urticaria, anaphylaxis.

Precautions: Use cautiously in patients with severe renal or hepatic disease.

FUROSEMIDE (Lasix) (Diuretic, Loop Diuretics)

Indications: CHF with acute pulmonary edema, hypertensive crisis, postarrest cerebral edema, hepatic or renal disease.

Dose: 0.5–1.0 mg/kg slow IVP over 1–2 min, may repeat at 2 mg/kg slow IVP over 1–2 min.

Contraindications: Hypersensitivity (cross-sensitivity with thiazides and sulfonamides may occur), uncontrolled electrolyte imbalance, hepatic coma, anuria, hypovolemia.

Side Effects: Severe dehydration, hypovolemia, hypotension, hypokalemia, hyponatremia, hypochloremia, hyperglycemia, dizziness, ototoxicity.

Precautions: Use cautiously in severe liver disease accompanied by cirrhosis or ascites, electrolyte depletion, diabetes mellitus, pregnancy, lactation, risk for ototoxicity with increased dose or rapid injection. Monitor electrolytes closely.

IBUTILIDE (Corvert) (Antiarrhythmic)

Indications: SVT, including A-fib and A-flutter; most effective for conversion of A-fib or A-flutter of short duration.

Dose: *Patients* ≥ 60 kg 1 mg IVP over 10 min, may repeat same dose in 10 min. *Patients* < 60 kg 0.01 mg/kg IVP over 10 min, may repeat same dose in 10 min.

Contraindications: Known hypersensitivity, history of ventricular arrhythmias including torsade de pointes.

Side Effects: Headache, nausea and vomiting.

Precautions: Monitor ECG for 4–6 hr after administration, with defibrillator nearby. Correct electrolyte abnormalities prior to use. If A-fib > 48 hr, anticoagulation is required before cardioversion with ibutilide.

ISOPROTERENOL (Isuprel) (Sympathomimetic, Beta-Adrenergic Agonist)

Indications: Symptomatic bradycardia, refractory torsade de pointes unresponsive to magnesium, bradycardia in heart transplant patients, beta blocker poisoning.

Dose: IV infusion: mix 1 mg/250 mL in normal saline, lactated Ringer's solution, or D5W, run at 2–10 μ g/min, and titrate to patient response. In *torsade de pointes* titrate to increase heart rate until VT is suppressed.

ISOPROTERENOL (Continued)

Contraindications: Cardiac arrest, concurrent use with epinephrine (can cause VF or VT), poison- or drug-induced shock (*exception:* beta blocker poisoning).

Side Effects: Anxiety, tachycardia, palpitations, skin flushing.

Precautions: May increase myocardial ischemia, tachycardia, restlessness. High doses are harmful except in beta blocker overdose.

LIDOCAINE (Xylocaine) (Antiarrhythmic, Anesthetic)

Indications: VF or pulseless VT, stable VT, wide-complex tachycardia of uncertain origin, wide-complex PSVT.

Dose: *Cardiac arrest from VF or VT* 1.0–1.5 mg/kg IVP (or 2–4 mg/kg via ET tube), may repeat 0.5–0.75 mg/kg IVP every 5–10 min, max. 3 mg/kg. *Stable VT, wide-complex tachycardia of uncertain origin* use 0.5–0.75 mg/kg and up to 1.0–1.5 mg/kg, may repeat 0.5–0.75 mg/kg every 5–10 min; max. total dose 3.0 mg/kg. If conversion is successful, start an IV infusion of 1–4 mg/min (30–50 µg/kg/min) in normal saline or D5W.

Contraindications: Prophylactic use in acute MI, advanced AV block, hypotension, Wolff-Parkinson-White syndrome, hypersensitivity to amide-type local anesthetics.

Side Effects: Confusion, seizures, hypotension, bradycardia, cardiovascular collapse, respiratory arrest.

Precautions: CHF, respiratory depression, shock. Reduce maintenance dose (not loading dose) in presence of impaired liver function or left ventricular dysfunction or in the elderly. Stop infusion if signs of toxicity (prolonged PR interval, QRS widening, or CNS changes) develop.

MAGNESIUM SULFATE (Electrolyte, Antiarrhythmic)

Indications: Torsade de pointes, VF refractory to lidocaine, digoxin-induced VT/VF.

Dose: *Cardiac arrest (in hypomagnesemia or torsade de pointes)* 1–2 g (2–4 mL of a 50% solution) diluted in 10 mL of D5W IVP. *Digoxin-induced VT or VF* 1–2 g IVP. *Torsade de pointes (non-cardiac arrest)* load with 1–2 g mixed in 50–100 mL of D5W infused over 5–60 min IV, then infuse 0.5–1.0 g/hr IV (titrate to control torsade). *Acute MI* load with 1–2 g mixed in 50–100 mL of D5W over 5–60 min IV, then infuse 0.5–1.0 g/hr IV for up to 24 hr.

Contraindications: Hypermagnesemia, hypocalcemia, renal disease, AV block, toxemia of pregnancy 2 hr prior to delivery.

Side Effects: Hypotension, bradycardia, cardiac arrest, respiratory depression, altered level of consciousness (LOC), flushed skin, diaphoresis.

Precautions: Renal insufficiency, occasional fall in BP with rapid administration. Monitor serum magnesium levels.

MORPHINE (Opioid Agonist Analgesic)

Indications: Chest pain unrelieved by nitroglycerin, CHF and dyspnea associated with pulmonary edema.

Dose: 2–4 mg IVP (over 1–5 min) every 5–30 min.

Contraindications: Hypersensitivity, heart failure due to chronic lung disease, respiratory depression, hypotension.

Side Effects: Respiratory depression, hypotension, nausea and vomiting, bradycardia, altered LOC, seizures.

Precautions: Administer slowly and titrate to effect. Reverse with naloxone (0.4–2.0 mg IVP). Use caution in cerebral edema and pulmonary edema with compromised respiration.

NITROGLYCERIN (Nitrostat, Nitrolingual Pumpspray)
(Antianginal, Nitrate)

Indications: Angina, CHF associated with acute MI, hypertensive crisis.

Dose: Sublingual route, 0.3–0.4 mg (1 tablet), repeat every 5 min, max. 3 doses/15 min. Aerosol, spray for 0.5–1.0 sec at 5-min intervals (provides 0.4 mg/dose), max. 3 sprays/15 min. IVP at 12.5–25.0 μg (if no sublingual or spray used). IV infusion: mix 25 mg/250 mL (100 $\mu\text{g}/\text{mL}$) in D5W, run at 5–20 $\mu\text{g}/\text{min}$, and titrate to desired response.

Contraindications: Hypersensitivity, systolic BP <90 mm Hg; severe bradycardia or severe tachycardia; sildenafil (**Viagra**), tadalafil (**Cialis**), vardenafil (**Levitra**) within 24 hr; right ventricular infarction.

Side Effects: Hypotension with secondary tachycardia, syncope, headache, flushed skin.

Precautions: Do not mix with other medications; titrate IV to maintain systolic BP >90 mm Hg. Mix only in glass IV bottles and infuse only through tubing provided by manufacturer; standard polyvinyl chloride tubing can bind up to 80% of the medication, making it necessary to infuse higher doses.

OXYGEN (Gas)

Indications: Cardiopulmonary emergencies with shortness of breath and chest pain, cardiac or respiratory arrest.

Dose: Nasal cannula 1–6 L/min (24%–44% oxygen), Venturi mask 4–8 L/min (24%–40% oxygen), simple mask 5–8 L/min (40%–60% oxygen), partial rebreathing mask 6–15 L/min (35%–60% oxygen), nonrebreathing mask 6–15 L/min (60%–90% oxygen), bag-valve-mask 15 L/min (up to 100% oxygen).

Contraindications: Emphysema (deliver <35% oxygen unless severely hypoxic), hyperventilation.

Side Effects: Drying of respiratory mucosa, possible bronchospasm if oxygen is extremely cold and dry. Oxygen supports combustion and can fuel a fire.

Precautions: Respiratory arrest in patients with hypoxic drive. Patient needs an airway and adequate ventilation before oxygen is effective.

PROCAINAMIDE (Pronestyl) (Antiarrhythmic)

Indications: Recurrent VT or VF, PSVT refractory to adenosine and vagal stimulation, rapid A-fib with Wolff-Parkinson-White syndrome, stable wide-complex tachycardia of uncertain origin, maintenance after conversion.

Dose: 20 mg/min IV infusion or up to 50 mg/min under urgent conditions, max. 17 mg/kg loading dose. Maintenance IV infusion: mix 1 g/250 mL (4 mg/mL) in normal saline or D5W, run at 1–4 mg/min.

Contraindications: 2nd- and 3rd-degree AV block (unless a functioning artificial pacemaker is in place), torsade de pointes, hypersensitivity.

Side Effects: Hypotension, widening QRS, headache, nausea and vomiting, flushed skin, seizures, ventricular arrhythmias, AV block, cardiovascular collapse, arrest.

Precautions: Monitor BP every 2–3 min while administering procainamide. If QRS width increases by 50% or more, or if BP decreases to >90 systolic, stop drug. Reduce total dose to 12 mg/kg and maintenance infusion to 1–2 mg/min if cardiac or renal dysfunction is present. Use cautiously in myasthenia gravis and in hepatic or renal disease and with drugs that prolong QT interval (e.g., amiodarone, sotalol).

SODIUM BICARBONATE (Alkalizing Agent, Buffer)

Indications: Prolonged resuscitation with effective ventilation; hyperkalemia; diabetic ketoacidosis; cocaine toxicity; tricyclic antidepressant, diphenhydramine, or acetylsalicylic acid overdose; metabolic acidosis; shock associated with severe diarrhea.

Dose: 1 mEq/kg IVP, may repeat 0.5 mEq/kg every 10 min.

Contraindications: Metabolic and respiratory alkalosis, hypocalcemia, renal failure, peptic ulcer, hypertension, convulsions, hypercarbic acidosis.

Side Effects: Hypokalemia, metabolic alkalosis, seizures, tetany.

Precautions: CHF, renal disease, cirrhosis, toxemia, concurrent corticosteroid therapy. Not recommended for routine use in cardiac arrest patients because adequate ventilation and CPR are the major "buffer agents" in cardiac arrest. Incompatible with many drugs; flush line before and after administration.

VASOPRESSIN (Pitressin Synthetic) (Vasopressor, Hormone)

Indications: Vasodilatory (septic) shock, an alternative to epinephrine in shock-refractory VF and pulseless VT.

Dose: Cardiac arrest 40 units IVP single dose.

Contraindications: Seizures, heart failure, asthma, coronary artery disease (CAD), migraine, allergy to beef or pork protein, chronic renal failure with increased blood urea nitrogen (BUN).

Side Effects: Dizziness, headache, nausea and vomiting, MI, chest pain, abdominal cramps, diaphoresis, bronchoconstriction, anaphylaxis, coma, convulsions.

Precautions: Coronary artery disease (may precipitate angina or MI), renal impairment; potent peripheral vasoconstrictor.

VERAPAMIL (Calan, Isoptin) (Calcium Channel Blocker, Antiarrhythmic, Antihypertensive)

Indications: PSVT (with narrow QRS and adequate BP) refractory to adenosine, rapid ventricular rates in A-fib, A-flutter, or MAT.

Dose: 2.5–5.0 mg slow IVP over 2 min; may give second dose, if needed, of 5–10 mg IVP in 15–30 min, max. dose 20 mg. An alternative second dose is 5 mg IVP every 15 min, max. dose 30 mg.

Contraindications: A-fib with Wolff-Parkinson-White syndrome, wide-complex tachycardia of uncertain origin, 2nd- or 3rd-degree AV block (unless a functioning artificial pacemaker is in place), sick sinus syndrome, hypotension, severe CHF, cardiogenic shock.

Side Effects: Hypotension, exacerbation of CHF with left ventricular dysfunction, bradycardia, AV block.

Precautions: Concurrent oral beta blockers, CHF, impaired hepatic or renal function; may decrease myocardial contractility. In geriatric patients administer dose slowly over 3 min.

Emergency Medical Skills

DEFIBRILLATION

Indications: VF or pulseless VT.

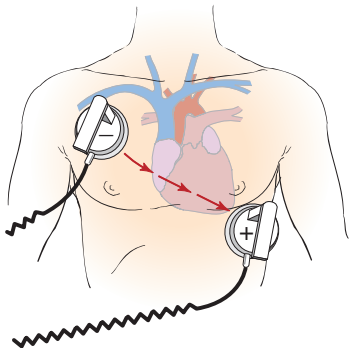
Energy Levels: *Adult monophasic energy levels* first shock 200 J, second shock 200–300 J, third shock 360 J; continue at 360 J for further shocks. *Biphasic energy level* shocks use lower energy levels, approximately 150 J.

Application: Use handheld paddles or remote adhesive pads. Always use a conducting gel with paddles and apply firm pressure to chest to ensure good skin contact. Dry skin if wet, shave excessive hair.

Methods: Manual or automated.

Precautions: Place paddles and pads several inches away from an implanted pacemaker.

♥ **Clinical Tip:** May be used on children aged 1–8 years. But always use pediatric paddles or pads and follow pediatric protocols.



MANUAL DEFIBRILLATION

A manual defibrillator is used to restore a normal heart rhythm. For a patient experiencing sudden cardiac arrest, first use the ECG tracing to verify that the rhythm is either VF or pulseless VT, and then manually deliver an electric shock to the heart.

Procedure

1. **Verify patient is in cardiac arrest**, with no pulse or respiration. Have someone provide CPR, if possible, while the defibrillator is obtained and placed next to the patient.
2. **Turn on defibrillator**; verify all cables are connected.
3. Turn "lead select" to "**paddles**" or "**defibrillator**."
4. **Select initial energy level** for an adult to 200 J.
5. **Paddles**: Use conducting gel and place on apex (lower left chest, midaxillary) and sternum (right of sternum, midclavicular).
Pads: Place in same locations as you would put paddles.
6. **Verify rhythm** as VF or pulseless VT.
7. Say, "**Charging defibrillator, stand clear!**"
8. **Charge defibrillator.**

9. **Say, "I'm going to shock on three.** One, I'm clear; two, you're clear; three, everybody's clear." Perform visual sweep to assure all rescue personnel are clear of patient, bed, and equipment.
10. **Discharge defibrillator,** reassess rhythm, and refer to appropriate treatment algorithm for resulting rhythm.

AUTOMATIC EXTERNAL DEFIBRILLATOR (AED)

An AED is a small, lightweight device used by both professionals and laypersons to assess heart rhythm by computer analysis. If necessary, it administers an electric shock to restore a normal rhythm in patients with sudden cardiac arrest. A shock is administered **only** if the rhythm detected is VF or VT.

Procedure

1. **Verify patient is in cardiac arrest,** with no pulse or respiration. Have someone provide CPR, if possible, while the AED is obtained and placed next to the patient.
2. **Turn on AED.** Follow voice prompts or visual messages.
3. Open adhesive pads and **attach pads to cables.**
4. **Attach pads to right sternal border and apex** or as pictured on each of the AED electrodes (see preceding manual defibrillation figure).
5. **Clear patient** and **stop CPR.**
6. **Press analyze button,** if present.
7. If shock is advised, say, **"I'm going to shock on three.** One, I'm clear; two, you're clear; three, everybody's clear." Perform visual sweep to ensure rescue personnel are not touching patient or equipment. **Press shock button.** Reanalyze after shock and continue as prompted by the AED.
8. **If no shock is advised, check for a pulse.** If no pulse, start CPR.

♥ **Clinical Tip:** Fully automatic AED analyzes the rhythm and delivers shock if indicated.

♥ **Clinical Tip:** Semiautomatic AED analyzes the rhythm and tells operator that shock is indicated. If it is indicated, operator initiates shock.

CARDIOVERSION (Synchronized)

Indications: Unstable tachycardia (altered LOC, dizziness, chest pain, hypotension).

Energy Levels: 100 J, 200 J, 300 J, 360 J.

Application: Use handheld paddles or remote adhesive pads. Always use a conducting gel with paddles. For conscious patients explain the procedure and use a medication for sedation. Consider 2.5–5.0 mg of midazolam (**Versed**) or 5 mg diazepam (**Valium**).

Methods: Place defibrillator in synchronized (sync) mode. Charge to appropriate level. Say, “**I’m going to shock on three.** One, I’m clear; two, you’re clear; three, everybody’s clear.” Perform visual sweep and press shock button. Reassess and treat according to appropriate algorithm.

Precautions: Reactivation of sync mode is required after each attempted cardioversion. Defibrillators default to unsynchronized mode. Place paddles and pads several inches away from an implanted pacemaker.

♥ **Clinical Tip:** Sync mode delivers energy just after the R wave to avoid stimulation during the refractory, or vulnerable, period.

TRANSCUTANEOUS PACING

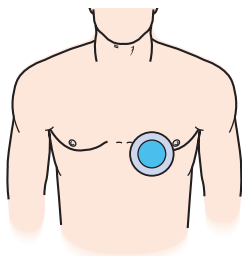
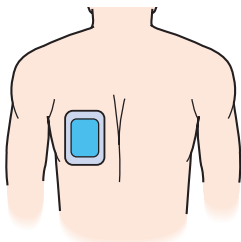
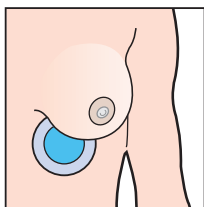
Indications: Symptomatic bradycardia unresponsive to atropine, bradycardia with ventricular escape rhythms, symptomatic 2nd-degree AV block type II, or 3rd-degree AV block.

Pacing Modes: *Demand mode (synchronous)* pacer senses the patient’s heart rate and paces only when the heart rate falls below the level set by the clinician. *Fixed mode (asynchronous)* pacer cannot sense the heart rate, and the pacer operates at the rate set by the clinician. Rate selection is 30–180 bpm. Output is adjustable 0–200 mA. Pulse duration varies from 20 to 40 ms.

Contraindications: Not effective in VF or pulseless VT.

Side Effects: Chest muscle contraction, burns, chest discomfort.

Precautions: Make sure pads have good skin contact to achieve capture and avoid burns.

**Anterior****Posterior**

Female patients:
Position electrode
under breast

Placement of anterior-posterior pacemaker pads.

PRECORDIAL THUMP

Indications: VF or pulseless VT; can cause depolarization and return the heart to an organized rhythm. Cardiac arrest must be witnessed.

Method: Sharply strike the midsternal area of the chest from a height of 10–12 inches with a fist. Recheck pulse and rhythm.

Contraindications: Should not be used in infants or children.

Side Effects: Fractured ribs or sternum.

Precautions: Position the fist (thumb side up) and arm parallel to the long axis of the sternum to avoid injuring adjacent ribs.

CAROTID SINUS MASSAGE (Vagal Maneuver)

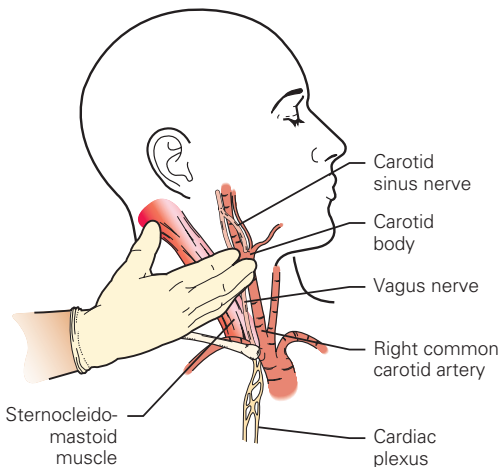
Indications: Can increase vagal nerve stimulation and slow SVT, or even convert SVT to NSR, without severe hemodynamic compromise.

Method: Supine position, head tilted to either side with neck hyperextended. Place index and middle fingers over the carotid artery below the angle of the jaw, as high on the neck as possible. Massage the artery for 5–10 sec by firmly pressing on it and rubbing.

Contraindications: Unequal carotid pulses, carotid bruits, cervical spine injury, or history of cerebrovascular accident (CVA) or carotid atherosclerosis.

Side Effects: Slow HR or AV block, PVCs, VT, VF, syncope, seizure, hypotension, nausea or vomiting, stroke.

Precautions: Be sure patient is receiving oxygen and an IV is in place. Never massage both arteries simultaneously.



Carotid sinus massage.

♥ **Clinical Tip:** Each carotid pulse should be palpated and auscultated before the procedure to maintain safety measures.

♥ **Clinical Tip:** Alternate vagal maneuvers include coughing, bearing down, holding breath.

CPR Skill Performance

| CPR Method | Compression/ Ventilation Ratio | Rate of Compressions (min) | Depth of Compressions (in.) | Pulse Check (artery) | Hand Position for Compressions |
|-----------------------|--------------------------------------|----------------------------------|-----------------------------------|----------------------------|---|
| Adult, 1 rescuer | 15:2 | 100 | 1 ¹ / ₂ -2 | Carotid | Heels of 2 hands over lower half of sternum |
| Adult, 2 rescuers | 15:2 | 100 | 1 ¹ / ₂ -2 | Carotid | Heels of 2 hands over lower half of sternum |
| Child, 1 rescuer | 5:1 | 100 | 1-1 ¹ / ₂ | Carotid | Heel of 1 hand over lower half of sternum |
| Child, 2 rescuers | 5:1 | 100 | 1-1 ¹ / ₂ | Carotid | Heel of 1 hand over lower half of sternum |
| Infant, 1 rescuer | 5:1 | ≥100 | ¹ / ₂ -1 | Brachial Femoral | 2 fingers over lower half of sternum |
| Infant, 2 rescuers | 5:1 | ≥100 | ¹ / ₂ -1 | Brachial Femoral | 2 fingers over lower half of sternum |
| Newborn | 3:1 | ≥120 | ¹ / ₃ | Brachial Femoral | 2 fingers over lower half of sternum |

CPR: Adult (older than 8 yr)

1. **Check for unresponsiveness.** Gently shake or tap person. Shout, "Are you OK?"
2. If no response, **call for an AED, summon help, call a code, or call 911.** Send second rescuer, if available, for help.
3. **Position person supine** on a hard, flat surface. Support head and neck, loosen clothing, and expose chest.
4. **Open airway** by the head tilt–chin lift method or, if spinal injury is suspected, use the jaw thrust method.
5. **Look, listen, and feel for breathing** for up to 10 sec.
6. If person is breathing, place in recovery position.
7. If person is not breathing, **begin rescue breaths.** Using a bag-valve-mask or face mask, give two slow breaths (2 sec each). Be sure that chest rises.
8. If the chest does not rise, reposition the head and the chin and jaw, and give two more breaths. **If chest still does not rise, follow instructions for unconscious adult with an obstructed airway (p 112).**
9. **Assess carotid pulse** for signs of circulation. If signs of circulation are present but person is still not breathing, continue to give rescue breaths at the rate of one every 5 sec.
10. If pulse and signs of circulation are not present, **begin compressions.** Place heel of your hand 2 finger-widths above xiphoid process; place heel of the second hand over the first. Keep elbows locked, lean shoulders over hands, and firmly compress chest $1\frac{1}{2}$ –2 inches. **Give 15 compressions.** Compress at a rate of 100 per min.
11. **Continue to give 2 breaths followed by 15 compressions.** After about 1 min (or at the 4th cycle of 15:2) **check pulse** and other signs of circulation. If circulation resumes but breathing does not or is inadequate, continue rescue breathing.
12. If breathing and circulation resume, place person in recovery position and monitor until help arrives.

♥ **Clinical Tip:** The compression rate is the speed of the compressions, not the actual number of compressions per min. Compressions, if uninterrupted, would equal 100/min.

CPR: Child (1–8 yr)

1. **Check for unresponsiveness.** Gently shake or tap child. Shout, “Are you OK?”
2. If no response send a second rescuer, if available, for help.
3. **Position child supine** on a hard, flat surface. Support head and neck, loosen clothing, and expose chest.
4. **Open airway** by the head tilt–chin lift method or, if spinal injury is suspected, use the jaw thrust method.
5. **Look, listen, and feel for breathing** for up to 10 sec.
6. If child is breathing, place in recovery position.
7. If child is not breathing, **begin rescue breaths.** Using a bag-valve-mask or face mask, give two slow breaths (1–1½ sec each). Be sure the chest rises.
8. If the chest does not rise, reposition the head and the chin and jaw and give two more breaths. **If chest still does not rise, follow instructions for unconscious child with an obstructed airway (p 113).**
9. Assess **carotid pulse** for signs of circulation. If signs of circulation are present but child is still not breathing, continue to give rescue breaths at the rate of one every 3 sec.
10. If pulse and signs of circulation are not present, **begin compressions.** Place heel of one hand 2 finger-widths above xiphoid process. Keep elbow locked, lean shoulders over hand, and firmly compress chest 1–1½ in. **Give 5 compressions.** Compress at a rate of 100 per min.
11. **Continue to give 1 breath followed by 5 compressions.** After about 1 min of CPR, **check pulse** and other signs of circulation. If rescuer is alone and no signs of circulation are present, **call for an AED, summon help, call a code, or call 911.** If circulation resumes but breathing does not or is inadequate, continue rescue breathing.
12. If breathing and circulation resume, place child in recovery position and monitor until help arrives.

♥ **Clinical Tip:** It is not always necessary to wait 1 min before calling for help if you are alone. If you know a child has had a cardiac arrest due to heart failure, request immediate help including a defibrillator.

CPR: Infant (under 1 yr)

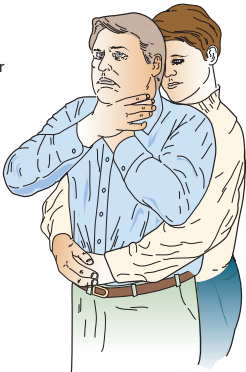1. **Check for unresponsiveness.** Gently rub infant's back or sternum. Never shake an infant.
2. If no response send a second rescuer, if available, for help.
3. **Position infant supine** on a hard, flat surface. Support head and neck, loosen clothing, and expose chest.
4. **Open airway** by the head tilt–chin lift method (do not overextend head or airway will become obstructed). If spinal injury is suspected, use jaw thrust method.
5. **Look, listen, and feel for breathing** for up to 10 sec.
6. If infant is breathing, place in recovery position.
7. If infant is not breathing, **begin rescue breaths.** Using a bag-valve-mask or face mask, give two slow breaths (1–1½ sec each). Be sure that chest rises.
8. If the chest does not rise, reposition the head and the chin and jaw and give two more breaths. **If chest still does not rise, follow instructions for unconscious infant with an obstructed airway (p 114).**
9. Assess **brachial or femoral pulse** for signs of circulation. If signs of circulation are present but infant is still not breathing, continue rescue breaths at the rate of one every 3 sec.
10. If pulse and signs of circulation are not present, **begin compressions.** Place two fingers of one hand 2 finger-widths above xiphoid process. Firmly compress chest ½–1 in. **Give five compressions.** Compress at a rate of ≥100 per min.
11. **Continue to give one breath followed by five compressions.** After about 1 min of CPR, **check pulse** and other signs of circulation. If rescuer is alone and no signs of circulation are present, **call for an AED, summon help, call a code, or call 911.** If circulation resumes but breathing does not or is inadequate, continue rescue breathing.
12. If breathing and circulation resume, place infant in recovery position and monitor until help arrives.

♥ **Clinical Tip:** Chest compressions must be adequate to produce a palpable pulse during resuscitation.

Obstructed Airway: Conscious Adult or Child (1 yr or older)

Signs and Symptoms

- Grabbing at the throat with one or both hands
 - Inability to speak; high-pitched crowing sounds
 - Wheezing, gagging, ineffective coughing
1. **Determine that airway is obstructed.** Ask, "Are you choking? Can you speak?"
 2. Let person know you are going to help.
 3. **Stand behind choking person and wrap your arms around his or her waist.** For someone who is obese or pregnant, wrap arms around chest.
 4. **Make a fist. Place thumb side of fist in middle of abdomen just above navel.** Locate middle of sternum for obese or pregnant persons.
 5. Grasp fist with your other hand.
 6. **Press fist abruptly into abdomen using an upward, inward thrust.** Use a straight thrust back for someone who is obese or pregnant.
 7. Continue thrusts until object is dislodged or person loses consciousness.
 8. If person loses consciousness, treat as unconscious adult or child with an obstructed airway (pp 112–113).

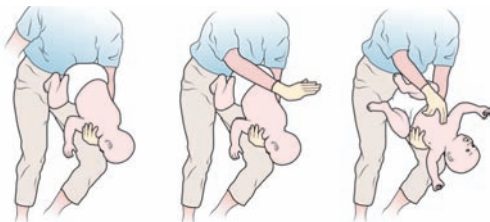

Heimlich maneuver for adult or child.

Obstructed Airway: Conscious Infant (younger than 1 yr)

Signs and Symptoms

- Inability to breathe or cry
 - High-pitched crowing sounds
 - Sudden wheezing or noisy breathing
1. **Determine that airway is obstructed.**
 2. Lay infant down on your forearm, with the chest in your hand and the jaw between your thumb and index finger.
 3. Using your thigh or lap for support, keep infant's head lower than his or her body.
 4. **Give five quick, forceful blows between shoulder blades** with your palm.
 5. Turn infant over to be face up on your other arm. Using your thigh or lap for support, keep infant's head lower than his or her body.
 6. Place two fingers on center of sternum just below nipple line.
 7. **Give five quick thrusts down, depressing chest** $\frac{1}{2}$ –1 in. each time.
 8. **Continue sequence of five back blows and five chest thrusts until object is dislodged or infant loses consciousness.** If infant loses consciousness, treat as unconscious infant with an obstructed airway (p 114).



Heimlich maneuver for infant.

Obstructed Airway: Unconscious Adult (older than 8 yr)

Signs and Symptoms

- Failure to breathe
 - Inability to move air into lungs with rescue breaths
 - Cyanosis
1. **Establish unresponsiveness.** Gently shake or tap person. Shout, "Are you OK?"
 2. If no response, **call for an AED, summon help, call a code, or call 911.** Send second rescuer, if available, for help.
 3. **Position person supine** on a hard, flat surface. Support head and neck, loosen clothing, and expose chest.
 4. **Open airway** by the head tilt–chin lift method or, if spinal injury is suspected, use the jaw thrust method.
 5. **Look, listen, and feel for breathing** for up to 10 sec.
 6. If person is not breathing, **begin rescue breaths.** If the chest does not rise, reposition the head and the chin and jaw, and attempt to ventilate.
 7. If ventilation is unsuccessful and chest still does not rise, **begin abdominal thrusts.** Straddle thighs or kneel to side for someone who is obese or pregnant. Place heel of hand in middle of abdomen just above umbilicus (middle of sternum if person is obese or pregnant).
 8. Place other hand on top of first hand and give **five quick thrusts inward** and upward.
 9. Open mouth by placing thumb over tongue and index finger under chin. **Perform a finger sweep to try to remove object.**
 10. Repeat steps 6 through 9 until rescue breaths are effective. Then continue steps for CPR.

♥ **Clinical Tip:** The most common cause of airway obstruction is the tongue.

Obstructed Airway: Unconscious Child (1–8 yr)

Signs and Symptoms

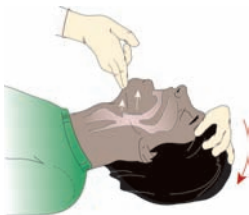- Failure to breathe
 - Inability to move air into lungs with rescue breaths
 - Cyanosis
1. **Check for unresponsiveness.** Gently shake or tap child. Shout, “Are you OK?”
 2. If no response send a second rescuer, if available, for help.
 3. **Position child supine** on a hard, flat surface. Support head and neck, loosen clothing, and expose chest.
 4. **Open airway** by the head tilt–chin lift method or, if spinal injury is suspected, use the jaw thrust method.
 5. **Look, listen, and feel for breathing** for up to 10 sec.
 6. If child is not breathing, **begin rescue breaths**. If the chest does not rise, reposition the head and the chin and jaw, and attempt to ventilate.
 7. If ventilation is unsuccessful and chest still does not rise, **begin abdominal thrusts**. Straddle child’s thighs. Place heel of hand in middle of abdomen just above umbilicus.
 8. Place other hand on top of first hand and give **five quick thrusts** inward and upward.
 9. Open child’s mouth by placing thumb over tongue and index finger under chin. **If object is visible and loose, perform a finger sweep and remove it. Do not perform a blind finger sweep.**
 10. If airway obstruction is not relieved after 1 min and rescuer is alone, **call for an AED, summon help, call a code, or call 911.**
 11. Repeat steps 6 through 9 until rescue breaths are effective. Then continue steps for CPR.

♥ **Clinical Tip:** Avoid compression of the xiphoid process.

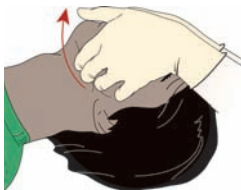Obstructed Airway: Unconscious Infant (younger than 1 yr)

Signs and Symptoms

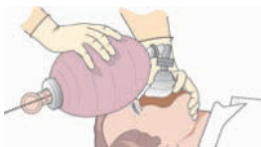- Inability to breathe, high-pitched noises
 - Inability to move air into lungs with rescue breaths
 - Cyanosis
1. **Check for unresponsiveness.** Gently rub infant's back or sternum. Never shake an infant.
 2. If no response send a second rescuer, if available, for help.
 3. **Position infant supine** on a hard, flat surface. Support head and neck, loosen clothing, and expose chest.
 4. **Open airway** by the head tilt–chin lift method, or, if spinal injury is suspected, use the jaw thrust method.
 5. **Look, listen, and feel for breathing** for up to 10 sec.
 6. If infant is not breathing, **begin rescue breaths.** If the chest does not rise, reposition the head and the chin and jaw, and attempt to ventilate.
 7. If ventilation is unsuccessful and chest still does not rise, **begin back blows.**
 8. Lay infant down on your forearm, with the chest in your hand and the jaw between your thumb and index finger.
 9. Using your thigh or lap for support, keep infant's head lower than his or her body. **Give five quick, forceful blows** between shoulder blades with your palm.
 10. Turn infant over to be face up on your other arm. Using your thigh or lap for support, keep infant's head lower than his or her body. Place two fingers on center of sternum just below nipple line. Give **five quick thrusts down, depressing chest** $\frac{1}{2}$ –1 in. each time.
 11. Open infant's mouth by placing thumb over tongue and index finger under chin. **If object is visible and loose, perform a finger sweep and remove it. Do not perform a blind finger sweep.**
 12. If airway obstruction is not relieved after 1 min and rescuer is alone, **call for an AED, summon help, call a code, or call 911.**
 13. Repeat steps 6 through 11 until rescue breaths are effective. Then continue steps for CPR.

CPR and Obstructed Airway Positions

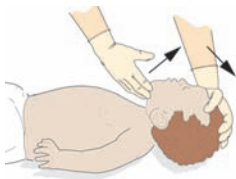
Head tilt–chin lift (adult or child).



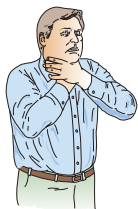Jaw thrust maneuver.



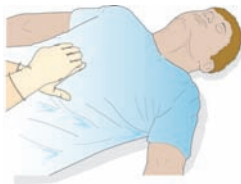Bag–valve–mask.



Head tilt–chin lift (infant).



Universal choking sign.



Abdominal thrusts.

Ventricular Fibrillation or Pulseless Ventricular Tachycardia

Signs and Symptoms

- Unresponsive state
- No respiration, pulse, or BP
 1. Establish unresponsiveness with no respiration or pulse.
 2. Deliver a precordial thump if cardiac arrest is witnessed and a defibrillator is not immediately available.
 3. Begin CPR with high-flow oxygen.
 4. Defibrillate at 200 J (or equivalent biphasic energy).
 5. Defibrillate at 200–300 J (or equivalent biphasic energy).
 6. Defibrillate at 360 J (or equivalent biphasic energy).
 7. Intubate and establish IV.
 8. Administer epinephrine 1 mg (10 mL of 1:10,000) IVP (follow with 20 mL IV flush), repeat every 3–5 min; give 2.0–2.5 mg diluted in 10 mL normal saline if administering via ET tube; or administer a single dose of vasopressin 40 U IVP.
 9. Defibrillate at 360 J (or equivalent biphasic energy) within 30–60 sec after each dose of medication. Pattern should be drug, shock; drug, shock. Consider the following antiarrhythmics for shock-refractory VF or VT:
 10. Administer amiodarone 300 mg (diluted in 20–30 mL D5W) IVP; or lidocaine 1.0–1.5 mg/kg IVP, 2–4 mg/kg by ET tube.
 11. Repeat initial antiarrhythmic for shock-refractory VF or VT: amiodarone 150 mg IVP; or lidocaine 0.5–0.75 mg/kg IVP, repeat lidocaine every 5–10 min, max. 3 mg/kg.
 12. Administer magnesium sulfate 1–2 g (2–4 mL of a 50% solution) diluted in 10 mL of D5W IVP in polymorphic VT, torsade de pointes, or suspected hypomagnesemia.
 13. If no response, consider procainamide 30–50 mg/min IV infusion, max. 17 mg/kg; or sodium bicarbonate 1 mEq/kg IVP, may repeat 0.5 mEq/kg every 10 min.

♥ **Clinical Tip:** Do not delay defibrillation.

♥ **Clinical Tip:** If vasopressin is used, wait 10–20 min before administering epinephrine.

Pulseless Electrical Activity

Signs and Symptoms

- Unresponsive state
- No respiration, pulse, or BP
- Identifiable electrical rhythm on monitor but no pulse
 1. Establish unresponsiveness with no respiration or pulse.
 2. Begin CPR with high-flow oxygen.
 3. Intubate and establish IV.
 4. Consider and treat possible causes: pulmonary embolism, MI, acidosis, tension pneumothorax, hyper- or hypokalemia, cardiac tamponade, hypovolemia, hypoxia, hypothermia, drug overdose (e.g., cyclic antidepressants, beta blockers, calcium channel blockers, digoxin).
 5. Administer epinephrine 1 mg (10 mL of 1:10,000) IVP, repeat every 3–5 min; give 2.0–2.5 mg diluted in 10 mL normal saline if administering by ET tube.
 6. Administer atropine 1 mg IVP if ECG rate is <60 bpm. Repeat every 3–5 min as needed to a total dose of 0.03–0.04 mg/kg. May be given by ET tube at 2–3 mg diluted in 10 mL normal saline.
 7. Consider fluid challenge of 500 mL normal saline, especially in suspected hypovolemia.
 8. If no response, consider sodium bicarbonate 1 mEq/kg IVP, may repeat 0.5 mEq/kg every 10 min.

♥ **Clinical Tip:** Sodium bicarbonate may be harmful in hypercarbic acidosis.

♥ **Clinical Tip:** Memory aid for causes of PEA:

| Five "H" Causes | Five "T" Causes |
|--------------------------|-------------------------|
| Hypothermia | Thrombosis (pulmonary) |
| Hyperkalemia/hypokalemia | Thrombosis (coronary) |
| Hydrogen ion (acidosis) | Tension pneumothorax |
| Hypoxia | Tamponade (cardiac) |
| Hypovolemia | Tablets (drug overdose) |

Asystole

Signs and Symptoms

- Unresponsive state
- No respiration, pulse, or BP
- ECG shows flat line; no electrical activity
 1. Establish unresponsiveness with no respiration or pulse.
 2. Begin CPR with high-flow oxygen.
 3. Intubate and establish IV.
 4. Consider and treat possible causes: pulmonary embolism, MI, acidosis, tension pneumothorax, hyper- or hypokalemia, cardiac tamponade, hypovolemia, hypoxia, hypothermia, drug overdose (e.g., cyclic antidepressants, beta blockers, calcium channel blockers, digoxin).
 5. If condition remains unchanged, begin immediate transcutaneous pacing if equipment is available.
 6. Administer epinephrine 1 mg (10 mL of 1:10,000) IVP, repeat every 3–5 min; give 2.0–2.5 mg diluted in 10 mL normal saline if administering by ET tube.
 7. Administer atropine 1 mg IVP, repeat every 3–5 min as needed, to a total dose of 0.03–0.04 mg/kg. May be given by ET tube at 2–3 mg diluted in 10 mL normal saline.
 8. If no response, consider sodium bicarbonate 1 mEq/kg IVP, may repeat 0.5 mEq/kg every 10 min.
 9. If asystole persists, consider quality of resuscitation, identification of reversible causes, and support for termination protocols.

♥ **Clinical Tip:** Do not delay transcutaneous pacing; it takes priority over medication.

♥ **Clinical Tip:** Always confirm asystole by checking the ECG in two different leads. Also, search to identify underlying VF.

♥ **Clinical Tip:** Study local policy to learn established criteria for stopping resuscitation efforts.

Ischemic Chest Pain

Signs and Symptoms

- History of acute MI or angina
- Chest pain or discomfort
- Pain spreading to neck, shoulders, arms, or jaw
- Nausea, diaphoresis, shortness of breath
 1. Establish responsiveness.
 2. Measure vital signs, including oxygen saturation.
 3. Supply oxygen, begin cardiac monitoring, start IV, and obtain 12-lead ECG.
 4. Administer aspirin 162–325 mg.
 5. Administer nitroglycerin by sublingual route 0.3–0.4 mg (1 tablet), repeat every 5 min, max. 3 doses/15 min; or administer aerosol spray for 0.5–1.0 sec at 5-min intervals (provides 0.4 mg per dose).
 6. Nitroglycerin administration requires BP >100 mm Hg systolic.
 7. Repeat nitroglycerin (see step 5) until chest pain is relieved, systolic BP falls below 100 mm Hg, or signs of ischemia or infarction are resolved.
 8. If chest pain is not relieved by nitroglycerin, administer morphine 2–4 mg IVP (over 1–5 min) every 5–30 min. Do not administer morphine if systolic BP is <100 mm Hg.

♥ **Clinical Tip:** Patients should not be given nitroglycerin if they have taken sildenafil (**Viagra**), tadalafil (**Cialis**), or vardenafil (**Levitra**) in the last 24 hr. The use of nitroglycerin with these medications may cause irreversible hypotension.

♥ **Clinical Tip:** Diabetic patients and women frequently present with atypical symptoms (e.g., weakness, fatigue, complaints of indigestion).

Bradycardia

Signs and Symptoms

- Pulse rate <60 bpm
- AV block
- Hypotension, altered mental status, pulmonary edema, shock
 1. Establish responsiveness.
 2. Measure vital signs, including oxygen saturation.
 3. Supply oxygen, begin cardiac monitoring, and start IV.
 4. In 2nd-degree (Mobitz type II) or 3rd-degree AV block, proceed directly to step 5, transcutaneous pacing; otherwise administer atropine 0.5–1.0 mg IVP every 3–5 min, max. 0.03–0.04 mg/kg.
 5. If patient remains symptomatic or has 2nd-degree (Mobitz type II) or 3rd-degree AV block, sedate patient and begin transcutaneous pacing, if available.
 6. If no response, consider dopamine with continuous infusions (titrate to patient response) of 5–20 $\mu\text{g}/\text{kg}/\text{min}$. Mix 400 mg/250 mL in normal saline, lactated Ringer's solution, or D5W.
 7. If patient is still hypotensive with severe bradycardia, consider epinephrine infusion, 2–10 $\mu\text{g}/\text{min}$ IV (add 1 mg of 1:1000 to 500 mL normal saline and infuse at 1–5 mL/min).
 8. If still no response, consider isoproterenol, IV infusion: mix 1 mg in 250 mL normal saline, lactated Ringer's solution, or D5W with rate of 2–10 $\mu\text{g}/\text{min}$, titrate to patient response.

♥ **Clinical Tip:** If patient is symptomatic, do not delay transcutaneous pacing while waiting for atropine to take effect or for IV access.

♥ **Clinical Tip:** Use atropine with caution in a suspected acute MI; atropine may induce rate-related ischemia.

♥ **Clinical Tip:** If patient is asymptomatic but has 2nd-degree (Mobitz type II) or 3rd-degree AV block, use transcutaneous pacemaker until transvenous pacer is placed.

Tachycardia – Unstable

Signs and Symptoms

- Altered level of consciousness
- Chest pain or discomfort, palpitations
- Shortness of breath, diaphoresis
- Hypotension, pulmonary edema, crackles, rhonchi, jugular vein distention, peripheral edema
 1. Establish responsiveness.
 2. Measure vital signs, including oxygen saturation.
 3. Supply oxygen, begin cardiac monitoring, and start IV.
 4. Establish that serious signs and symptoms are related to the tachycardia.
 5. If ventricular rate is >150 bpm, prepare for immediate synchronized cardioversion.
 6. Premedicate with a sedative plus an analgesic whenever possible.
 7. Administer synchronized cardioversion at 100 J (or equivalent biphasic energy).
 8. If no response, administer synchronized cardioversion at 200 J (or equivalent biphasic energy).
 9. If no response, administer synchronized cardioversion at 300 J (or equivalent biphasic energy).
 10. If no response, administer synchronized cardioversion at 360 J (or equivalent biphasic energy).
 11. If the unstable tachycardia converts to VF or pulseless VT, treat with immediate defibrillation and follow algorithm for VF and pulseless VT.

♥ **Clinical Tip:** Reactivate sync mode before next attempted cardioversion.

♥ **Clinical Tip:** If a tachycardia is VT or torsade de pointes, it may rapidly deteriorate to VF.

♥ **Clinical Tip:** A-flutter and PSVT may respond to lower energy levels such as 50 J (or equivalent biphasic energy).

Wide-Complex Tachycardia — Stable**Monomorphic VT**

1. Establish responsiveness.
2. Measure vital signs, including oxygen saturation.
3. Supply oxygen, begin cardiac monitoring, and start IV.
4. May go directly to step 8, cardioversion.

For Impaired Cardiac Function

5. Administer amiodarone 150 mg IVP over 10 min (15 mg/min), may repeat infusion of 150 mg IVP every 10 min as needed; or administer lidocaine 0.5–0.75 mg/kg IVP (may use up to 1.0–1.5 mg/kg), repeat 0.5–0.75 mg/kg IVP every 5–10 min, max. 3 mg/kg.
6. If rhythm converts to sinus rhythm, begin infusion of rhythm-converting agent: amiodarone, slow infusion of 360 mg IV over the next 6 hr (1 mg/min) with maintenance infusion of 540 mg over the next 18 hr (0.5 mg/min); or start lidocaine infusion of 1–4 mg/min (30–50 μ g/kg/min).
7. If rhythm does not convert, prepare for immediate cardioversion.
8. Premedicate with sedative plus analgesic agent whenever possible.
9. Administer synchronized cardioversion incrementally at 100 J, 200 J, 300 J, then 360 J (or equivalent biphasic energy).

For Normal Cardiac Function

5. Follow steps 1–4 above.
6. Otherwise, consider procainamide or sotalol.
7. Other acceptable medication is amiodarone or lidocaine.

Notes:

Wide-Complex Tachycardia – Stable

Polymorphic VT

1. Establish responsiveness.
2. Measure vital signs, including oxygen saturation.
3. Supply oxygen, begin cardiac monitoring, and start IV.
4. May go directly to step 8, cardioversion.

For Impaired Cardiac Function

5. Administer amiodarone 150 mg IVP over first 10 min (15 mg/min), may repeat infusion of 150 mg IVP every 10 min as needed; or administer lidocaine 0.5–0.75 mg/kg IVP (may use up to 1.0–1.5 mg/kg), repeat 0.5–0.75 mg/kg IVP every 5–10 min, max. 3 mg/kg.
6. If rhythm converts to sinus rhythm, begin infusion of rhythm-converting agent: amiodarone, slow infusion of 360 mg IV over the next 6 hr (1 mg/min) with maintenance infusion of 540 mg over the next 18 hr (0.5 mg/min); or start lidocaine infusion of 1–4 mg/min (30–50 μ g/kg/min).
7. If rhythm does not convert, prepare for immediate cardioversion.
8. Premedicate with sedative plus analgesic agent whenever possible.
9. Administer synchronized cardioversion incrementally at 100 J, 200 J, 300 J, then 360 J (or equivalent biphasic energy).

For Normal Cardiac Function

If possible, measure QT interval before onset of VT; it cannot be obtained in sustained VT. Torsade de pointes is an example of polymorphic VT with an abnormally prolonged QT interval.

| Normal QT Interval | Prolonged QT Interval |
|---|--|
| Correct electrolytes | Correct electrolytes |
| Treat ischemia | Treat ischemia |
| Consider (any one): beta blockers, lidocaine, amiodarone, procainamide, or sotalol. | Consider (any one): magnesium, overdrive pacing, isoproterenol, phenytoin, or lidocaine. |

Narrow-Complex Tachycardia—Stable

Paroxysmal Supraventricular Tachycardia

Signs and Symptoms

- If present, hypotension, syncope, or limited ability to exercise
- Patient may be asymptomatic.
 1. Establish responsiveness.
 2. Measure vital signs, including oxygen saturation.
 3. Supply oxygen, begin cardiac monitoring, and start IV.
 4. Attempt vagal maneuvers (e.g., carotid sinus massage, Valsalva maneuver).
 5. If rhythm has not converted to sinus rhythm, administer adenosine 6 mg rapid IVP over 1–3 sec followed by a 20-mL bolus of normal saline.
 6. If rhythm still has not converted, repeat adenosine 12 mg IVP in 1–2 min. A third dose of 12 mg IVP may be given after another 1–2 min, max. 30 mg.

For Impaired Cardiac Function

7. If still no response and patient has serious signs and symptoms with ventricular rate >150 bpm, prepare for immediate cardioversion.
8. Premedicate with sedative plus analgesic agent whenever possible.
9. Administer synchronized cardioversion incrementally at 100 J, 200 J, 300 J, then 360 J (or equivalent biphasic energy).
10. If rhythm still has not converted, consider digoxin, amiodarone, or diltiazem.

For Normal Cardiac Function

7. Follow steps 1–6 above.
8. Consider in order of priority an AV blocker (beta blocker, calcium channel blocker, digoxin), cardioversion, and an antiarrhythmic (procainamide, amiodarone, sotalol).

Narrow-Complex Tachycardia – Stable**Junctional Tachycardia**

1. Establish responsiveness.
2. Measure vital signs, including oxygen saturation.
3. Supply oxygen, begin cardiac monitoring, and start IV.
4. Attempt vagal maneuvers (e.g., carotid sinus massage, Valsalva maneuver).
5. If rhythm has not converted to sinus rhythm, administer adenosine 6 mg rapid IVP over 1–3 sec followed by a 20-mL bolus of normal saline.
6. If rhythm still has not converted, repeat adenosine 12 mg IVP in 1–2 min. A third dose of 12 mg IVP may be given after another 1–2 min, max. 30 mg.

For Impaired Cardiac Function

7. If still no response consider amiodarone, 150 mg IVP over 10 min (15 mg/min), may repeat infusion of 150 mg IVP every 10 min as needed.
8. Do not attempt cardioversion.

For Normal Cardiac Function

7. Follow steps 1–6 above.
8. Consider a beta blocker, calcium channel blocker, or amiodarone.
9. Do not attempt cardioversion.

♥ **Clinical Tip:** Avoid carotid massage in patients at risk for carotid atherosclerosis.

Notes:

| |
|--|
| |
| |
| |
| |

Narrow-Complex Tachycardia – Stable**Ectopic or Multifocal Atrial Tachycardia**

1. Establish responsiveness.
2. Measure vital signs, including oxygen saturation.
3. Supply oxygen, begin cardiac monitoring, and start IV.
4. Attempt vagal maneuvers (e.g., carotid sinus massage, Valsalva maneuver).
5. If rhythm has not converted to sinus rhythm, administer adenosine 6 mg rapid IVP over 1–3 sec followed by a 20-mL bolus of normal saline.
6. If rhythm still has not converted, repeat adenosine 12 mg IVP in 1–2 min. A third dose of 12 mg IVP may be given after another 1–2 min, max. 30 mg.

For Impaired Cardiac Function

7. If still no response, consider amiodarone 150 mg IVP over 10 min (15 mg/min), may repeat infusion of 150 mg IVP every 10 min as needed.
8. Consider diltiazem 15–20 mg (0.25 mg/kg) IVP over 2 min. May repeat in 15 min at 20–25 mg (0.35 mg/kg) IVP over 2 min. Start maintenance drip at 5–15 mg/hr and titrate to HR.
9. Do not attempt cardioversion.

For Normal Cardiac Function

7. Follow steps 1–6 above.
8. Consider a beta blocker, calcium channel blocker, or amiodarone.
9. Do not attempt cardioversion.

Notes:

| |
|--|
| |
| |
| |
| |
| |

Narrow-Complex Tachycardia – Stable

Atrial Fibrillation or Atrial Flutter

1. Establish responsiveness.
2. Measure vital signs, including oxygen saturation.
3. Supply oxygen, begin cardiac monitoring, and start IV.
4. If rate or rhythm has not converted, proceed to the following tables:

Agents Used in Normal Cardiac Function

| Duration \leq 48 hr | Duration $>$ 48 hr |
|---|--|
| To control rate | To control rate |
| Diltiazem (or another calcium channel blocker) or metoprolol (or another beta blocker) | Diltiazem (or another calcium channel blocker) or metoprolol (or another beta blocker) |
| To convert rhythm | To convert rhythm |
| Recommended: cardioversion Or consider: procainamide, amiodarone, ibutilide, flecainide, propafenone | Urgent cardioversion ($<$ 24 hr): IV heparin, transesophageal echocardiography to exclude atrial clot, cardioversion (within 24 hr), then anticoagulation (4 wk); or delayed cardioversion ($>$ 3 wk): anticoagulation (3 wk), then cardioversion, then anticoagulation (4 wk) |

Agents Used in Impaired Cardiac Function

| Duration \leq 48 hr | Duration $>$ 48 hr |
|---|---|
| To control rate | To control rate |
| Diltiazem, digoxin, or amiodarone | Diltiazem, digoxin, or amiodarone |
| To convert rhythm | To convert rhythm |
| Recommended: cardioversion Or consider: amiodarone | Urgent cardioversion ($<$ 24 hr): IV heparin , transesophageal echocardiography to exclude atrial clot, cardioversion (within 24 hr), then anticoagulation (4 wk); or delayed cardioversion ($>$ 3 wk): anticoagulation (3 wk), then cardioversion, then anticoagulation (4 wk) |

Narrow-Complex Tachycardia – Stable

Atrial Fibrillation or Atrial Flutter with Wolff-Parkinson-White Syndrome

1. Establish responsiveness.
2. Measure vital signs, including oxygen saturation.
3. Supply oxygen, begin cardiac monitoring, and start IV.
4. If rate or rhythm has not converted, proceed to the following tables:

To Control Rate and Rhythm

Agents Used in Normal Cardiac Function

| Duration \leq 48 hr | Duration $>$ 48 hr |
|---|--|
| Recommended: cardioversion Or consider: amiodarone, procainamide, flecainide, pro- prafenone, sotalol | Urgent cardioversion ($<$ 24 hr): IV heparin, transesophageal echocardiography to exclude atrial clot, cardioversion (within 24 hr), then anticoagulation (4 wk); or delayed cardioversion ($>$ 3 wk): anticoagulation (3 wk), then cardioversion, then anticoagulation (4 wk) |

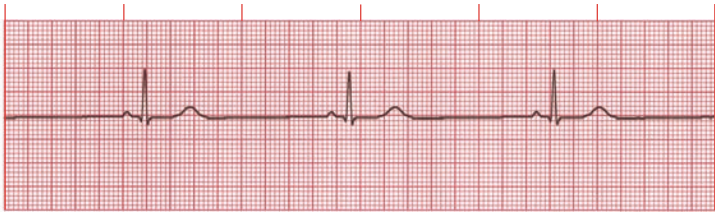
Agents Used in Impaired Cardiac Function

| Duration \leq 48 hr | Duration $>$ 48 hr |
|---|--|
| Recommended: cardioversion Or consider: amiodarone | Urgent cardioversion ($<$ 24 hr): IV heparin, transesophageal echocardiography to exclude atrial clot, cardioversion (within 24 hr), then anticoagulation (4 wk); or delayed cardioversion ($>$ 3 wk): anticoagulation (3 wk), then cardioversion, then anticoagulation (4 wk) |

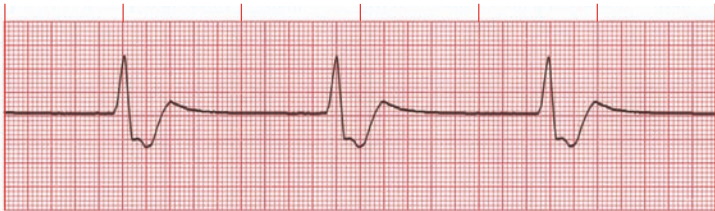
♥ **Clinical Tip:** Do not use adenosine, beta blockers, calcium channel blockers, or digoxin with A-fib or A-flutter associated with WPW.

ECG Test Strip 1

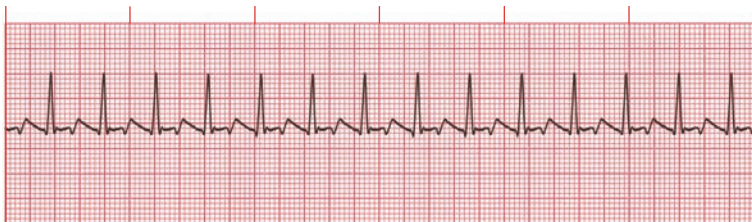
Note: All ECG strips in this tab were recorded in lead II.



ECG Test Strip 2



ECG Test Strip 3



| ECG Strip 1 | ECG Strip 2 | ECG Strip 3 |
|-----------------|-----------------|-----------------|
| Rate: | Rate: | Rate: |
| Rhythm: | Rhythm: | Rhythm: |
| P Waves: | P Waves: | P Waves: |
| PR Interval: | PR Interval: | PR Interval: |
| QRS: | QRS: | QRS: |
| Interpretation: | Interpretation: | Interpretation: |

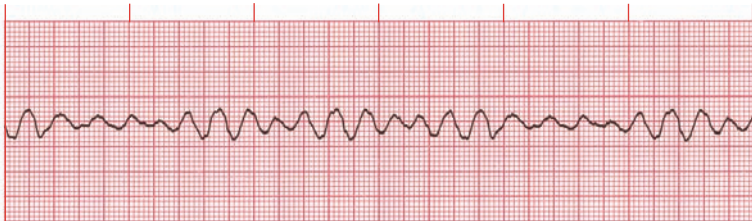
Case Study One: A 66-year-old woman with a history of heart disease is found unresponsive. This is an unwitnessed cardiac arrest with the initial rhythm shown in ECG strip 4. CPR is initiated while the defibrillator is charged. Strip 5 shows the rhythm following defibrillation. Because the first defibrillation was unsuccessful, the machine is charged a second time. The next rhythm is shown in strip 6.

ECG Strip 4 Interpretation:

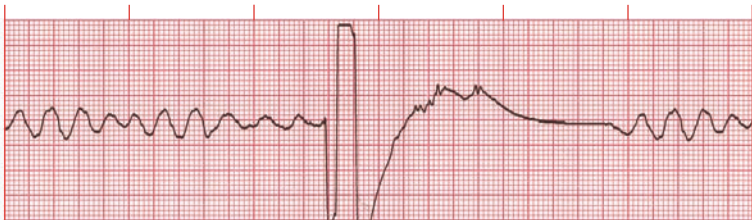
ECG Strip 5 Interpretation:

ECG Strip 6 Interpretation:

ECG Test Strip 4

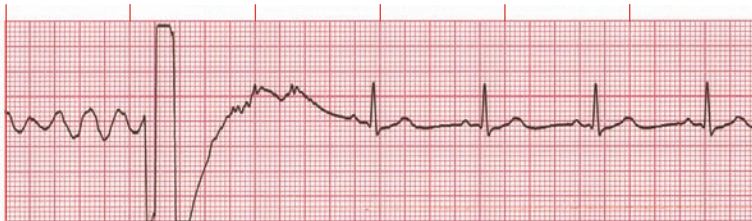

ECG Test Strip 5

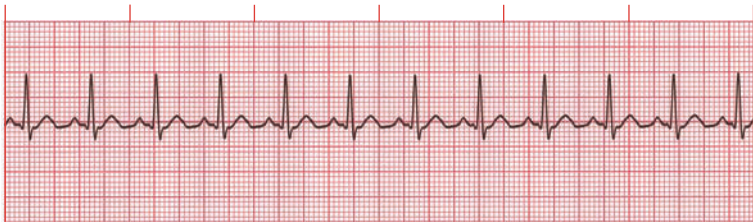


133

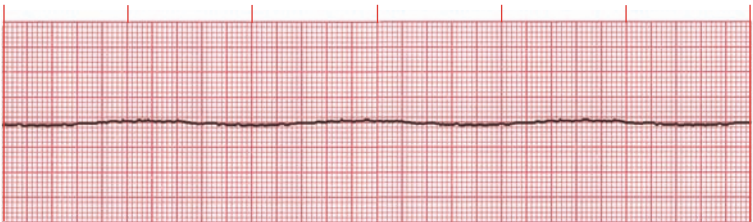ECG Test Strip 6



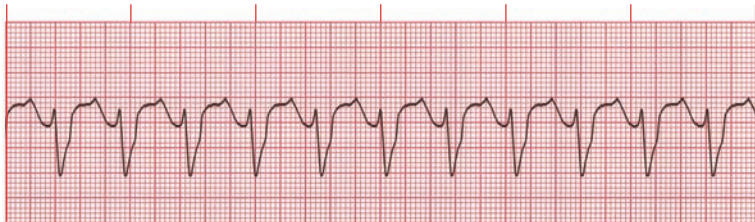
ECG Test Strip 7



ECG Test Strip 8



ECG Test Strip 9



| ECG Strip 7 | ECG Strip 8 | ECG Strip 9 |
|-----------------|-----------------|-----------------|
| Rate: | Rate: | Rate: |
| Rhythm: | Rhythm: | Rhythm: |
| P Waves: | P Waves: | P Waves: |
| PR Interval: | PR Interval: | PR Interval: |
| QRS: | QRS: | QRS: |
| Interpretation: | Interpretation: | Interpretation: |

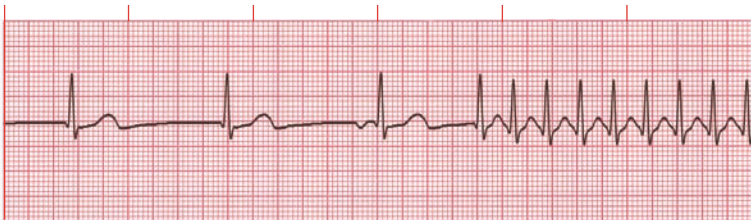
Case Study Two: A 72-year-old man is complaining of dizziness and anxiety. Strip 10 shows his initial rhythm. An IV is started and the patient is given oxygen, but his vital signs become unstable (strip 11). An IVP of adenosine is given and his condition stabilizes with the final rhythm, shown in strip 12.

ECG Strip 10 Interpretation:

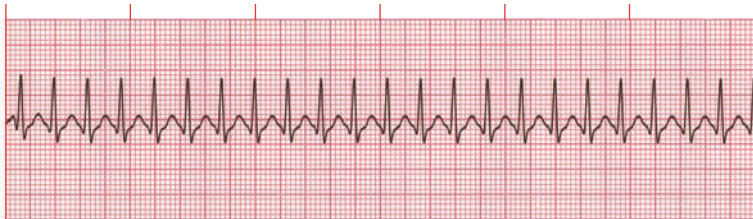ECG Strip 11 Interpretation:

ECG Strip 12 Interpretation:

ECG Test Strip 10

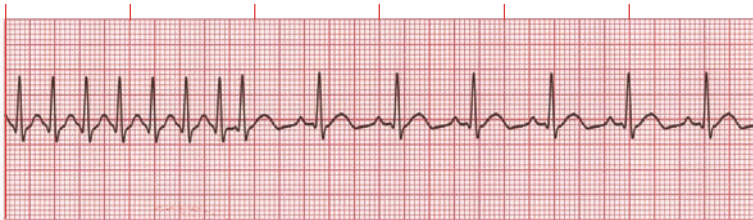


ECG Test Strip 11



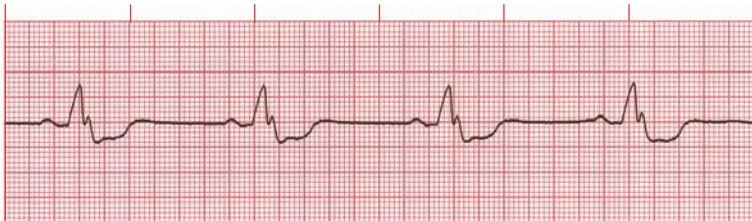137

ECG Test Strip 12

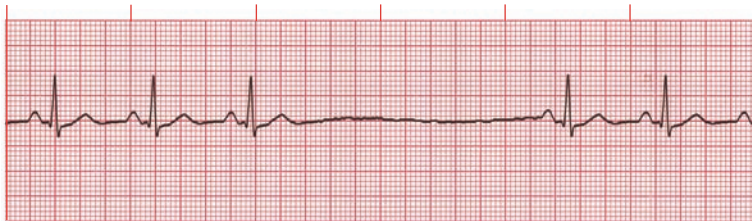

TEST
STRIPS

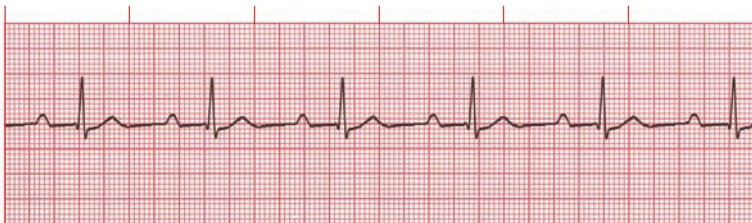
ECG Test Strip 13



ECG Test Strip 14



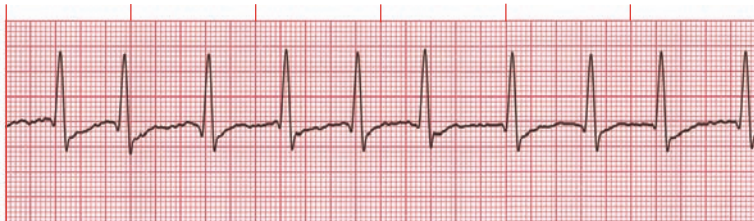ECG Test Strip 15



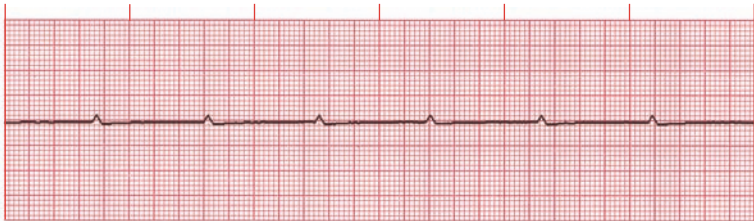139

| ECG Strip 13 | ECG Strip 14 | ECG Strip 15 |
|-----------------|-----------------|-----------------|
| Rate: | Rate: | Rate: |
| Rhythm: | Rhythm: | Rhythm: |
| P Waves: | P Waves: | P Waves: |
| PR Interval: | PR Interval: | PR Interval: |
| QRS: | QRS: | QRS: |
| Interpretation: | Interpretation: | Interpretation: |

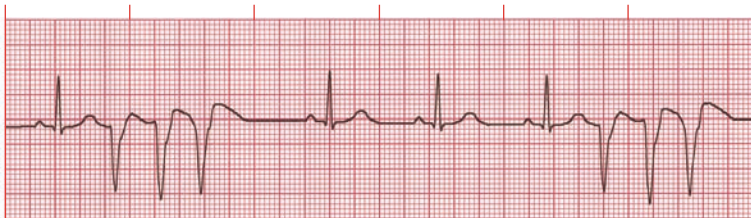
ECG Test Strip 16



ECG Test Strip 17

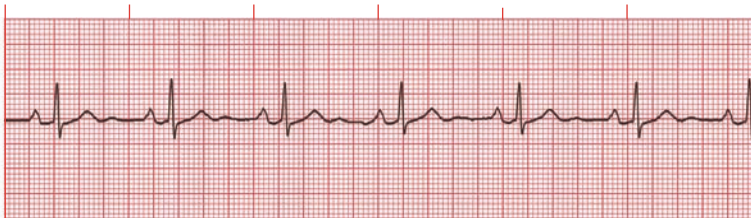


ECG Test Strip 18

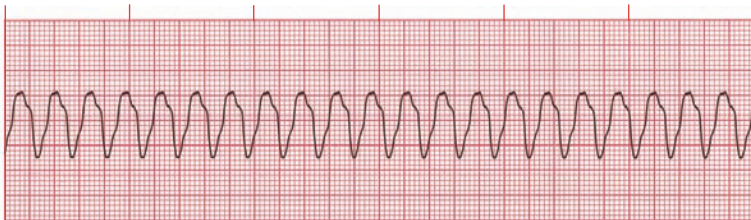


| ECG Strip 16 | ECG Strip 17 | ECG Strip 18 |
|-----------------|-----------------|-----------------|
| Rate: | Rate: | Rate: |
| Rhythm: | Rhythm: | Rhythm: |
| P Waves: | P Waves: | P Waves: |
| PR Interval: | PR Interval: | PR Interval: |
| QRS: | QRS: | QRS: |
| Interpretation: | Interpretation: | Interpretation: |

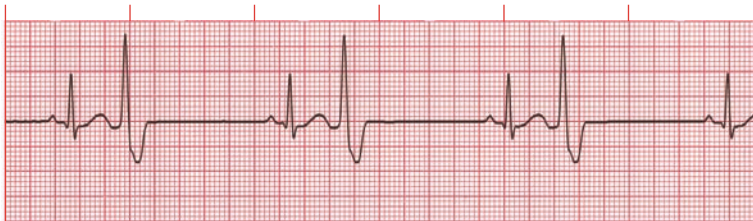ECG Test Strip 19



ECG Test Strip 20



ECG Test Strip 21



| ECG Strip 19 | ECG Strip 20 | ECG Strip 21 |
|-----------------|-----------------|-----------------|
| Rate: | Rate: | Rate: |
| Rhythm: | Rhythm: | Rhythm: |
| P Waves: | P Waves: | P Waves: |
| PR Interval: | PR Interval: | PR Interval: |
| QRS: | QRS: | QRS: |
| Interpretation: | Interpretation: | Interpretation: |

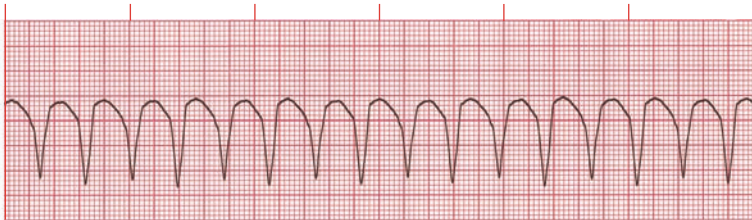
Case Study Three: A 44-year-old man complains of severe chest pain. He has diaphoresis, a BP of 80/60, and 24 respirations per min. The initial rhythm, recorded by the paramedics, is shown in strip 22. An IV is started and the patient is given oxygen. Because his condition is unstable, he receives sedation and cardioversion (strip 23). There is no change, and cardioversion is performed a second time (strip 24).

ECG Strip 22 Interpretation:

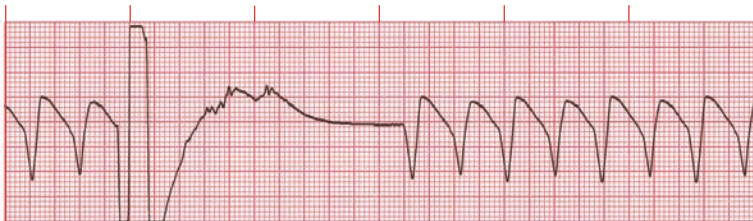
ECG Strip 23 Interpretation:

ECG Strip 24 Interpretation:

ECG Test Strip 22

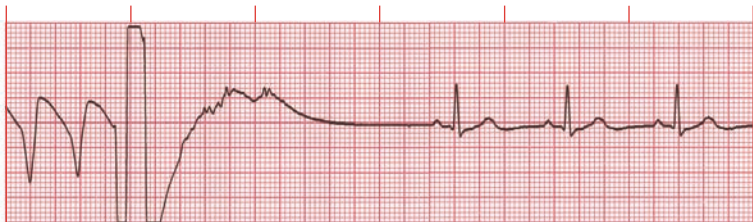


ECG Test Strip 23

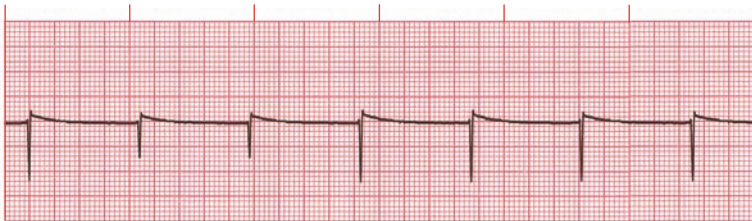


145

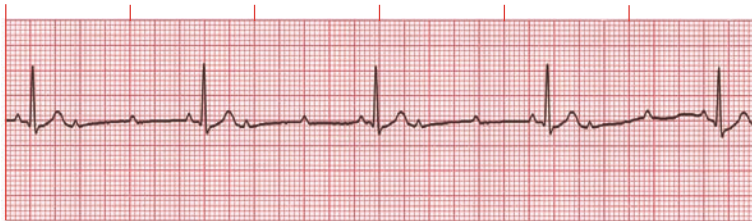ECG Test Strip 24



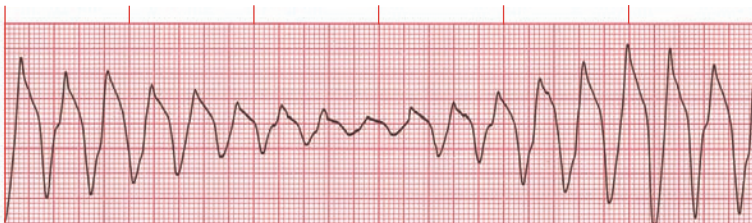ECG Test Strip 25



ECG Test Strip 26

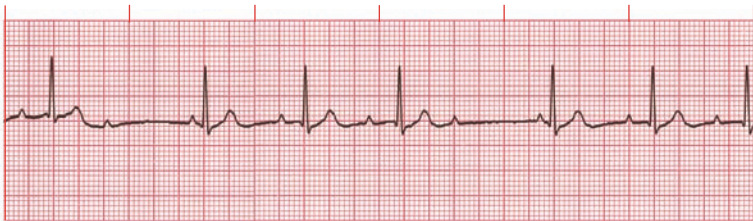


ECG Test Strip 27

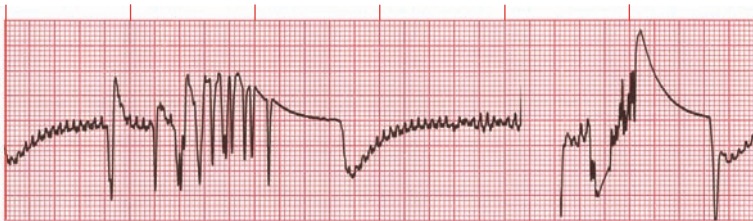

| ECG Strip 25 | ECG Strip 26 | ECG Strip 27 |
|-----------------|-----------------|-----------------|
| Rate: | Rate: | Rate: |
| Rhythm: | Rhythm: | Rhythm: |
| P Waves: | P Waves: | P Waves: |
| PR Interval: | PR Interval: | PR Interval: |
| QRS: | QRS: | QRS: |
| Interpretation: | Interpretation: | Interpretation: |

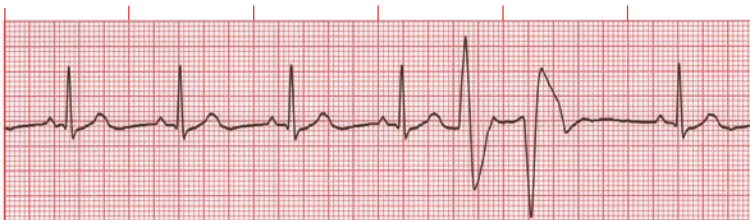ECG Test Strip 28



ECG Test Strip 29

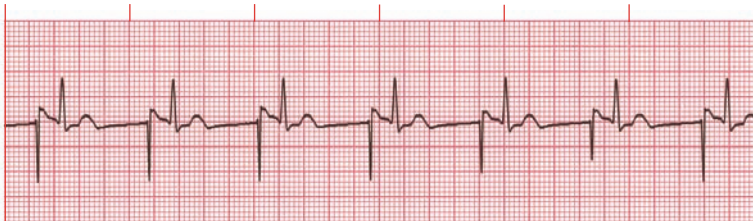


ECG Test Strip 30

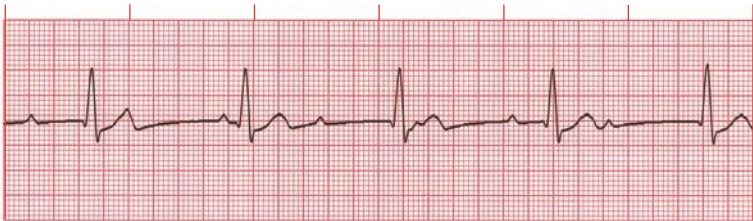

| ECG Strip 28 | ECG Strip 29 | ECG Strip 30 |
|-----------------|-----------------|-----------------|
| Rate: | Rate: | Rate: |
| Rhythm: | Rhythm: | Rhythm: |
| P Waves: | P Waves: | P Waves: |
| PR Interval: | PR Interval: | PR Interval: |
| QRS: | QRS: | QRS: |
| Interpretation: | Interpretation: | Interpretation: |

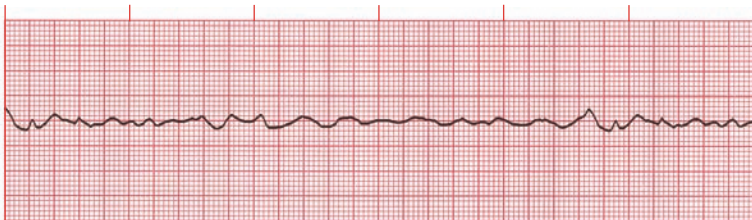ECG Test Strip 31



ECG Test Strip 32

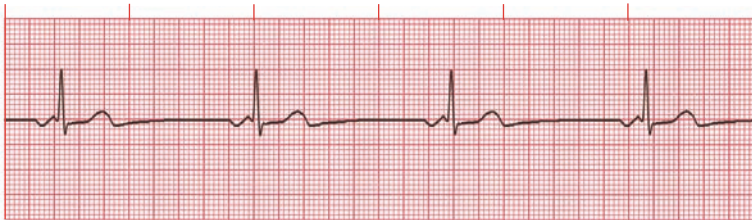


ECG Test Strip 33

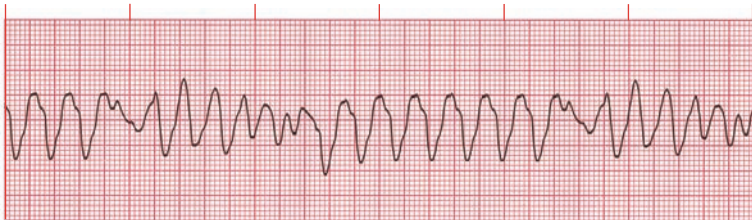


| ECG Strip 31 | ECG Strip 32 | ECG Strip 33 |
|-----------------|-----------------|-----------------|
| Rate: | Rate: | Rate: |
| Rhythm: | Rhythm: | Rhythm: |
| P Waves: | P Waves: | P Waves: |
| PR Interval: | PR Interval: | PR Interval: |
| QRS: | QRS: | QRS: |
| Interpretation: | Interpretation: | Interpretation: |

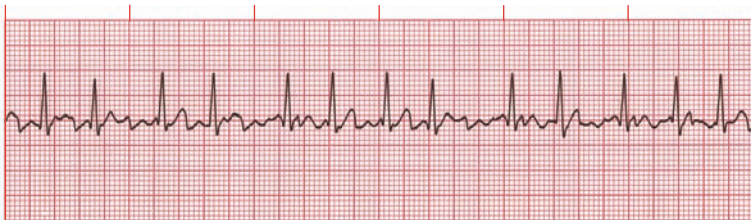ECG Test Strip 34



ECG Test Strip 35

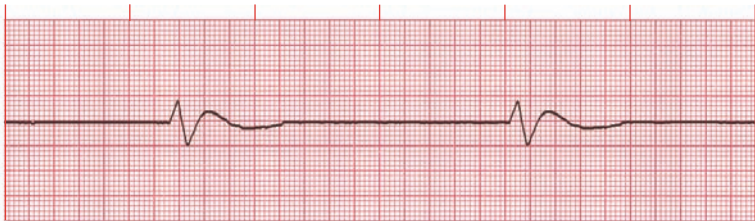

ECG Test Strip 36

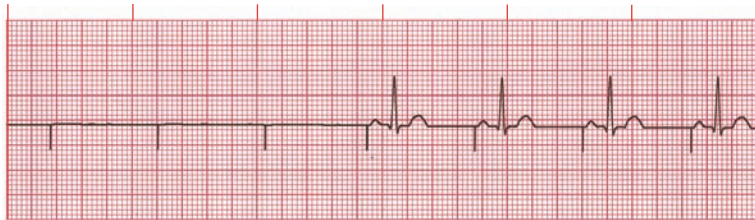

| ECG Strip 34 | ECG Strip 35 | ECG Strip 36 |
|-----------------|-----------------|-----------------|
| Rate: | Rate: | Rate: |
| Rhythm: | Rhythm: | Rhythm: |
| P Waves: | P Waves: | P Waves: |
| PR Interval: | PR Interval: | PR Interval: |
| QRS: | QRS: | QRS: |
| Interpretation: | Interpretation: | Interpretation: |

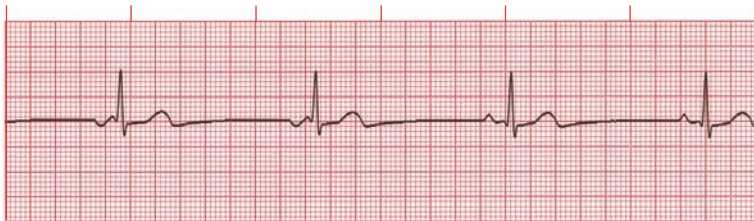ECG Test Strip 37



ECG Test Strip 38



ECG Test Strip 39



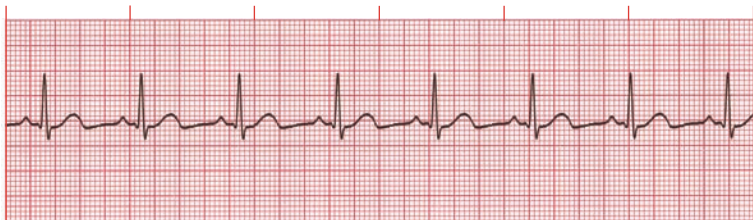155

ECG Strip 37 Interpretation:

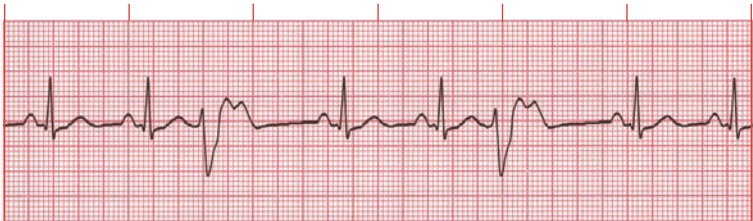
ECG Strip 38 Interpretation:

ECG Strip 39 Interpretation:

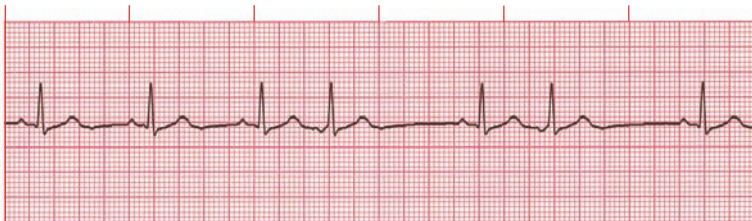ECG Test Strip 40



ECG Test Strip 41



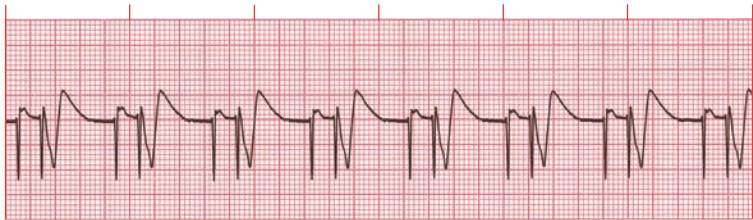ECG Test Strip 42



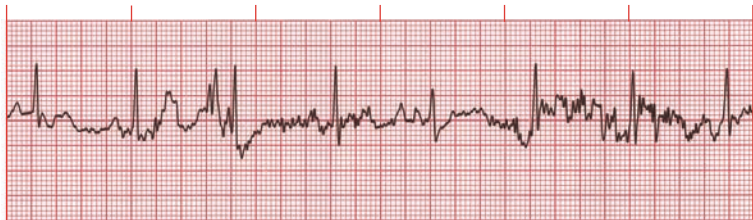157

| ECG Strip 40 | ECG Strip 41 | ECG Strip 42 |
|-----------------|-----------------|-----------------|
| Rate: | Rate: | Rate: |
| Rhythm: | Rhythm: | Rhythm: |
| P Waves: | P Waves: | P Waves: |
| PR Interval: | PR Interval: | PR Interval: |
| QRS: | QRS: | QRS: |
| Interpretation: | Interpretation: | Interpretation: |

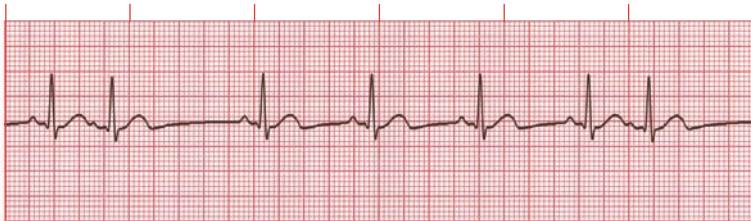
ECG Test Strip 43



ECG Test Strip 44

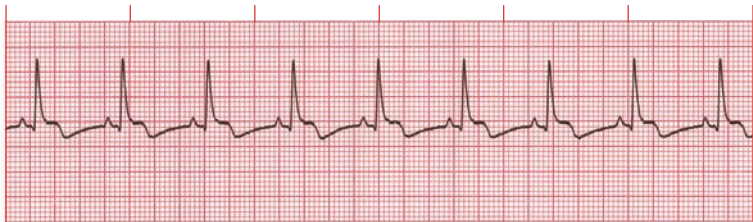


ECG Test Strip 45

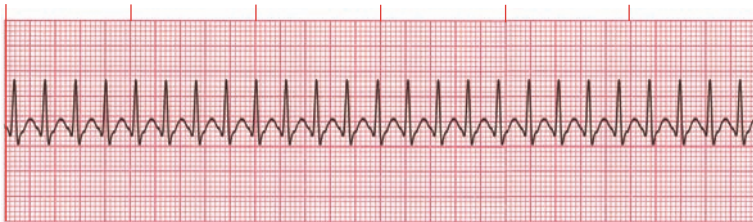


| ECG Strip 43 | ECG Strip 44 | ECG Strip 45 |
|-----------------|-----------------|-----------------|
| Rate: | Rate: | Rate: |
| Rhythm: | Rhythm: | Rhythm: |
| P Waves: | P Waves: | P Waves: |
| PR Interval: | PR Interval: | PR Interval: |
| QRS: | QRS: | QRS: |
| Interpretation: | Interpretation: | Interpretation: |

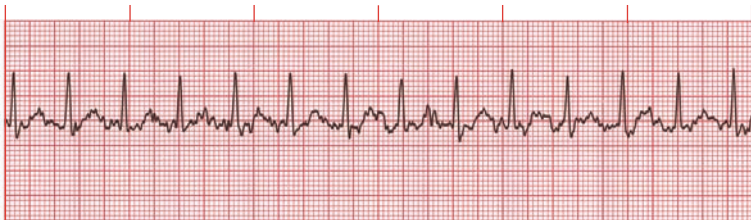ECG Test Strip 46



ECG Test Strip 47

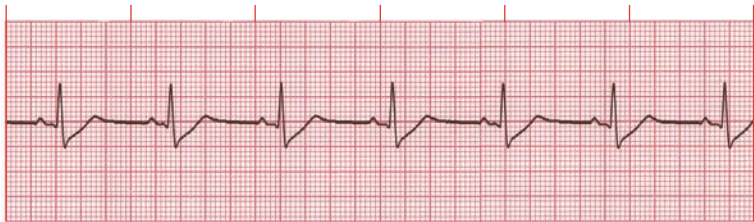


ECG Test Strip 48

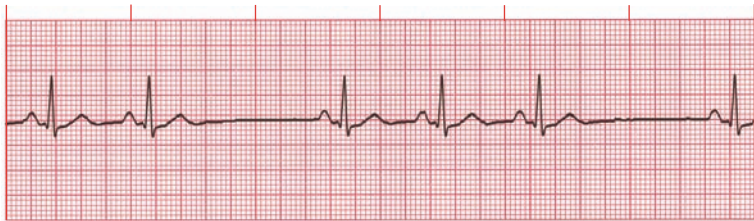

| ECG Strip 46 | ECG Strip 47 | ECG Strip 48 |
|-----------------|-----------------|-----------------|
| Rate: | Rate: | Rate: |
| Rhythm: | Rhythm: | Rhythm: |
| P Waves: | P Waves: | P Waves: |
| PR Interval: | PR Interval: | PR Interval: |
| QRS: | QRS: | QRS: |
| Interpretation: | Interpretation: | Interpretation: |

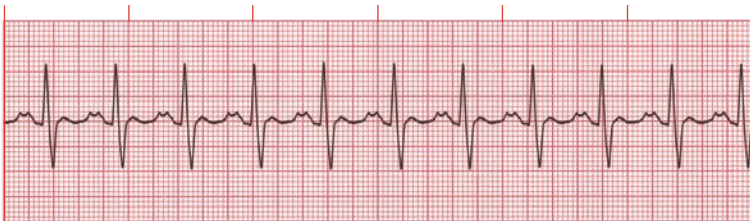
ECG Test Strip 49



ECG Test Strip 50



ECG Test Strip 51



163

| ECG Strip 49 | ECG Strip 50 | ECG Strip 51 |
|-----------------|-----------------|-----------------|
| Rate: | Rate: | Rate: |
| Rhythm: | Rhythm: | Rhythm: |
| P Waves: | P Waves: | P Waves: |
| PR Interval: | PR Interval: | PR Interval: |
| QRS: | QRS: | QRS: |
| Interpretation: | Interpretation: | Interpretation: |

Answers to ECG Test Strips

| ECG Strip 1 | ECG Strip 2 | ECG Strip 3 |
|--|---|---|
| Rate: 35 bpm | Rate: 34 bpm | Rate: Ventricular 150 bpm, atrial 280 bpm |
| Rhythm: Regular | Rhythm: Regular | Rhythm: Regular |
| P Waves: Normal | P Waves: None | P Waves: Flutter waves |
| PR Interval: 0.16 sec | PR Interval: None | PR Interval: Variable |
| QRS: 0.10 sec | QRS: 0.20 sec | QRS: 0.08 sec |
| Interpretation: Sinus bradycardia | Interpretation: Idioventricular rhythm | Interpretation: Atrial flutter with 2:1 conduction |
| ECG Strip 4 Interpretation: Ventricular fibrillation | | |
| ECG Strip 5 Interpretation: VF with defibrillation converting back to same rhythm | | |
| ECG Strip 6 Interpretation: VF with defibrillation converting to sinus rhythm at 68 bpm | | |
| Notes: | | |
| | | |
| | | |
| | | |
| | | |
| | | |
| | | |

| ECG Strip 7 | ECG Strip 8 | ECG Strip 9 |
|---|---------------------------------|--|
| Rate: 115 bpm | Rate: None | Rate: 115 bpm |
| Rhythm: Regular | Rhythm: None | Rhythm: Regular |
| P Waves: Normal | P Waves: None | P Waves: None |
| PR Interval: 0.12 sec | PR Interval: None | PR Interval: None |
| QRS: 0.10 sec | QRS: None | QRS: Wide (>0.12 sec), bizarre |
| Interpretation: Sinus tachycardia | Interpretation: Asystole | Interpretation: Ventricular tachycardia—monomorphic |
| ECG Strip 10 Interpretation: Paroxysmal supraventricular tachycardia—initial junctional rhythm at 48 bpm converting to supraventricular tachycardia at 250 bpm | | |
| ECG Strip 11 Interpretation: SVT at 250 bpm | | |
| ECG Strip 12 Interpretation: SVT at 250 bpm converting to a sinus rhythm at 100 bpm | | |
| Notes: | | |
| | | |
| | | |
| | | |
| | | |
| | | |
| | | |
| | | |
| | | |
| | | |

| ECG Strip 13 | ECG Strip 14 | ECG Strip 15 |
|---|---|---|
| Rate: 41 bpm | Rate: Basic rate 79 bpm | Rate: 58 bpm |
| Rhythm: Regular | Rhythm: Irregular | Rhythm: Regular |
| P Waves: Normal | P Waves: Normal | P Waves: Normal |
| PR Interval: 0.20 sec | PR Interval: 0.16 sec | PR Interval: 0.32 sec |
| QRS: 0.24 sec | QRS: 0.08 sec | QRS: 0.08 sec |
| Interpretation: Sinus bradycardia with a bundle branch block | Interpretation: Sinus rhythm with sinus pause/arrest | Interpretation: Sinus bradycardia with 1st-degree AV block |
| | | |
| ECG Strip 16 | ECG Strip 17 | ECG Strip 18 |
| Rate: Atrial >350 bpm, ventricular 88–115 bpm | Rate: Atrial 60 bpm | Rate: Basic rate 68 bpm |
| Rhythm: Irregular | Rhythm: Atrial regular | Rhythm: Irregular |
| P Waves: None | P Waves: Normal | P Waves: Normal |
| PR Interval: None | PR Interval: None | PR Interval: 0.16 sec |
| QRS: 0.12 sec | QRS: None | QRS: 0.08 sec |
| Interpretation: Atrial fibrillation | Interpretation: P Wave asystole | Interpretation: Sinus rhythm with premature ventricular contractions— triplets |

| ECG Strip 19 | ECG Strip 20 | ECG Strip 21 |
|--|---|--|
| Rate: 65 bpm | Rate: 214 bpm | Rate: Basic rate 35 bpm |
| Rhythm: Regular | Rhythm: Regular | Rhythm: Regular |
| P Waves: Normal | P Waves: None | P Waves: Normal |
| PR Interval: 0.20 sec | PR Interval: None | PR Interval: 0.16 sec |
| QRS: 0.08 sec | QRS: Wide (>0.12 sec), bizarre | QRS: 0.08 sec |
| Interpretation: Normal sinus rhythm with U wave | Interpretation: VT— monomorphic | Interpretation: Sinus bradycardia with ventricular bigeminy |
| ECG Strip 22 Interpretation: VT—monomorphic | | |
| ECG Strip 23 Interpretation: VT—monomorphic with cardioversion converting to same rhythm | | |
| ECG Strip 24 Interpretation: VT—monomorphic with cardioversion converting to a sinus rhythm at 65 bpm | | |
| Notes: | | |
| | | |
| | | |
| | | |
| | | |
| | | |
| | | |
| | | |

| ECG Strip 25 | ECG Strip 26 | ECG Strip 27 |
|--|--|--|
| Rate: Pacing spikes 68 bpm | Rate: Atrial 125 bpm, ventricular 44 bpm | Rate: 200–250 bpm |
| Rhythm: Regular pacing spikes | Rhythm: Regular | Rhythm: Irregular |
| P Waves: None | P Waves: Normal | P Waves: None |
| PR Interval: None | PR Interval: 0.16 sec | PR Interval: None |
| QRS: None | QRS: 0.10 sec | QRS: Wide (>0.12 sec), bizarre |
| Interpretation: Pacemaker—100% failure to capture, underlying rhythm asystole | Interpretation: 2nd-degree AV block Type II with 3:1 conduction | Interpretation: VT—torsade de pointes |
| ECG Strip 28 | ECG Strip 29 | ECG Strip 30 |
| Rate: 50–75 bpm | Rate: None | Rate: Basic rate 68 bpm |
| Rhythm: Irregular | Rhythm: None | Rhythm: Irregular |
| P Waves: Normal | P Waves: None | P Waves: Normal |
| PR Interval: 0.12–0.28 sec | PR Interval: None | PR Interval: 0.16 sec |
| QRS: 0.08 sec | QRS: None | QRS: 0.10 sec |
| Interpretation: 2nd-degree AV block Type I | Interpretation: Loose electrodes | Interpretation: Sinus rhythm with multifiform PVCs—couplets |

| ECG Strip 31 | ECG Strip 32 | ECG Strip 33 |
|---|---|---|
| Rate: 68 bpm | Rate: Atrial 75 bpm, ventricular 48 bpm | Rate: Indeterminate |
| Rhythm: Regular | Rhythm: Regular | Rhythm: Irregular |
| P Waves: Upright with pacing spikes | P Waves: Normal, superimposed on QRS and T waves | P Waves: None |
| PR Interval: 0.16 sec | PR Interval: Varies | PR Interval: None |
| QRS: 0.10 sec | QRS: 0.16 sec | QRS: None |
| Interpretation: Atrial pacemaker with 100% capture | Interpretation: 3rd-degree AV block | Interpretation: VF |
| ECG Strip 34 | ECG Strip 35 | ECG Strip 36 |
| Rate: 48 bpm | Rate: 250 bpm | Rate: Atrial ≥ 350 bpm, ventricular 94–167 bpm |
| Rhythm: Regular | Rhythm: Irregular | Rhythm: Irregular |
| P Waves: Inverted | P Waves: None | P Waves: None |
| PR Interval: 0.12 sec | PR Interval: None | PR Interval: None |
| QRS: 0.08 sec | QRS: Wide (>0.12 sec), bizarre | QRS: 0.10 sec |
| Interpretation: Junctional rhythm | Interpretation: VT— polymorphic | Interpretation: A-fib |

ECG Strip 37 Interpretation: Agonal rhythm at 22 bpm

ECG Strip 38 Interpretation: Pacemaker failure to capture. When the pacemaker voltage is increased, there is capture at pacemaker spike 4.

ECG Strip 39 Interpretation: Junctional bradycardia at 38 bpm converting to sinus bradycardia at 38 bpm

Notes:

| ECG Strip 40 | ECG Strip 41 | ECG Strip 42 |
|--|--|---|
| Rate: 75 bpm | Rate: Basic rate 79 bpm | Rate: Basic rate 68 bpm |
| Rhythm: Regular | Rhythm: Irregular | Rhythm: Irregular |
| P Waves: Normal | P Waves: Normal | P Waves: Normal; none associated with premature junctional contraction |
| PR Interval: 0.16 sec | PR Interval: 0.20 sec | PR Interval: 0.16 sec |
| QRS: 0.08 sec | QRS: 0.10 sec | QRS: 0.10 sec |
| Interpretation: Normal sinus rhythm | Interpretation: Sinus rhythm with ventricular trigeminy | Interpretation: Sinus rhythm with PJs at beats 4 and 6 |

| ECG Strip 43 | ECG Strip 44 | ECG Strip 45 |
|---|--|--|
| Rate: 75 bpm | Rate: 75 bpm | Rate: 68 bpm |
| Rhythm: Regular | Rhythm: Regular | Rhythm: Irregular |
| P Waves: Upright with pacing spike | P Waves: Not visible | P Waves: Normal |
| PR Interval: 0.20 sec | PR Interval: Not measurable | PR Interval: 0.16 sec |
| QRS: 0.16 sec | QRS: Not measurable | QRS: 0.10 sec |
| Interpretation: Atrial-ventricular pacemaker | Interpretation: Sinus rhythm with muscle artifact | Interpretation: Sinus rhythm with two premature atrial contractions (beats 2 and 7) |
| ECG Strip 46 | ECG Strip 47 | ECG Strip 48 |
| Rate: 88 bpm | Rate: 250 bpm | Rate: 136 bpm |
| Rhythm: Regular | Rhythm: Regular | Rhythm: Regular |
| P Waves: Normal | P Waves: Buried in T waves | P Waves: Not visible |
| PR Interval: 0.12 sec | PR Interval: Not measurable | PR Interval: Not measurable |
| QRS: 0.12 sec | QRS: 0.08 sec | QRS: 0.10 sec |
| Interpretation: Sinus rhythm with ST segment elevation | Interpretation: SVT | Interpretation: Sinus tachycardia with muscle artifact |

| ECG Strip 49 | ECG Strip 50 | ECG Strip 51 |
|--|--|---|
| Rate: 71 bpm | Rate: Basic rate 79 bpm | Rate: 107 bpm |
| Rhythm: Regular | Rhythm: Irregular | Rhythm: Regular |
| P Waves: Normal | P Waves: Normal | P Waves: Notched (P prime) |
| PR Interval: 0.16 sec | PR Interval: 0.16 sec | PR Interval: 0.20 sec |
| QRS: 0.10 sec | QRS: 0.10 sec | QRS: 0.12 sec |
| Interpretation: Sinus rhythm with ST segment depression | Interpretation: Sinus rhythm with two SA blocks | Interpretation: Sinus tachycardia with P' wave |
| Notes: | | |
| | | |
| | | |
| | | |
| | | |
| | | |
| | | |
| | | |
| | | |
| | | |

Notes:

173

**TEST
STRIPS**

Troubleshooting ECG Problems

- Place leads in the correct position. Incorrect placement can give false readings.
- Avoid placing leads over bony areas.
- In patients with large breasts, place the electrodes under the breast. Accurate tracings are obtained through the least amount of fat tissue.
- Apply tincture of benzoin to the electrode sites if the patient is diaphoretic. The electrodes will adhere to the skin better.
- Shave hair at the electrode site if it interferes with contact between the electrode and skin.
- Discard old electrodes and use new ones if the gel on the back of the electrode dries.

Cable Connections

It is important to know if you are using an American or European cable for ECG monitoring. The colors of the wires differ as shown below.

Monitoring Cable Connections

| U.S.A. | Connect to | Europe |
|--------|------------|--------|
| White | Right arm | Red |
| Black | Left arm | Yellow |
| Red | Left leg | Green |
| Green | Right leg | Black |
| Brown | Chest | White |

Patient Cable

Monitoring cables contain varying numbers of wires.

3- and 4-wire cables: Allow a choice of limb and augmented leads.

5-wire cable: Allows a choice of limb and augmented leads plus a chest lead.

10-wire cable: Records a 12-lead ECG.

Patient ECG Record

Patient Name: _____

Sex **F** **M**

Heart rate: _____ **bpm**

- | | | | |
|---|---|---|--|
| <input type="checkbox"/> Normal (60–100 bpm) | Y | N | |
| <input type="checkbox"/> Bradycardia (<60 bpm) | Y | N | |
| <input type="checkbox"/> Tachycardia (>100 bpm) | Y | N | |

Rhythm

- | | | | |
|------------------------------------|---|---|--|
| <input type="checkbox"/> Regular | Y | N | |
| <input type="checkbox"/> Irregular | Y | N | |
| <input type="checkbox"/> P waves | Y | N | |

P Waves (form)

- | | | | |
|---|---|---|--|
| <input type="checkbox"/> Normal (upright and uniform) | Y | N | |
| <input type="checkbox"/> Inverted | Y | N | |

P wave associated with QRS Y N

PR interval normal (0.12–0.20 sec) Y N

P waves and QRS complexes associated with one another Y N

QRS Interval

- | | | | |
|--|---|---|--|
| <input type="checkbox"/> Normal (0.6–0.10 sec) | Y | N | |
| <input type="checkbox"/> Wide (>0.10 sec) | Y | N | |

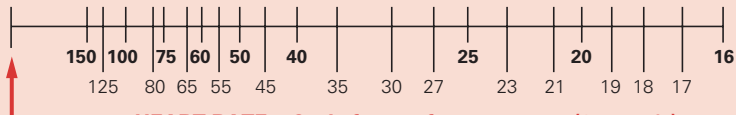Are the QRS complexes grouped or not grouped?

Are there any dropped beats?

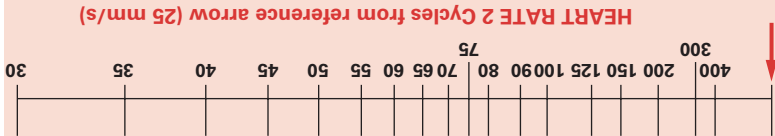
Is there a compensatory or noncompensatory pause?

QT interval: _____

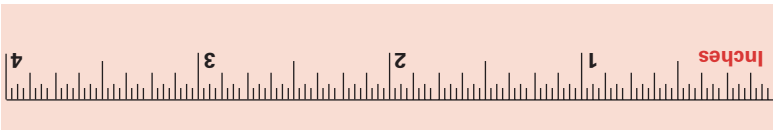
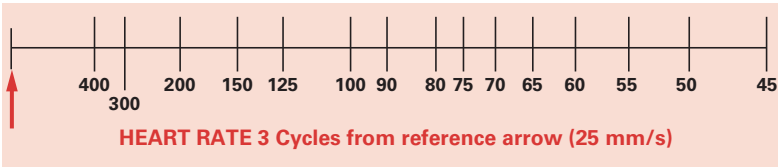
Interpretation: _____



HEART RATE 1 Cycle from reference arrow (25 mm/s)



HEART RATE 2 Cycles from reference arrow (25 mm/s)



Abbreviations

| | |
|-----------|--|
| ACE | angiotensin-converting enzyme |
| AED | automatic external defibrillator |
| A-fib | atrial fibrillation |
| A-flutter | atrial flutter |
| ARDS | acute respiratory distress syndrome |
| AV | atrioventricular |
| BBB | bundle branch block |
| BP | blood pressure |
| bpm | beats per min |
| BUN | blood urea nitrogen |
| CAD | coronary artery disease |
| CHF | congestive heart failure |
| CO | cardiac output |
| COPD | chronic obstructive pulmonary disease |
| CPR | cardiopulmonary resuscitation |
| CVA | cerebrovascular accident |
| ECG | electrocardiogram |
| EMD | electromechanical dissociation |
| ET | endotracheal |
| FAB | fragment antigen binding |
| HR | heart rate |
| HTN | hypertension |
| IHSS | idiopathic hypertrophic subaortic stenosis |
| IM | intramuscular |
| IV | intravenous |
| IVP | intravenous push |
| LA | left arm |
| LL | left leg |
| LOC | level of consciousness |
| MAT | multifocal atrial tachycardia |
| MCL | modified chest lead |
| MI | myocardial infarction |
| NSR | normal sinus rhythm |
| PAC | premature atrial contraction |
| PAT | paroxysmal atrial tachycardia |
| PEA | pulseless electrical activity |

| | |
|------|---|
| PJC | premature junctional contraction |
| PO | by mouth |
| PSVT | paroxysmal supraventricular tachycardia |
| PVC | premature ventricular contraction |
| RA | right arm |
| RL | right leg |
| SA | sinoatrial |
| SC | subcutaneous |
| SV | stroke volume |
| SVT | supraventricular tachycardia |
| VF | ventricular fibrillation |
| VT | ventricular tachycardia |
| WAP | wandering atrial pacemaker |
| WPW | Wolff-Parkinson-White |

Selected References

1. Cummins, RO (ed.): ACLS Provider Manual. American Heart Association, Dallas, 2002.
2. Deglin, JH, Vallerand, AH: Davis's Drug Guide for Nurses, ed 8. FA Davis, Philadelphia, 2003.
3. Deglin, JH, Vallerand, AH: Med Notes. FA Davis, Philadelphia, 2004.
4. Myers, E: RNotes. FA Davis, Philadelphia, 2003.
5. Myers, E, Hopkins, T: MedSurg Notes. FA Davis, Philadelphia, 2004.
6. Physicians' Desk Reference, ed 59. Thomson Healthcare, Montvale, NJ, 2005.
7. Scanlon, VC, Sanders, T: Essentials of Anatomy and Physiology, ed 4. FA Davis, Philadelphia, 2003.
8. Stapleton, ER, et al. (eds.): BLS for Healthcare Providers. American Heart Association, Dallas, 2001.
9. Taber's Cyclopedic Medical Dictionary, ed 19. FA Davis, Philadelphia, 2001.

Illustration Credits

Pages 2, 3, 4, 5, 6, 7, 8, from: Scanlon, *Essentials of Anatomy and Physiology*, ed 4. F.A. Davis, Philadelphia, 2003.

Pages 10, 11, 16, 19, 73, 100, 111, 115 from: Myers, *MedSurg Notes*. F.A. Davis, Philadelphia, 2004.

Pages 28–64, 66–70, 130–163 from: Armstrong Medical Industries, Inc. Lincolnshire, IL.

Index

Note: Page numbers followed by f refer to illustrations and pages followed by t refer to tables.

A

- Accelerated idioventricular rhythm, 49, 49f
- Accelerated junctional rhythm, 44, 44f
- ACE (angiotensin-converting enzyme) inhibitors, as emergency cardiac medications, 86
- Acute MI. *See* Infarction, myocardial.
- Adenosine, as emergency cardiac medication, 86–87
- Adult, cardiopulmonary resuscitation of, 106t, 107
- conscious, emergency management of obstructed airway in, 110
- Heimlich maneuver in, 110f
- unconscious, emergency management of obstructed airway in, 112
- AED (automated external defibrillator), 101
- A-fib (atrial fibrillation), 41, 41f, 140f, 153f, 166, 169
- management of, 127
- in Wolff-Parkinson-White syndrome, 128
- A-flutter (atrial flutter), 40, 40f, 131f, 164
- management of, 127
- in Wolff-Parkinson-White syndrome, 128
- Agonal rhythm, 154f, 170
- Airway obstruction, emergency management of, 110–114, 115f
- in conscious adult, 110
- in conscious child, 110
- in conscious infant, 111
- in unconscious adult, 112
- in unconscious child, 113
- in unconscious infant, 114
- via Heimlich maneuver, 110f, 111f
- universal sign of, 115f
- Amiodarone, as emergency cardiac medication, 87
- Angiotensin-converting enzyme (ACE) inhibitors, as emergency cardiac medications, 86
- Anterior myocardial infarction, 79, 79f
- Arrest, sinus, 32, 32f, 138f, 166
- Arrhythmia(s), 28–59, 29f–59f
- atrial, 34–42, 34f–42f
- junctional, 43–47, 43f–47f
- sinoatrial node, 28–33, 29f–33f
- sinus, 31, 31f
- ventricular, 48–59, 48f–59f
- Arterial circulation, 7f
- coronary, 5f
- Artifacts, 69, 69f, 70, 70f
- muscle, 70f, 158f, 161f, 171

- Aspirin, as emergency cardiac medication, 88
- Asystole, 59, 59f, 134f, 140f, 165, 166
management of, 118
- Atrial arrhythmias, 34–42, 34f–42f
- Atrial contraction(s), premature, 36, 36f, 159f, 171
- Atrial fibrillation (A-fib), 41, 41f, 140f, 153f, 166, 169
management of, 127
in Wolff-Parkinson-White syndrome, 128
- Atrial flutter (A-flutter), 40, 40f, 131f, 164
management of, 127
in Wolff-Parkinson-White syndrome, 128
- Atrial pacemaker, wandering, 34, 34f
- Atrial tachycardia, 37, 37f
multifocal, 35, 35f
- Atrioventricular block(s), 60–64, 60f–64f
first-degree, 60, 60f, 139f, 166
Mobitz I, 61, 61f, 148f, 168
Mobitz II, 62, 62f, 146f, 168
second-degree, 61, 61f, 62, 62f, 146f, 148f, 168
third-degree, 63, 63f, 150f, 169
Wenckebach, 61, 61f
- Atrioventricular node, 10
- Atropine, as emergency cardiac medication, 88
- Augmented limb leads, in electrocardiography, 15, 15f
- Automated external defibrillator (AED), 101
- Automaticity, of cardiac cells, 9
- AV. *See* Atrioventricular entries.
- B**
- Bag-valve mask, in airway management, 115f
- BBB (bundle branch block), 64, 64f, 138f, 166
left, 84, 84f
right, 85, 85f
- Beta blockers, as emergency cardiac medications, 88–89
- Bicarbonate, as emergency cardiac medication, 98
- Bigeminy, ventricular, 52, 52f, 143f, 167
- Block(s), atrioventricular, 60–64, 60f–64f
first-degree, 60, 60f, 139f, 166
Mobitz I, 61, 61f, 148f, 168
Mobitz II, 62, 62f, 146f, 168
second-degree, 61, 61f, 62, 62f, 146f, 148f, 168
third-degree, 63, 63f, 150f, 169
Wenckebach, 61, 61f
bundle branch, 64, 64f, 138f, 166
left, 84, 84f
right, 85, 85f
sinoatrial, 33, 33f, 162f, 172
- Blood vessel structures, 6, 6f
- Bradycardia, 120
junctional, 155f, 170

Bradycardia (*Continued*)
 management of, 120
 sinus, 29, 29f, 130f, 138f,
 139f, 143f, 164, 166, 167
 junctional bradycardia
 converting to, 155f, 170
 with muscle artifact, 161f,
 171

Bundle branch(es), 10

Bundle branch block (BBB), 64,
 64f, 138f, 166
 left, 84, 84f
 right, 85, 85f

Bundle of His, 10

C

Cable connections, in electro-
 cardiography, 17, 17f, 174

Calcium chloride, as emer-
 gency cardiac medication,
 89

Cardiac anatomy, 1, 1f–5f, 3

Cardiac electrophysiology,
 9–11, 10f–11f, 74, 74f. *See*
also Electrocardiography
 (ECG).

Cardiac ischemia, 76, 76f. *See*
also Infarction, myocardial.
 chest pain due to, manage-
 ment of, 119

Cardiopulmonary resuscitation
 (CPR), 106t, 107–109, 115f
 by one rescuer, 106t
 by two rescuers, 106t
 of adult, 106t, 107
 of child, 106t, 108
 of infant, 106t, 109
 of newborn, 106t

Cardiovascular system, 6, 6f–8f

Cardioversion, 102

Carotid sinus massage,
 104–105, 105f

Chambers of heart, 4f

Chest compressions, in CPR,
 106t, 107, 108, 109

Chest leads, in electrocardiog-
 raphy, 16, 16f, 18, 18f

Chest pain, ischemic, manage-
 ment of, 119

Child, cardiopulmonary resus-
 citation of, 106t, 108
 conscious, emergency
 management of
 obstructed airway in, 110
 Heimlich maneuver in, 110f
 unconscious, emergency
 management of
 obstructed airway in, 113

Chin lift, in airway manage-
 ment, 115f

Choking. *See* Airway obstruc-
 tion.

Circulation, arterial, 7f
 coronary, 5f
 venous, 8f

Complex, 21
 QRS, 22, 27

Complex width, tachycardia
 management in relation to,
 122, 123, 124–128

Conduction system, of heart,
 10–11, 10f–11f. *See also*
 Electrocardiography (ECG).

Conductivity, of cardiac cells, 9

Conscious patient, emergency
 management of obstructed
 airway in, 110, 111

Contractility, of cardiac cells, 9

Contraction(s), atrial, premature, 36, 36f, 159f, 171
 junctional, premature, 47, 47f, 157f, 170
 ventricular, premature, 50, 50f
 couplet (paired), 53, 53f, 149f, 168
 every 2nd beat (bigeminal), 52, 52f, 147f, 163
 every 3rd beat (trigeminal), 52, 52f, 156f, 170
 every 4th beat (quadrigeminal), 53, 53f
 multiform, 51, 51f
 paired (couplet), 53, 53f, 149f, 168
 triplet, 141f, 166
 uniform, 51, 51f

Coronary arterial circulation, 5f

Couplet PVCs (paired PVCs), 53, 53f, 149f, 168

CPR. *See* Cardiopulmonary resuscitation (CPR).

D

Defibrillation, 99–101, 100f
 automated external, 101
 manual, 100

Depolarization, 11

Digoxin, as emergency cardiac medication, 90

Digoxin toxicity, antidote for, 89

Diltiazem, as emergency cardiac medication, 90

Dopamine, as emergency cardiac medication, 91

Dropped beats, 26

E

ECG. *See* Electrocardiography (ECG).

Electrical activity, pulseless, 58, 58f
 management of, 117
 mnemonics for causes of, 117

Electrical axis deviation, of heart, 74, 74f

Electrical conduction system, of heart, 10–11, 10f–11f. *See also* Electrocardiography (ECG).

Electrocardiography (ECG), 12–13, 21f

cable connections in, 17, 17f, 174

electrode placement in, 13–20, 13f–20f

loose, artifact due to, 69f, 148f, 168

fifteen-lead, 20, 20f

heart rate calculation via, 23–24, 23f, 25f, 176f, 177f

interpretation of results of, 22, 26–27

as abnormal, 28–64, 29f–64f. *See also* Arrhythmia(s) and specific patterns.

as artifactual. *See* Artifacts.

Electrocardiography (*Cont'd*)
 as diagnostic yield in
 suspected MI, 79–83,
 79f–83f
 as pacemaker rhythms, 66,
 66f, 67f, 150f, 158f, 169,
 171
 on patient's record, 175
 leads used in, 13–20, 13f–20f
 monitoring cables in, 174
 troubleshooting in, 174
 twelve-lead, 19, 19f, 72, 78,
 78f

Emergency medical skills,
 99–115

Emergency medications, 86–99

Endocardium, 2f

Epinephrine, as emergency
 cardiac medication, 91–92

Escape beat, junctional, 46,
 46f

Excitability, of cardiac cells, 9

External defibrillator, auto-
 mated, 101

F

Fibrillation, atrial, 41, 41f, 140f,
 153f, 166, 169

management of, 127
 in Wolff-Parkinson-White
 syndrome, 128

ventricular, 57, 57f, 132f,
 133f, 151f, 164, 169
 management of, 116

Fibrinolytic agents, as emer-
 gency cardiac medications,
 92

Fifteen-lead electrocardiogra-
 phy, 20, 20f

First-degree atrioventricular
 block, 60, 60f, 139f, 166

Flutter, atrial, 40, 40f, 131f,
 164

management of, 127
 in Wolff-Parkinson-White
 syndrome, 128

Furosemide, as emergency
 cardiac medication, 92–93

G

Great vessels of heart, 4f

H

H mnemonic, for causes of
 pulseless electrical activity,
 117

Head tilt, in airway manage-
 ment, 115f

Heart, anatomy of, 1, 1f–5f, 3
 cells of, properties of, 9
 chambers of, 4f
 coronary arteries of, 5f
 electrical axis deviation of,
 74, 74f

electrical conduction system
 of, 10–11, 10f–11f. *See also*
 Electrocardiography
 (ECG).

great vessels of, 4f
 ischemia of, 76, 76f. *See also*
 Infarction, myocardial.
 chest pain due to,
 management of, 119

layers of, 2f
 infarct sites in. *See*
 Infarction, myocardial.

physiology of, 9
 valves of, 3, 3f

Heart rate, methods of calculating, 23–24, 23f, 25f, 176f, 177f
 Heimlich maneuver, 110f, 111f

I

Ibutilide, as emergency cardiac medication, 93
 Idioventricular rhythm, 48, 48f, 130f, 164
 accelerated, 49, 49f
 Infant, cardiopulmonary resuscitation of, 106t, 109
 conscious, emergency management of
 obstructed airway in, 111
 Heimlich maneuver in, 111f
 unconscious, emergency management of
 obstructed airway in, 114

Infarction, myocardial, 75, 76, 79–83
 anterior, 79, 79f
 electrocardiographic evidence for, 79–83, 79f–83f
 inferior, 80, 80f
 lateral, 81, 81f
 posterior, 83, 83f
 propagation of, 76, 76f
 septal, 82, 82f
 Inferior myocardial infarction, 80, 80f

Interval(s), 21
 PR, 22, 26
 QRS, 26
 QT, 22, 26

Ischemia, cardiac, 76, 76f. *See also* Infarction, myocardial.

chest pain due to, management of, 119
 Isoproterenol, as emergency cardiac medication, 93–94

J

Jaw thrust, in airway management, 115f
 Junctional arrhythmias, 43–47, 43f–47f
 Junctional bradycardia, 155f, 170
 Junctional contraction(s), premature, 47, 47f, 157f, 170
 Junctional escape beat, 46, 46f
 Junctional rhythm, 43, 43f
 accelerated, 44, 44f
 Junctional tachycardia, 45, 45f
 management of, 125

L

Lateral myocardial infarction, 81, 81f
 Left bundle branch, 10
 Left bundle branch block, 84, 84f
 Lidocaine, as emergency cardiac medication, 94
 Limb leads, in electrocardiography, 13–15, 13f–15f
 Loose electrode(s), artifact due to, 69f, 148f, 168

M

Magnesium sulfate, as emergency cardiac medication, 95
 Manual defibrillation, 100
 Massage, carotid sinus, 104–105, 105f

MAT (multifocal atrial tachycardia), 35, 35f

Medical skills, emergency, 99–115

Medications, emergency, 86–99

MI. *See* Myocardial infarction.

Mobitz I atrioventricular block, 61, 61f, 148f, 168

Mobitz II atrioventricular block, 62, 62f, 146f, 168

Monitoring cables, in electrocardiography, 174

Monomorphic ventricular tachycardia, 54, 54f, 135f, 142f, 143f, 145f, 165, 167
management of, 122

Morphine, as emergency cardiac medication, 95

Multifocal atrial tachycardia (MAT), 35, 35f

Multiform premature ventricular contraction, 51, 51f

Muscle artifacts, 70f, 158f, 161f, 171

Myocardial infarction, 75, 76, 79–83

anterior, 79, 79f

electrocardiographic evidence for, 79–83, 79f–83f

inferior, 80, 80f

lateral, 81, 81f

posterior, 83, 83f

propagation of, 76, 76f

septal, 82, 82f

Myocardium, 2f

acute infarction of. *See* Myocardial infarction.

N

Narrow-complex tachycardia, management of, 124–128

Newborn, cardiopulmonary resuscitation of, 106t

Nitroglycerin, as emergency cardiac medication, 96

O

Obstructed airway, emergency management of, 110–114, 115f

in conscious adult, 110

in conscious child, 110

in conscious infant, 111

in unconscious adult, 112

in unconscious child, 113

in unconscious infant, 114

via Heimlich maneuver, 110f, 111f

universal sign of, 115f

One-rescuer cardiopulmonary resuscitation, 106t

Oxygen, as emergency cardiac medication, 96–97

P

P wave, 22, 26

PAC(s) (premature atrial contraction[s]), 36, 36f, 159f, 171

Pacemaker, atrial, wandering, 34, 34f

Pacemaker device(s), 65
malfunction of, 68, 68f, 146f, 154f, 168, 170

Pacemaker rhythm, 66, 66f, 67f, 150f, 158f, 169, 171

- Pacing, transcutaneous, 102, 103f
- Pain, ischemic, management of, 119
- Paired PVCs (couplet PVCs), 53, 53f, 149f, 168
- Paroxysmal supraventricular tachycardia (PSVT), 39, 39f, 136f, 165
management of, 124
- Pause, sinus, 32, 32f, 138f, 166
- PEA (pulseless electrical activity), 58, 58f
management of, 117
mnemonics for causes of, 117
- Pediatric patient, cardiopulmonary resuscitation of, 106t, 108, 109
conscious, emergency management of
obstructed airway in, 110, 111
Heimlich maneuver in, 110f, 111f
unconscious, emergency management of
obstructed airway in, 113, 114
- Pericardium, 2f
- PJC(s) (premature junctional contraction[s]), 47, 47f, 157f, 170
- Polymorphic ventricular tachycardia, 55, 55f, 152f, 169
management of, 123
- Posterior myocardial infarction, 83, 83f
- PR interval, 22, 26
- Precordial thump, 104
- Premature atrial contraction(s) (PAC[s]), 36, 36f, 159f, 171
- Premature junctional contraction(s) (PJC[s]), 47, 47f, 157f, 170
- Premature ventricular contraction(s) (PVC[s]), 50, 50f
couplet (paired), 53, 53f, 149f, 168
every 2nd beat (bigeminal), 52, 52f, 143f, 167
every 3rd beat (trigeminal), 52, 52f, 156f, 170
every 4th beat (quadrigeminal), 53, 53f
multiform, 51, 51f
paired (couplet), 53, 53f, 149f, 168
triplet, 141f, 166
uniform, 51, 51f
- Procainamide, as emergency cardiac medication, 97
- PSVT (paroxysmal supraventricular tachycardia), 39, 39f, 136f, 165
management of, 124
- Pulseless electrical activity (PEA), 58, 58f
management of, 117
mnemonics for causes of, 117
- Pulseless ventricular tachycardia, management of, 116
- Purkinje system, 10
- PVC(s) (premature ventricular contraction[s]), 50, 50f
couplet (paired), 53, 53f, 149f, 168

PVC(s) (*Continued*)

- every 2nd beat (bigeminal), 52, 52f, 143f, 157
- every 3rd beat (trigeminal), 52, 52f, 156f, 170
- every 4th beat (quadrigeminal), 53, 53f
- multiform, 51, 51f
- paired (couplet), 53, 53f, 149f, 168
- triplet, 141f, 166
- uniform, 51, 51f

Q

- Q wave, 22
- QRS complex, 27
- QRS interval, 22, 26
- QT interval, 22, 26
- Quadrigeminy, ventricular, 53, 53f

R

- R wave, propagation of, 73, 73f
- Rate component, in rhythm evaluation, 26
- Regularity component, in rhythm evaluation, 26
- Repolarization, 11
- Resuscitation, cardiopulmonary, 106t, 107–109, 115f
 - by one rescuer, 106t
 - by two rescuers, 106t
 - of adult, 106t, 107
 - of child, 106t, 108
 - of infant, 106t, 109
 - of newborn, 106t
- Rhythm. *See also* Arrhythmia(s).
 - agonal, 154f, 170

- idioventricular, 48, 48f, 130f, 164
 - accelerated, 49, 49f
- junctional, 43, 43f
 - accelerated, 44, 44f
- pacemaker, 66, 66f, 67f, 158f, 159f, 169, 171
- sinus, 28, 28f, 156f, 170
 - with muscle artifact, 158f, 171
 - with premature atrial contractions, 159f, 171
 - with premature junctional contractions, 157f, 170
 - with premature ventricular contractions, 141f, 149f, 156f, 166, 168, 170
 - with sinoatrial block, 162f, 172
 - with sinus pause/arrest, 138f, 166
 - with ST segment depression, 162f, 172
 - with ST segment elevation, 160f, 171
 - with U wave, 142f, 167

- Right bundle branch, 10
- Right bundle branch block, 85, 85f
- Right-sided twelve-lead electrocardiography, 19, 19f

S

- SA. *See* Sinoatrial *entries*.
- Second-degree atrioventricular block, 61, 61f, 62, 62f, 146f, 148f, 168

- Segment(s), 21
 ST, 22
 depression of, 77, 77f, 162f, 172
 elevation of, 77, 77f, 160f, 171
- Septal myocardial infarction, 82, 82f
- Sinoatrial block, 33, 33f, 162f, 172
- Sinoatrial node, 10
- Sinoatrial node arrhythmias, 28–33, 29f–33f
- Sinus arrest (sinus pause), 32, 32f, 138f, 166
- Sinus arrhythmia, 31, 31f
- Sinus bradycardia, 29, 29f, 130f, 138f, 139f, 143f, 164, 166, 167
 junctional bradycardia
 converting to, 155f, 170
 with muscle artifact, 161f, 171
- Sinus pause (sinus arrest), 32, 32f, 138f, 166
- Sinus rhythm, 28, 28f, 156f, 170
 with muscle artifact, 158f, 171
 with premature atrial contractions, 159f, 171
 with premature junctional contractions, 157f, 170
 with premature ventricular contractions, 141f, 149f, 156f, 166, 168, 170
 with sinoatrial block, 162f, 172
 with sinus pause/arrest, 138f, 166
 with ST segment depression, 162f, 172
 with ST segment elevation, 160f, 171
 with U wave, 142f, 167
- Sinus tachycardia, 30, 30f, 134f, 163f, 165, 172
- Sodium bicarbonate, as emergency cardiac medication, 98
- ST segment, 22
 depression of, 77, 77f, 162f, 172
 elevation of, 77, 77f, 160f, 171
- Stable narrow-complex tachycardia, management of, 124–128
- Stable wide-complex tachycardia, management of, 122, 123
- Supraventricular tachycardia (SVT), 38, 38f, 137f, 160f, 165, 171
 paroxysmal, 39, 39f, 136f, 165
 management of, 124
- T**
- T mnemonic, for causes of pulseless electrical activity, 117
- T wave, 22
- Tachycardia, atrial, 37, 37f
 multifocal, 35, 35f
 junctional, 45, 45f
 management of, 125

Tachycardia (*Continued*)

- monomorphic ventricular, 54, 54f, 135f, 142f, 143f, 145f, 165, 167
 - management of, 122
- multifocal atrial, 35, 35f
- narrow-complex, management of, 124–128
- paroxysmal supraventricular, 39, 39f, 136f, 165
 - management of, 124
- polymorphic ventricular, 55, 55f
 - management of, 123
- sinus, 30, 30f, 134f, 163f, 165, 172
- stable, management of, 122–128
- supraventricular, 38, 38f, 137f, 160f, 165, 171
 - paroxysmal, 39, 39f, 136f, 165
 - management of, 124
- unstable, management of, 121
- ventricular, 54, 54f, 55, 55f
 - monomorphic, 54, 54f, 135f, 142f, 143f, 145f, 165, 167
 - management of, 122
 - polymorphic, 55, 55f, 152f, 169
 - management of, 123
 - pulseless, management of, 116
- wide-complex, management of, 122, 123

- Third-degree atrioventricular block, 63, 63f, 150f, 169
- Thump, precordial, 104
- Torsade de pointes, 56, 56f, 147f, 168
- Transcutaneous pacing, 102, 103f
- Trigeminy, ventricular, 52, 52f, 156f, 170
- Triplet PVCs, 141f, 166
- Troubleshooting, in electrocardiography, 174
- Twelve-lead electrocardiography, 19, 19f, 72, 78, 78f
- Two-rescuer cardiopulmonary resuscitation, 106t

U

- U wave, 22, 142f, 167
- Unconscious patient, emergency management of
 - obstructed airway in, 112, 113, 114
- Uniform premature ventricular contraction, 51, 51f
- Universal sign, of airway obstruction, 115f
- Unstable tachycardia, management of, 121

V

- Vagal maneuver(s), 105
 - carotid sinus massage as, 104–105, 105f
- Valves of heart, 3, 3f
- Vasopressin, as emergency cardiac medication, 98
- Venous circulation, 8f

- Ventricular arrhythmias, 48–59, 48f–59f
- Ventricular bigeminy, 52, 52f, 143f, 167
- Ventricular contraction(s), premature, 50, 50f
- couplet (paired), 53, 53f, 149f, 168
 - every 2nd beat (bigeminal), 52, 52f, 143f, 167
 - every 3rd beat (trigeminal), 52, 52f, 156f, 170
 - every 4th beat (quadrigeminal), 53, 53f
 - multiform, 51, 51f
 - paired (couplet), 53, 53f, 149f, 168
 - triplet, 141f, 166
 - uniform, 51, 51f
- Ventricular fibrillation (VF), 57, 57f, 132f, 133f, 151f, 164, 169
- management of, 116
- Ventricular quadrigeminy, 53, 53f
- Ventricular tachycardia (VT), 54, 54f, 55, 55f
- monomorphic, 54, 54f, 135f, 142f, 143f, 145f, 165, 167
 - management of, 122
 - polymorphic, 55, 55f, 152f, 169
 - management of, 123
 - pulseless, management of, 116
- Ventricular trigeminy, 52, 52f, 156f, 170
- Verapamil, as emergency cardiac medication, 98–99
- VF (ventricular fibrillation), 57, 57f, 132f, 133f, 151f, 164, 169
- management of, 116
- VT (ventricular tachycardia), 54, 54f, 55, 55f
- monomorphic, 54, 54f, 135f, 142f, 143f, 145f, 165, 167
 - management of, 122
 - polymorphic, 55, 55f, 152f, 169
 - management of, 123
 - pulseless, management of, 116

W

- Wandering atrial pacemaker, 34, 34f
- Wave(s), 21
- P, 22, 26
 - Q, 22
 - R, propagation of, 73, 73f
 - T, 22
 - U, 22, 142f, 167
- Wenckebach atrioventricular block, 61, 61f
- Wide-complex tachycardia, management of, 122, 123
- Wolff-Parkinson-White (WPW) syndrome, 42, 42f
- management of, 128

Notes

Notes

Notes

Notes

Notes

