

**Learn  
ECG  
in a Day**  
**A Systematic Approach**

**Sajjan M**

*Foreword*  
**EVS Maben**

**JAYPEE**

# Learn ECG in a Day

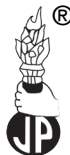

# Learn ECG in a Day

## A Systematic Approach

**Sajjan M** MBBS  
President, Dynamic Education Trust®  
Mangalore, Karnataka, India

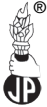*Foreword*  
**EVS Maben**



**JAYPEE BROTHERS MEDICAL PUBLISHERS (P) LTD**

---

New Delhi • Panama City • London • Dhaka • Kathmandu



**Jaypee Brothers Medical Publishers (P) Ltd.**

### Headquarters

Jaypee Brothers Medical Publishers (P) Ltd.  
4838/24, Ansari Road, Daryaganj  
New Delhi 110 002, India  
Phone: +91-11-43574357  
Fax: +91-11-43574314  
**Email: jaypee@jaypeebrothers.com**

### Overseas Offices

J.P. Medical Ltd.  
83, Victoria Street, London  
SW1H 0HW (UK)  
Phone: +44-2031708910  
Fax: +02-03-0086180  
**Email: info@jpmepub.com**

Jaypee-Highlights Medical Publishers Inc.  
City of Knowledge, Bld. 237, Clayton  
Panama City, Panama  
Phone: +507-301-0496  
Fax: +507-301-0499  
**Email: cservice@jphmedical.com**

Jaypee Brothers Medical Publishers (P) Ltd.  
17/1-B Babar Road, Block-B, Shaymali  
Mohammadpur, Dhaka-1207  
Bangladesh  
Mobile: +088019112003485  
**Email: jaypedhaka@gmail.com**

Jaypee Brothers Medical Publishers (P) Ltd.  
Shorakhute, Kathmandu  
Nepal  
Phone: +00977-9841528578  
**Email: jaypee.nepal@gmail.com**

Website: [www.jaypeebrothers.com](http://www.jaypeebrothers.com)

Website: [www.jaypeedigital.com](http://www.jaypeedigital.com)

© 2013, Jaypee Brothers Medical Publishers

All rights reserved. No part of this book may be reproduced in any form or by any means without the prior permission of the publisher.

**Inquiries for bulk sales may be solicited at:** [jaypee@jaypeebrothers.com](mailto:jaypee@jaypeebrothers.com)

This book has been published in good faith that the contents provided by the author contained herein are original, and is intended for educational purposes only. While every effort is made to ensure accuracy of information, the publisher and the author specifically disclaim any damage, liability, or loss incurred, directly or indirectly, from the use or application of any of the contents of this work. If not specifically stated, all figures and tables are courtesy of the author. Where appropriate, the readers should consult with a specialist or contact the manufacturer of the drug or device.

***Learn ECG in a Day: A Systematic Approach***

*First Edition: 2013*

ISBN 978-93-5090-086-4

*Printed at:*

**Dedicated to**

*My parents, Smt Prasadini Madappady  
and Sri Radhakrishna Madappady  
who have unconditionally been constant source of love,  
support and encouragement*



# Foreword

---

Interpretation of electrocardiograph is an essential part of cardiovascular diagnosis.

ECG is an important diagnostic tool in the diagnosis of cardiac as well as some metabolic problems. To read an ECG correctly, one has to be thorough with the basic knowledge of electromechanical system of the heart. It also requires a lot of imaginations and logic conclusions.

Teaching ECG to an undergraduate student is a challenging task for the teacher. The teacher has to use a lot of innovative ideas to kindle an interest in the student to the interpretation of ECG.

I am extremely proud of my student, Dr Sajjan, who took keen interest in my ECG classes and with his strong foundation of cardiology and multimedia skills, brought out this practical book *Learn ECG in a Day: A Systematic Approach*. He made it very simple, interesting and practical by using his own innovative ideas and methods.

Probably, this is the first book on ECG written by an internist for the benefit of not only undergraduates but also for postgraduates in General Medicine. This is also an example of how a young mind can blossom with new ideas and skills if given proper guidance and opportunity.

I wish many young brains be stimulated by this commendable work of Dr Sajjan and hope he will become a good medical teacher in the days to come.

I wish him all the best.

**EVS Maben**  
Professor and Head  
Department of Medicine  
AJ Institute of Medical Sciences  
Mangalore, Karnataka, India





# Preface

---

Present-day cardiology is undergoing immense advancements. ECG still remains the key stone in the clinical management of various cardiovascular and metabolic disorders.

Currently, interpreting ECG for medicos is a difficult task. So my efforts into this book endeavor to equip them to interpret ECG confidently and independently.

My experience with trying to understand ECG as an undergraduate made me realize that all the current books on ECG are merely a source of information. So unlike other books, the purpose of this book is to help medicos to develop a systematic approach to ECG and come to a diagnosis in a clinical set-up. However, reading the book alone will not suffice until interpreting is not put into practice.

Your opinion is valuable. I request you to give me a feedback and help in improvement of this book to my E-mail: [dynamicsajjan@gmail.com](mailto:dynamicsajjan@gmail.com).

In the end,

*“Observe, record, tabulate, and communicate. Use your five senses. Learn to see, learn to hear, learn to feel, learn to smell and know that by practice alone you can become expert.”*

—William Osler

**WISHING YOU ALL THE BEST!**

**Sajjan M**



# Acknowledgments

---

When emotions are poured, words, sometimes, are not sufficient to express our thanks and gratitude.

My sincere gratitude to Dr EVS Maben, Professor and Head, Department of Medicine, AJ Institute of Medical Sciences, who is my teacher, guide and inspiration behind this book and I would like to thank him for writing the Foreword for this book.

I extend my sincere gratitude to Shri AJ Shetty, President, Laxmi Memorial Education Trust, and Shri Prashanth Shetty, Vice-President, Laxmi Memorial Education Trust, for their support. I extend my sincere gratitude to Dr Ramesh Pai, Dean, AJIMS, Mangalore and Dr E Keshava Bhat, Professor of Medicine (Retd), Mangalore, for reviewing this book.

I extend my heartfelt gratitude to Dr Purushotham, Interventional Cardiologist, AJHRC, Mangalore, for taking his valuable time in evaluating this book and giving his expert opinion. I extend my sincere gratitude to Dr Krishna Kumar PN, MCH (CVTS), Apollo Hospitals, Chennai; Dr Naveen NS (GS), District Hospital, Madikeri, Kodagu; Dr BK Rajeshwari, MS (O & G), Bangalore Medical College, Bengaluru; Dr Praveen NS, Senior Clinical Fellow in Fetal Medicine, Royal London Hospital, London, UK; Dr Ashwini A, Clinical Fellow in Anesthesiology, Luton and Dunstable NHS Trust, UK, for taking their precious time in reviewing this book and giving their valuable views.

I would like to thank my mother, Smt Prasadini M; my father, Sri Radhakrishna M; my sister, Ms Madhura M, and all my family members for their encouragement and support.

It is my immense pleasure to pay gratitude to my teacher Mrs Olivia Periera.

Words are hard to find when it comes to highlighting the role of my friends in making this book.

I express my special thanks to Dr Nandish VS, Dr Ajey M Hegde, Dr Ravichandran K, Dr Chinthan S, Dr Anup Yogi and all my friends for their constant support.

I express my gratitude to my dearest friend and colleague Dr Rex Pais Prabhu for his constant support and aptly titling my book *Learn ECG in a Day: A Systematic Approach*.

My gratitude to Jaypee Brothers Medical Publishers (P) Ltd, New Delhi, India, for accepting my book and bringing out the contents and pictures in an elegant manner.

Last but not least, I gracefully acknowledge and thank in anticipation all readers, whom I am confident will act as a guiding force in improving and upgrading the contents of this book.



# Readers' Views

---

I am extremely happy that the 'primer' of ECG is brought over by our own product, Dr Sajjan. He has taken lots of trouble to compile this volume and I am sure it will help the house surgeons and postgraduates. I congratulate him and I wish him all the best for future.

— **Dr Ramesh Pai** MD (General Medicine)  
Dean, AJIMS, Mangalore, Karnataka

I have reviewed this book written by Dr Sajjan and I find it as an interesting ECG manual for beginners. I am thoroughly impressed with the efforts put in and the insight of the author, who is in his formative years as a doctor. This speaks of his vast ability and commitment. I wish him luck in his future endeavors.

— **Dr Purushotham** MD DNB (Cardio) DM (Cardio)  
Interventional Cardiologist, AJHRC, Mangalore, Karnataka

Dr Sajjan has written a book about basics of ECG. It is well-illustrated, useful for MBBS students, house surgeons and initial years of postgraduate students.

— **Dr E Keshava Bhat** MD (Internal Medicine)  
Mangalore, Karnataka

Dr Sajjan has done an excellent job in covering the entire subject of Electrocardiology in a simple and precise manner. The basic format and good illustrations make it an ideal choice for budding doctors.

— **Dr Krishna Kumar PN** MCH (CVTS)  
Apollo Hospitals, Chennai

I am very happy to see Dr Sajjan who has completed his MBBS recently and he has written a book on ECG which is one of the important subjects in General Medicine. I appreciate his knowledge and interest in the subject. I hope this book will be helpful for all MBBS and beginners in postgraduation. I wish him a bright future.

— **Dr Naveen NS** MBBS MS (GS)  
District Hospital Madikeri, Kodagu, Karnataka

Dr Sajjan has done a fantastic work by bringing out such a nice book on ECG. I am very happy to see him doing this great job in the beginning of his career. I hope that this book will guide all MBBS and postgraduate students. I wish him all success in future.

— **Dr BK Rajeshwari** MBBS MS (O & G)  
Bangalore Medical College, Bengaluru, Karnataka

*Learn ECG in a Day: A Systematic Approach* as title suggests is simple, clear and concise. This book takes relatively little time to read through, and guides you through basic understanding and makes interpretation a lot simpler. To touch this complicated subject (at least for me!) during internship is not easy and Dr Sajjan has done an excellent job! The book is highly recommended for the beginners to understand and interpret ECG as well as to use in a clinical setting in day-to-day practice.

— **Dr Praveen NS** MD (O & G) DNB MRCOG(London) PG Cert. in Clinical Ultrasound  
Senior Clinical Fellow in Fetal Medicine  
Royal London Hospital, London, UK

This book is simple, very easy to read and helps us to understand and interpret ECG clearly in a quick time. It is ideal for anybody who is a beginner and afraid of ECG! Dr Sajjan has worked hard to make this difficult subject much easier using a series of illustrative diagrams throughout the book. The book has an easy feel to it and I would recommend this book for anybody who wants a basic introduction to ECG.

— **Dr Ashwini A** DA  
Clinical Fellow in Anaesthesiology  
Luton and Dunstable NHS Trust, UK

# Contents

---

<b>1. History of ECG.....</b>	<b>1</b>
<b>2. Physiology of Conduction System of Heart .....</b>	<b>3</b>
<i>Rates of pacemakers</i>	3
<i>Normal spread of electrical activity in the heart</i>	4
<i>Clinical significance</i>	5
<b>3. Basics of ECG .....</b>	<b>6</b>
<i>Electrocardiography</i>	6
<b>4. ECG Leads.....</b>	<b>8</b>
<b>5. Placement of Leads .....</b>	<b>11</b>
<b>6. Normal ECG Morphology.....</b>	<b>13</b>
<i>Parts of ECG strip</i>	14
<i>Normal ECG pattern</i>	15
<i>Normal R wave progression in chest leads</i>	16
<b>7. Systematic Interpretation of ECG.....</b>	<b>17</b>
<i>Systematic interpretation guidelines for electrocardiogram</i>	17
<i>Look for standardization and lead aVR</i>	18
<i>Rate</i>	18
<i>Rhythm</i>	19
<i>Axis</i>	19
<i>P wave morphology</i>	20
<i>P-R interval</i>	24
<i>Nice to know</i>	32
<i>Hypertrophy</i>	38
<i>Bundle branch block</i>	41
<i>Nice to know</i>	46
<b>8. Arrhythmias.....</b>	<b>48</b>
<i>Disorders of impulse formation</i>	48
<i>Disorders of impulse conduction</i>	48
<i>Premature beats/Ectopic beats/Extrasystole</i>	49
<i>Nodal rhythm or junctional rhythm</i>	53
<i>SA node block</i>	54




<i>Abnormalities of rhythms</i>	56
<i>Sinus arrhythmia</i>	56
<i>Sinus bradycardia</i>	57
<i>Sinus tachycardia</i>	58
<i>Atrial Rhythms</i>	58
<i>Paroxysmal supraventricular tachycardia (PSVT)</i>	59
<i>Atrial fibrillation</i>	61
<i>Atrial flutter</i>	63
<i>Differences between atrial tachycardia, flutter and fibrillation</i>	64
<i>Ventricular rhythms</i>	64
<i>Ventricular tachycardia</i>	64
<i>Torsades De Pointes</i>	65
<i>Ventricular fibrillation</i>	66
<i>Idioventricular rhythm</i>	66
<i>Differences between ventricular tachycardia and ventricular fibrillation</i>	67
<i>Wolf-Parkinson-White (WPW) syndrome</i>	67
<b>9. Systematic Interpretation of Arrhythmias.....</b>	<b>70</b>
<b>10. Differential Diagnosis.....</b>	<b>71</b>
<i>P wave</i>	71
<i>P-R interval</i>	71
<i>Q wave</i>	72
<i>R wave</i>	72
<i>QRS complex</i>	72
<i>ST segment</i>	73
<i>T wave</i>	74
<i>U wave</i>	74
<i>Q-T interval</i>	74
<i>Bibliography .....</i>	<i>77</i>
<i>Index.....</i>	<i>79</i>

Einthoven was born in Indonesia in the year 1860. His father who was a doctor, died when Einthoven was still a child. His mother along with her children moved to Netherlands in 1870. He received a medical degree from the University of Utrecht in 1885. After that he went on to become a professor at University of Leiden in 1886.



Before Einthoven's time, it was known that electrical currents were produced by the beating of the heart, but this phenomenon could not be measured accurately without placing electrodes directly over the heart. Einthoven completed a series of prototypes of string galvanometers in 1901. The device used a very thin filament of conductive wire passing between very strong electromagnets. The electromagnetic field would cause the string to move when current was passed through the filament. This string would cast a shadow on a moving role of photographic paper when a light was shone.



**Fig.1.1:** Photograph of a complete electrocardiography showing the way in which the electrodes are attached to the patient. In this case the hands and one of the feet being immersed in jars of salt solution

*"There are two ways to live: you can live as if nothing is a miracle; you can live as if everything is a miracle."*  
—Albert Einstein

The original machine required cooling water for the powerful electromagnets. It required 5 people to operate it and weighed around 600 lb. This device increased the sensitivity of the standard galvanometer so that the electrical activity of the heart could be measured despite the insulation of flesh and bones.

Much of the terminology used in describing an EKG originated with Einthoven. His assignment of the letters P, Q, R, S and T to the various deflections is still used. The term Einthoven's triangle is named after him.

Einthoven went on to describe the electrocardiographic features of a number of cardiovascular disorders after his development of string galvanometer. Later Einthoven studied the acoustics, particularly heart sounds which he researched with Dr P Battaerd.

He died in Leiden, Netherlands and is buried in the graveyard of the Reformed Church at Haarlemmerstraatweg in Oegstgeest.

# Physiology of Conduction System of Heart

The conductive system of the heart consists of five specialized tissues.

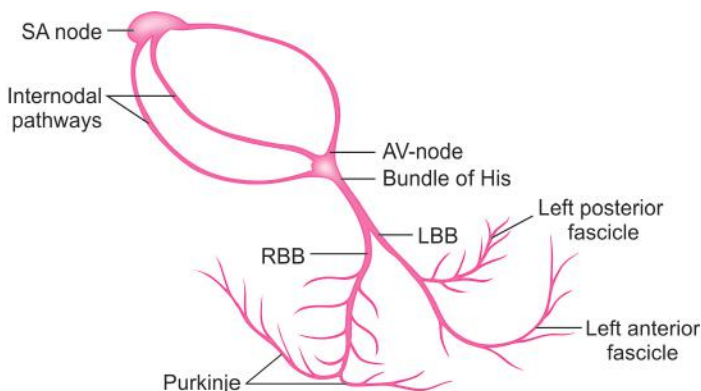
1. Sinoatrial node (SA node)
2. Atrioventricular node (AV node)
3. Bundle of His.
4. Left bundle branch (LBB) and right bundle branch (RBB)
5. Purkinje fibers.

As impulses arise in SA node and traverse through atria, they cause depolarization of the atria. From the atria impulses reach AV node, where there is some delay. This delay will allow the atria to contract and pump blood into the ventricles. This impulse is later spread along bundle of His, left and right bundle branch and finally, through Purkinje fibers causing ventricular depolarization.

The dominant pacemaker is SA node. Atrial cells, AV node, bundle of His, bundle branch, Purkinje fibers and myocardial cells are the other pacemaker sites. When SA node fails, they can initiate impulse at a slow rate.

## RATES OF PACEMAKERS

- |                 |              |
|-----------------|--------------|
| 1. SA node      | 60 – 100 bpm |
| 2. Atrial cells | 55 – 60 bpm  |
| 3. AV node      | 45 – 50 bpm  |



*"Don't wait. The time will never be just right."*

*—Napolean Hill*

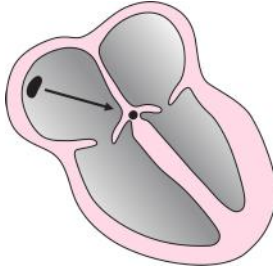
**4** *Learn ECG in a Day: A Systematic Approach*

---

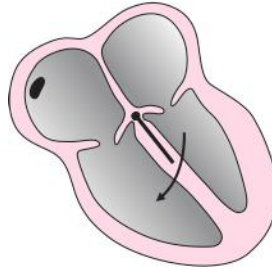
4. Bundle of His	40 – 45 bpm
5. Bundle branch	40 – 45 bpm
6. Purkinje cells	35 – 40 bpm
7. Myocardial cells	30 – 35 bpm

**NORMAL SPREAD OF ELECTRICAL ACTIVITY IN THE HEART**

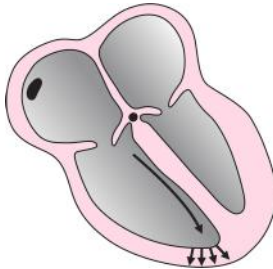---



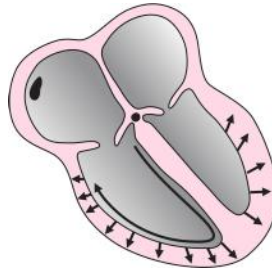
**A.** Atrial depolarization



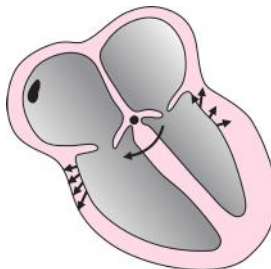
**B.** Septal depolarization from left to right



**C.** Depolarization of antero-septal region of the ventricular myocardium



**D.** Depolarization of major portion of ventricular myocardium from endocardial surface to epicardium



**E.** Late depolarization of posterobasal portion of the left ventricle and pulmonary conus

## CLINICAL SIGNIFICANCE

Any disturbance in the sequence of stimulation of this specialized tissue leads to rhythmic disturbances called arrhythmias or conduction abnormality called heart block.

*“There are three kinds of people; those that make things happen, those that watch things happen and those who don’t know what’s happening.”* —Bible

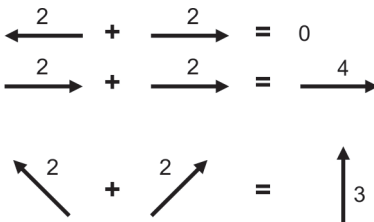
**ELECTROCARDIOGRAPHY**

Electrocardiography is the recording of the electrical impulses that are generated in the heart. These impulses initiate the contraction of cardiac muscles. The term vector is used to describe these electrical impulses. The vector is a diagrammatic way to show the strength and the direction of the electrical impulse. The vectors add up when they are going in the same direction and they get cancelled if they point in the opposite directions. But in case if they are at an angle to each other, they add or subtract energy and change their resultant direction of flow.

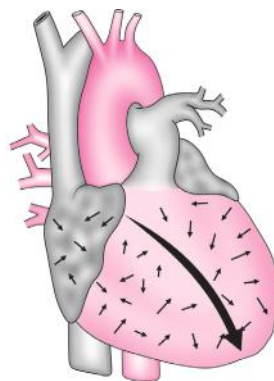
Now just imagine, how many cells the heart is composed of?... Millions of cells right! So there are millions of vectors formed. When these millions of vectors add up, subtract or change direction, we finally get a resultant vector! This resultant vector is known as electrical axis of the ventricle. Therefore, ECG is the measurement of these vectors that pass under the electrode.

Now let's refine ECG, it is a graphical representation of the electrical movement of the main vector passing under an electrode or a lead.

Electrodes are the sensing devices that pick up the electrical activity occurring under it. When a positive impulse is moving away from the electrode, the ECG machine converts it into a negative wave. When a positive impulse is moving towards the electrode, the ECG machine converts it into a positive wave.



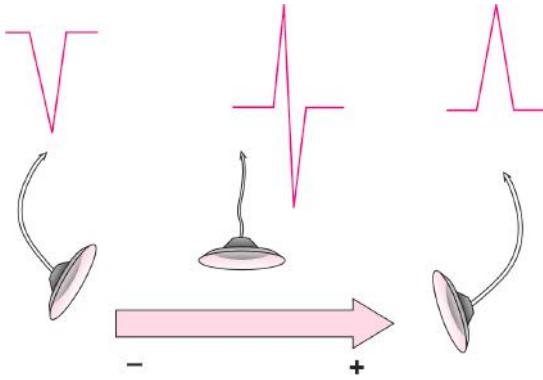
**Fig. 3.1:** Examples for adding vector



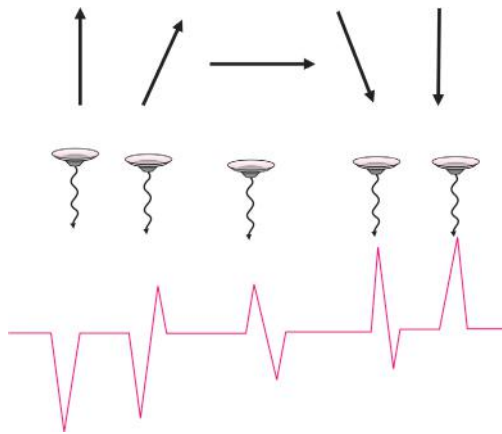
**Fig. 3.2:** Sum of all the ventricular vectors is equal to electrical axis

*“Be more dedicated to making solid achievements than in running after swift but synthetic happiness.”*  
 —Abdul Kalam

But when the electrode is in the middle of the vector, the ECG machine converts it into positive deflection for the amount of energy that is coming towards the electrode and the negative wave for the amount of energy that is going away from the electrode.



**Fig. 3.3:** Three different ECG's resulting from the same vector due to the different lead placement



**Fig. 3.4:** Different vectors showing different deflections in ECG wave patterns

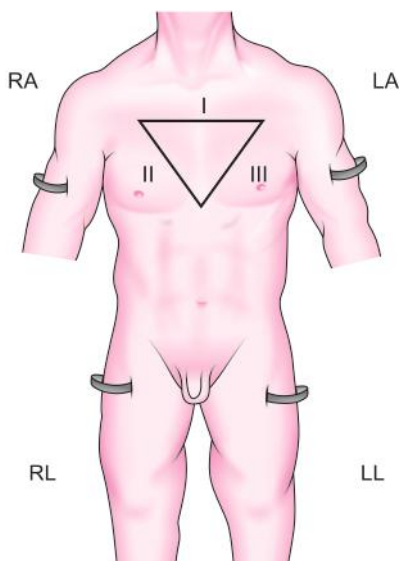
*"Edison failed 10,000 times before he made the electric light". Do not be discouraged if you fail a few times.*  
—Napoleon Hill



There are twelve leads consisting of six limb leads (I, II, III, aVR, aVL and aVF) and six chest leads (V1–V6). The limb leads consists of standard bipolar (I, II and III) and augmented (aVR, aVL and aVF) leads. The bipolar leads were so named because they record the difference in electrical voltage between two extremities.

For example:

- Lead I:** Records the difference in voltage between the left arm and the right arm electrodes.
- Lead II:** The difference in voltage between the left leg and the right arm electrodes.
- Lead III:** The difference in voltage between the left leg and the left arm electrodes.



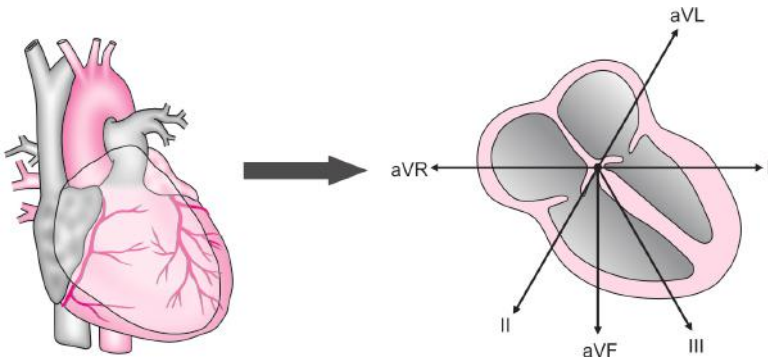
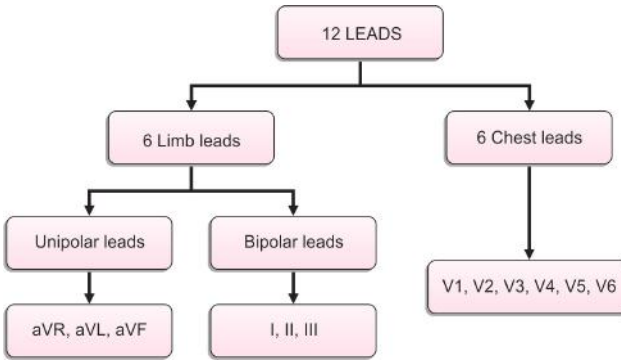
**Fig. 4.1:** Leads

In augmented limb leads, the abbreviation ‘a’ refers to augmented; V to voltage; R, L and F to right arm, left arm and left foot (leg) respectively. They record the electrical voltage of corresponding extremity.

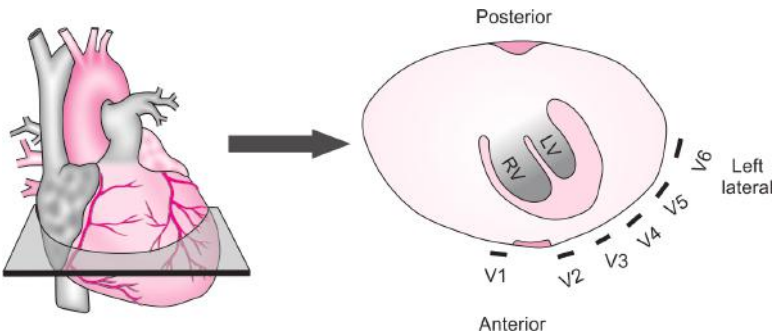
*“Success means having the courage, the determination, and the will to become the person you believe you were meant to be.”*

—George Sheehan

Flow Chart 4.1: LEADS



**Fig. 4.2:** Limb leads are placed in such a way that they bisect the heart at the center in the coronal plane



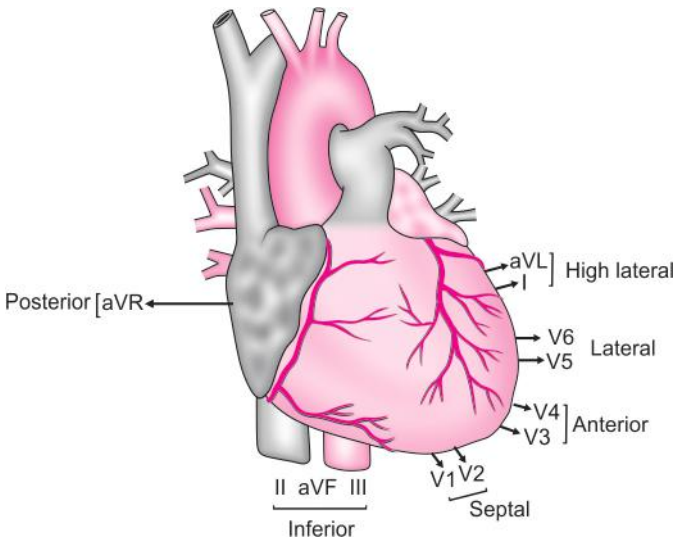
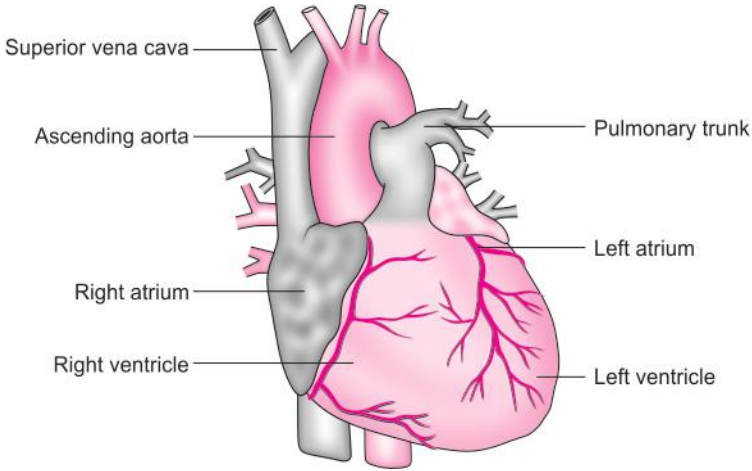
**Fig. 4.3:** Chest leads are placed in such a way that they bisect the heart in the horizontal plane

*“Failure comes only when we forget our ideals and objectives and principles.”*

*—Jawaharlal Nehru*

**Table 4.1: Relationship of 12 Leads to Heart**

V1–V2	Septal wall
V3–V4	Anterior wall
I, aVL, V5–V6	Lateral wall
II, III, aVF	Inferior wall



**Fig. 4.4:** Relationship of 12 Leads to heart

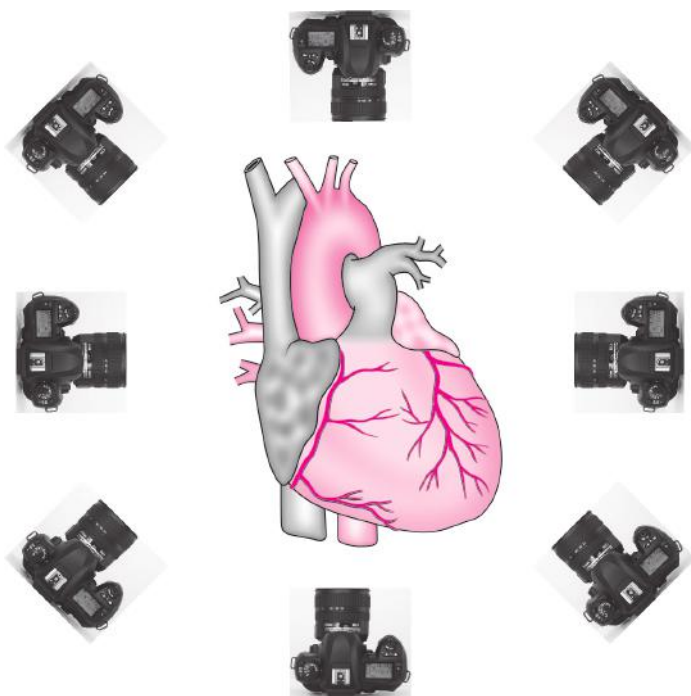
*“Take time to deliberate, but when the time for action has arrived, stop thinking and go in.”*  
 —Napoleon Bonaparte

# Chapter 5

## Placement of Leads

Before placing the leads, let us understand what leads are. Why they are placed at that particular landmarks? The leads are electrodes which pick up electrical activity of the cell (i.e. the vectors generated by the cell) and the ECG machine converts them to waves.

Now let's imagine that leads are camera, which are kept at different angles from the heart. These cameras take pictures of the heart in those angles in which they have been placed. When we arrange all the photographs which are taken at different angles from the heart, we get a 3D (3-dimensional) picture of the heart. Wow! Isn't it amazing? You are actually looking at a 3D image of the heart represented by the ECG strip.



**Fig. 5.1:** Leads (cameras) view at different angles from the heart

*"You have to dream before your dreams can come true."*

*—Abdul Kalam*

Placement of limb leads:  
Right arm (RA)  
Left arm (LA)  
Right leg (RL)  
Left leg (LL)

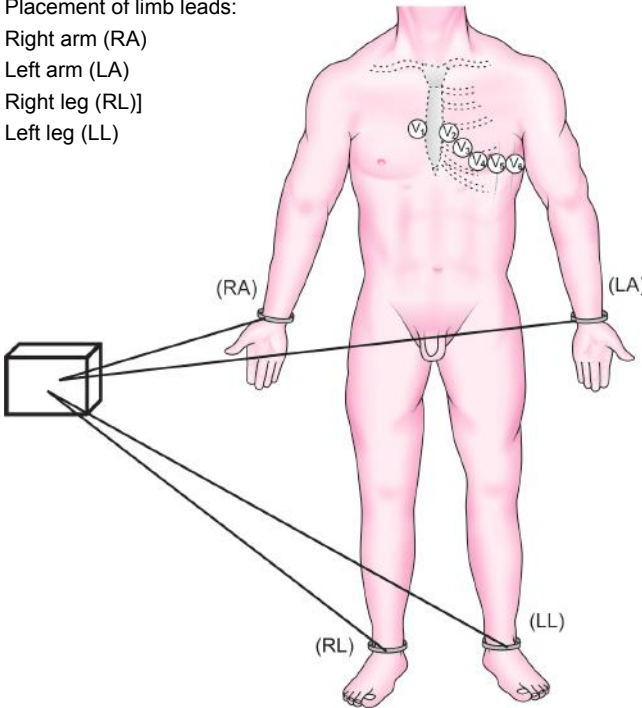


Fig. 5.2: Placement of limb leads

### Placement of Chest Leads

- V1- fourth intercostal space at the right sternal border
- V2- fourth intercostal space at the left sternal border
- V4- fifth intercostal space at mid clavicular line
- V3- midway between V2 and V4
- V5- at the same horizontal level as V4 in the anterior axillary line
- V6- at the same horizontal level as V4 in the mid axillary line.

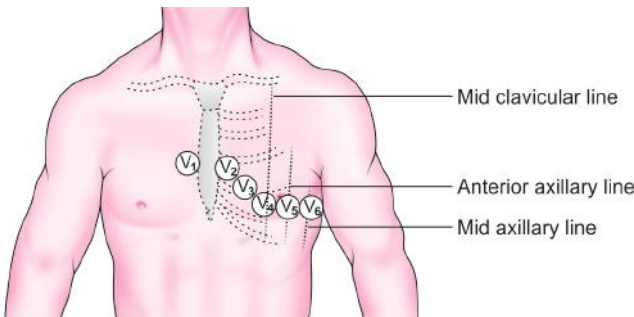



Fig. 5.3: Placement of chest leads

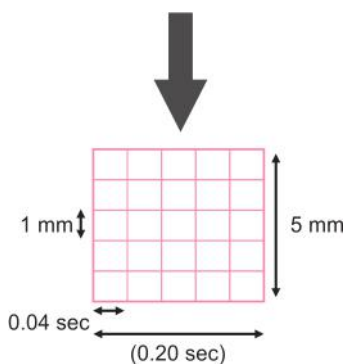
*“Be the change you want to see in the world.”*

*—Mahatma Gandhi*

# Normal ECG Morphology



**Fig. 6.1:** ECG paper



**Fig. 6.2:** Height is measured in millimeters (mm) and width in milliseconds (ms)

*“If I have the belief that I can do it, I shall surely acquire the capacity to do it even if I may not have it at the beginning.”*

—Mahatma Gandhi

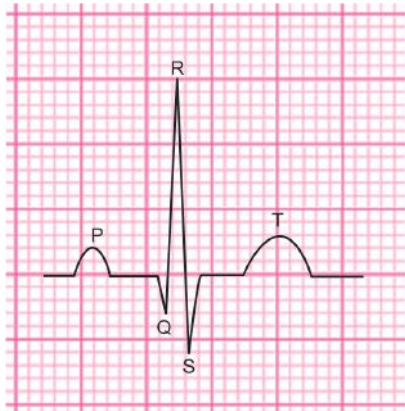


Fig. 6.3: ECG wave morphology

P wave-atrial depolarization

QRS complex-ventricular depolarization

ST segment, T wave-ventricular repolarization

For better understanding:

- 1 mm = 0.04 sec
- 2 mm = 0.08 sec
- 3 mm = 0.12 sec
- 4 mm = 0.16 sec
- 5 mm = 0.20 sec
- 10 mm = 0.40 sec
- 15 mm = 0.60 sec
- 20 mm = 0.80 sec
- 25 mm = 1.00 sec

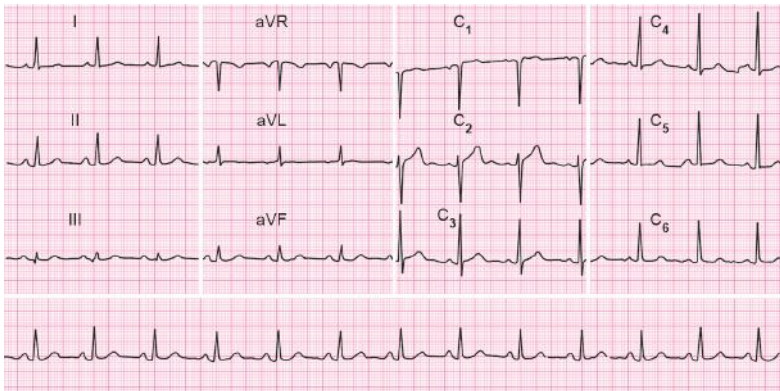


Fig. 6.4: Parts of ECG strip

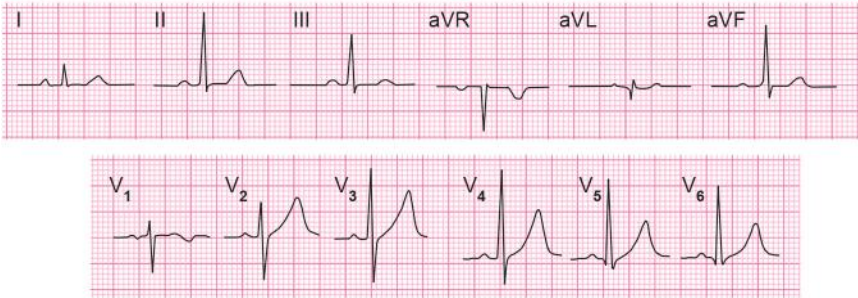
*“The mind acts like an enemy for those who do not control it.”*

*—Bhagavad Gita*

Lateral	Posterior	Septal	Anterior
Inferior	Lateral	Septal	Lateral
Inferior	Inferior	Anterior	Lateral

### NORMAL ECG PATTERN

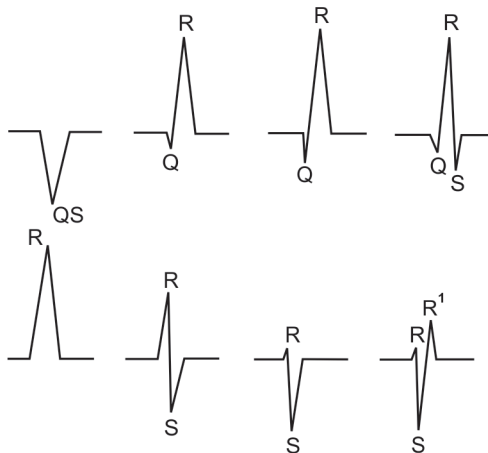
Try labeling P, QRS and T wave in this ECG .



**Fig. 6.5:** Normal ECG patterns

### How to Name the QRS Complex?

- The first negative deflection (below the base line) is called Q wave.
- The first positive deflection is called R wave. If there is a second positive complex, it is called as R' (R prime).
- The negative deflection following the R wave is S wave.
- This three rules are applicable to all leads except for aVR.



**Fig. 6.6:** Different patterns of QRS waves

*“Do not go where the path may lead, go instead where there is no path and leave a trail.”*  
 —Ralph Waldo Emerson



## NORMAL R WAVE PROGRESSION IN CHEST LEADS

As we move in the direction of electrically predominant left ventricle, R wave tends to become relatively larger and S wave relatively smaller. Generally, in V3 or V4 the ratio of R wave to S wave becomes 1. This is called transition zone. If transition occurs as early as V2, then it is called early transition and if transition occurs as late as V5, it is called late transition.

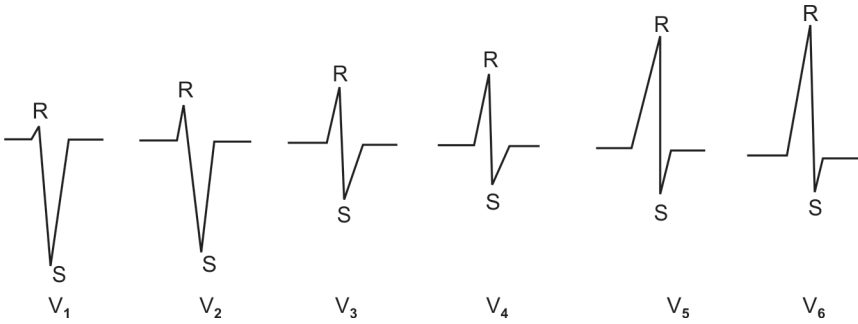


Fig. 6.7: Normal R wave progression in chest leads

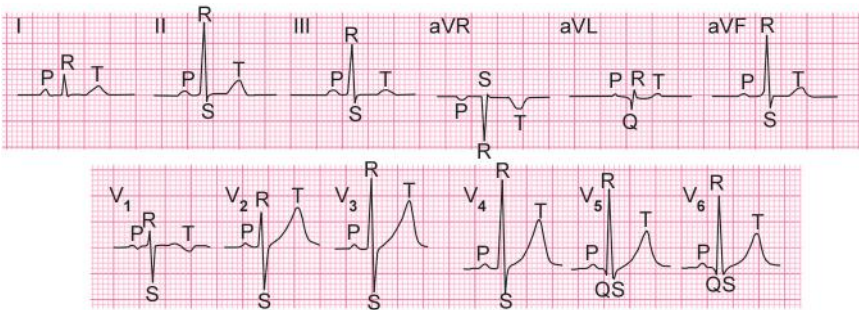


Fig. 6.8: Labeled normal ECG patterns

*“When we accept tough jobs as a challenge and wade into them with joy and enthusiasm, miracles can happen.”*  
—Arland Gilbert

**SYSTEMATIC INTERPRETATION GUIDELINES  
FOR ELECTROCARDIOGRAM**

1. Look for standardization and lead aVR
2. Rate
3. Rhythm
  - I. Regular
  - II. Irregular
4. Axis
  - I. Normal
  - II. Right axis deviation
  - III. Left axis deviation
5. P wave morphology
  - I. P-Mitrale
  - II. P-Pulmonary
6. P-R interval
  - I. First degree heart block
  - II. Second degree heart block
  - III. Third degree heart block
7. ST segment and T wave abnormality
  - I. S-T segment elevation
  - II. S-T segment depression
  - III. T wave inversion
8. Hypertrophy
  - I. Left ventricular hypertrophy
  - II. Right ventricular hypertrophy
9. Bundle branch block
  - I. Right bundle branch block
  - II. Left bundle branch block.

*“In the middle of difficulty lies opportunity.”*

*—Albert Einstein*

## 1. Look for Standardization and Lead aVR

At the end of each ECG strip, a standardization mark is present which should be 10 mm in height 0.20 second in width (5 mm).

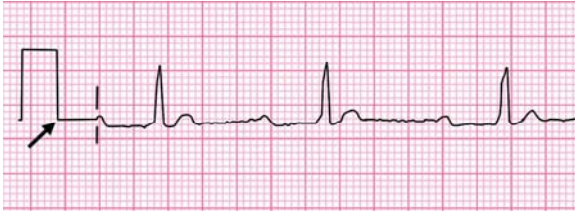

Fig. 7.1: Standardization mark

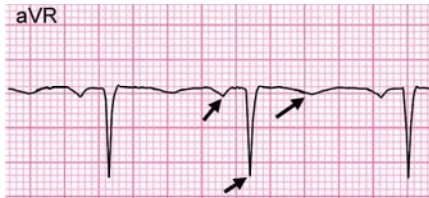


Fig. 7.2: Lead aVR showing inverted P, QRS & T

All waves should be inverted in lead aVR unless the limb leads are wrongly connected except in dextrocardia.

## 2. Rate

Concept

0.04 second = 1 small square

0.20 second = 5 small squares (1 large square)

So, 1 second = 25 small squares or 5 large squares

So 1 minute =  $25 \times 60 = 1500$  small squares or  $5 \times 60 = 300$  large squares.

If the rhythm is regular,

Rate =  $1500/\text{R-R interval}$

Normal heart rate: 60–100 (i.e. 15–25 small squares)

1. In this ECG, R-R interval measures 15 small squares

Rate =  $1500/15 = 100$

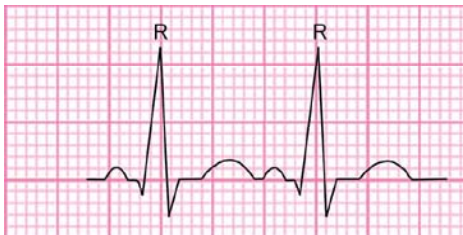
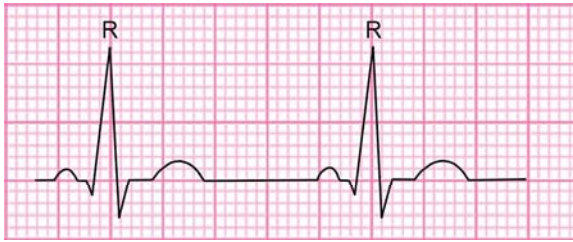
Fig. 7.3: R-R interval

*“Every person is responsible for his own looks after 40.”*

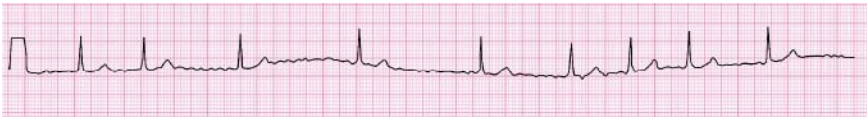—Abraham Lincoln

2. If R-R interval measures 25 small squares,  
 Rate =  $1500/25 = 60$   
 Normal heart rate = 60–100



**Fig. 7.4:** R-R interval

If the rhythm is irregular each R-R interval will be different, in that case the number of R waves in the 30 large squares (6 seconds) should be counted and multiply the number by 10 to get an approximate heart rate per minute.



**Fig. 7.5:** Irregular R-R interval

### 3. Rhythm

Features of sinus rhythm are:

- Each P wave should be followed by QRS complex.
- P-R interval should be normal and constant.
- P wave morphology should be normal.
- R-R interval should be equal, if it is irregular, then it is called irregular rhythm.

*Causes of Irregular Rhythm*

1. *Physiological:* Sinus arrhythmia
2. *Pathological:*
  - Atrial fibrillation
  - Ventricular fibrillation

### 4. Axis

Look at Lead I and Lead aVF for electrical axis of the heart. In both these leads, normally, QRS complex is upwards.

*“Don’t worry when you are not recognized, but strive to be worthy of recognition.”*

*—Abraham Lincoln*


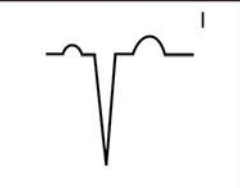



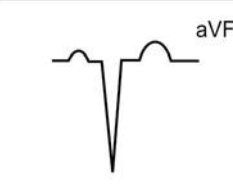
Normal axis	Right axis deviation	Left axis deviation
		
		
Pneumonic	Right reaches	Left leaves

Fig. 7.6: Comparison of lead I with aVF to get the axis

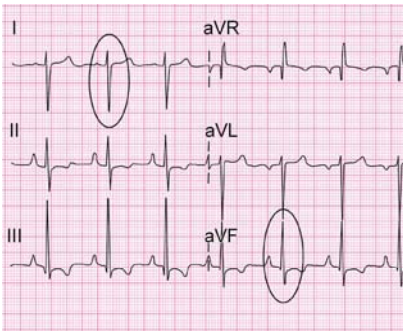


Fig. 7.7: Right axis deviation

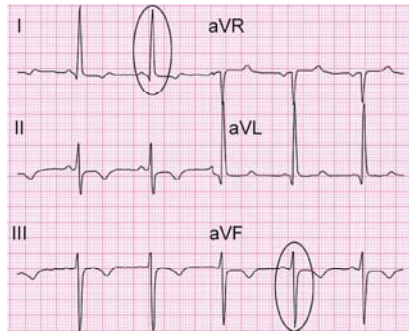


Fig. 7.8: Left axis deviation

Causes

Right axis deviation	Left axis deviation
Right ventricular hypertrophy	Left ventricular hypertrophy
Right bundle branch block	Left bundle branch block
Left posterior hemiblock	Left anterior hemiblock
Emphysema and cor pulmonale	Wolf-Parkinson-White syndrome
Falot's tetralogy	Hypertrophic cardiomyopathy

5. P Wave Morphology

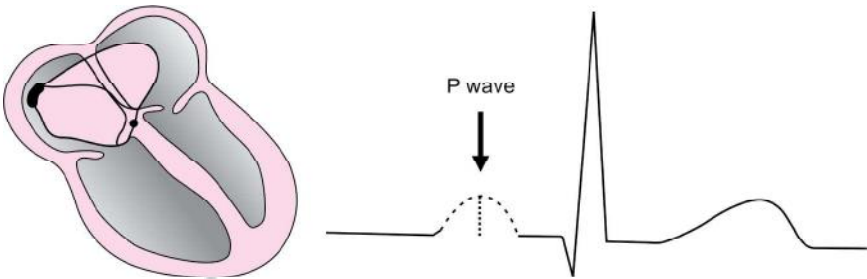
The P wave represents depolarization of right and left atria.

This process takes 0.08–0.11seconds (2–3 mm)

P wave morphology is best appreciated in lead II and contrast in lead V1.

*“If you do not hope, you will not find what is beyond your hopes.”*

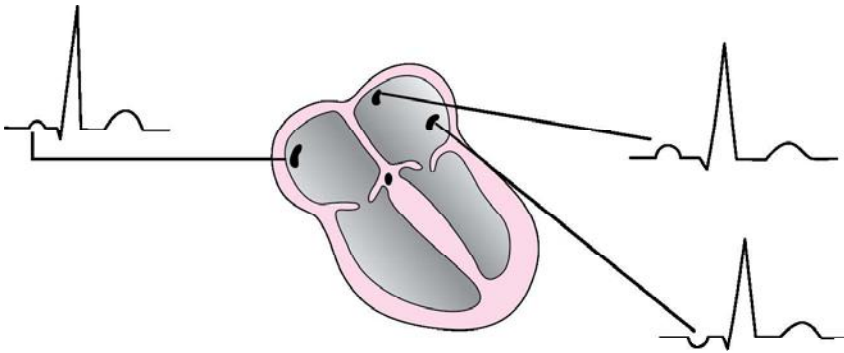
—St. Clement of Alexandria



**Fig. 7.9:** P wave morphology

The SA node starts depolarization in right atrium so the former part of the P wave is contributed by right atrium, the latter part is contributed by left atrium.

P wave morphology varies in any lead depending on the location of the area acting as the pacemaker.



**Fig. 7.10:** Different morphology of P wave depending on the location of the area acting as pacemaker

## P Mitrale or Left Atrial Enlargement

### Criteria

The width of P wave in lead II is more than 0.12 seconds and notched (M shaped) the gap between the two peaks should be greater than or equal to 0.04 seconds.

### Concept

Here left atrium is enlarged and the duration taken to depolarize the left atria is comparatively more than the right atria. Therefore, we see a notched and wide P wave.

*"A person who never made a mistake never tried anything new."*

*—Abraham Lincoln*

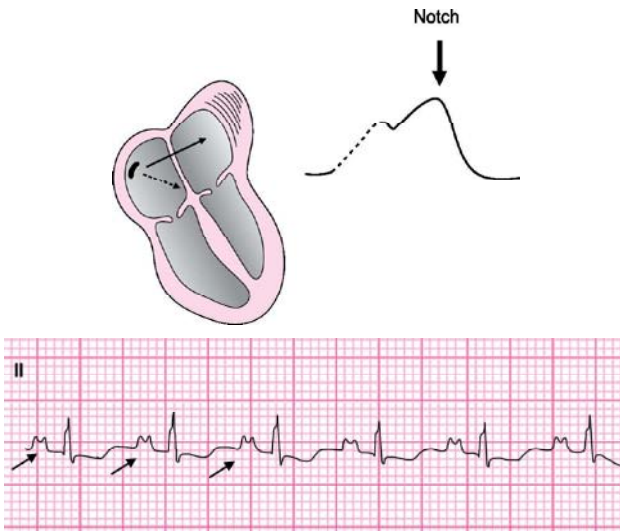


Fig. 7.11: P mitrale

### P Pulmonale or Right Atrial Enlargement

#### Criteria

The P wave is peaked and the amplitude  $> 2\frac{1}{2}$  mm in lead II.

#### Concept

Here there is right atrial enlargement and the duration required for right atrium to depolarize is longer, hence tall P wave.

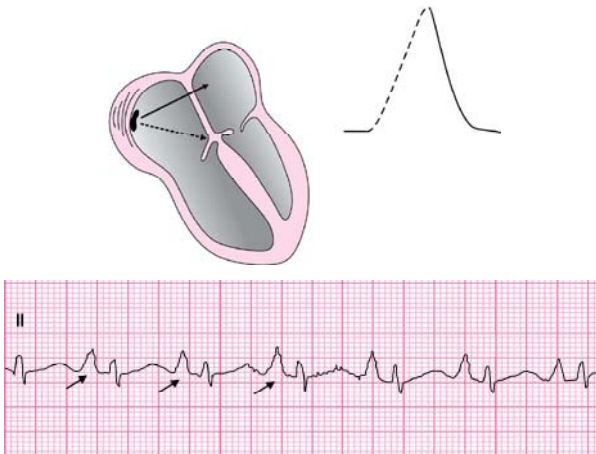


Fig. 7.12: P pulmonale

*“Without friends no one would choose to live.”*

*—Albert Einstein*

## Causes

<i>Right atrial abnormality</i>	<i>Left atrial abnormality</i>
Bronchial asthma	Mitral stenosis
Emphysema	Mitral regurgitation
Pulmonary embolism	Aortic stenosis
Tetralogy of fallot	
Atrial septal defect	
Pulmonic valve stenosis	

## Inverted P Wave

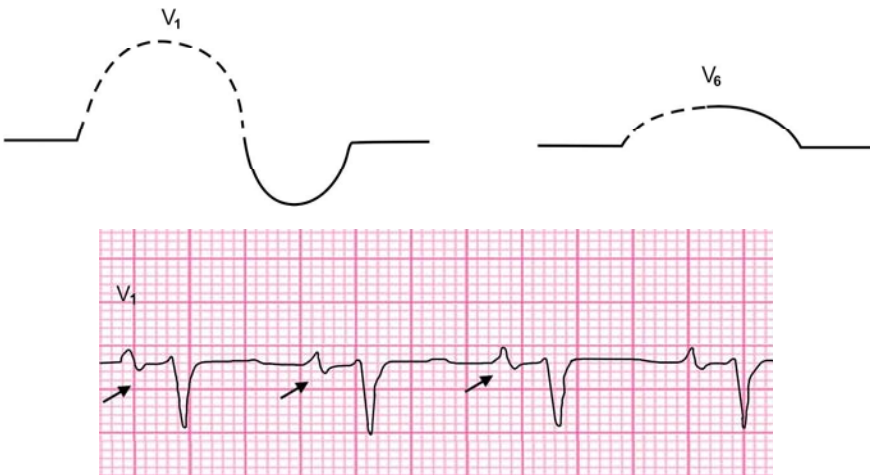
Inverted P waves are found when the pacing or the initial impulse originates at or below the AV node. Therefore, depolarization wave of the atrium will spread in a retrograde manner causing inverted P wave. Inverted P wave indicates nodal rhythm or junctional rhythm and idioventricular rhythm.

## Intra-atrial Conduction Delay (IACD)

Indicates non-specific conduction problem in atria usually, the problem is caused by atrial enlargement but there is no much enlargement to form P mitrale or P pulmonale pattern. However, biphasic P wave in V<sub>1</sub> and V<sub>6</sub> helps to differentiate between left and right atrial enlargement.

## Criteria

In V<sub>1</sub> if the first half of biphasic P wave is taller than the first half of the P wave in V<sub>6</sub>, then it is likely to be right atrial enlargement.



**Fig. 7.13:** Intra-atrial conduction delay in right atrial enlargement

*“Opportunity is missed by most people because it is dressed in overalls and looks like work.”*

—Thomas A Edison



Criteria

In V1 if the second half of P wave is wider and deeper than 0.4 second (1 mm), then it is likely to be left atrial enlargement.

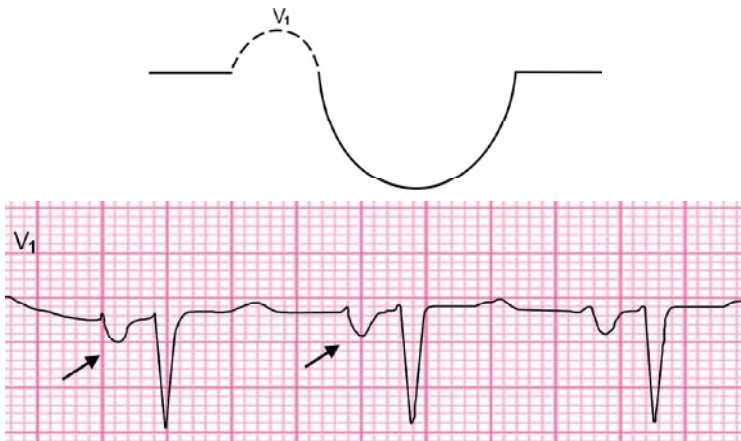


Fig. 7.14: Intra-atrial conduction delay in left atrial enlargement

6. P-R Interval

- Normal P-R interval is 0.12–0.20 seconds (3–5 mm).
- P-R interval is best appreciated in rhythm strip.

Short P-R interval:

Less than 0.11 seconds (3 mm)

1. Retrograde junctional P wave
2. Lown Ganong-Levine syndrome (L-G-L)
3. Wolff-Parkinson-White pattern and syndrome (WPW)

Prolonged P-R interval:

More than 0.20 seconds (5 mm).

1. AV block.
  - First degree AV block

Criteria

Here PR interval is prolonged beyond 0.20 sec. and remains constant from beat to beat.

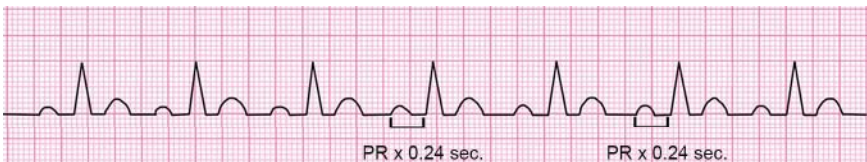

Fig. 7.15: First degree AV block

*“You can never cross the ocean unless you have the courage to lose sight of the shore.”*  
—Christopher Columbus

## Second Degree AV Block

Mobitz type I block (Wenckebach phenomena)

Criteria

There is progressive lengthening of P-R interval followed by a drop beat.

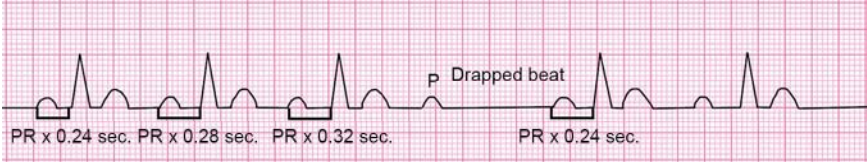


Fig. 7.16: Mobitz type I block

## Mobitz Type II Block

Criteria

There is no progressive lengthening of P-R interval, followed by a drop beat.

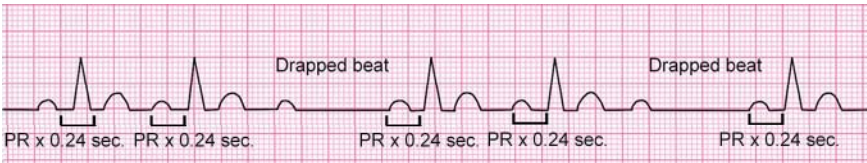


Fig. 7.17: Mobitz type II block

*Complications*

1. Complete heart block.
2. Heart failure.
3. Stokes-Adams attacks.

## Third Degree AV Block

Criteria

Here P wave has no relation to QRS complex. It always has more P waves than QRS complex.

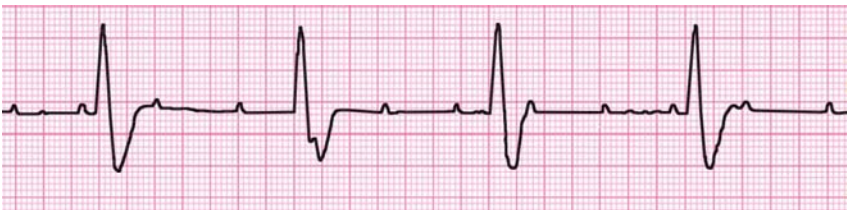

Fig. 7.18: Third degree AV block

*“Many of life’s failures are people who had not realized how close they were to success when they gave up.”*

—Thomas A Edison

Clinical Features

1. Blackout, dizziness or sudden loss of consciousness or syncope (Stoke-Adam’s attack)
2. Pulse: Usually bradycardia < 40 beats per minute.
3. Blood pressure: High pulse pressure (high systolic normal diastolic)
4. JVP: Cannon waves (large a wave) may be present.

QRS Wave Morphology

QRS complex represents ventricular depolarization.

Normal duration: < 0.12 seconds

Acute Myocardial Infarction

Flow Chart 7.1: Pathology of acute myocardial infarction

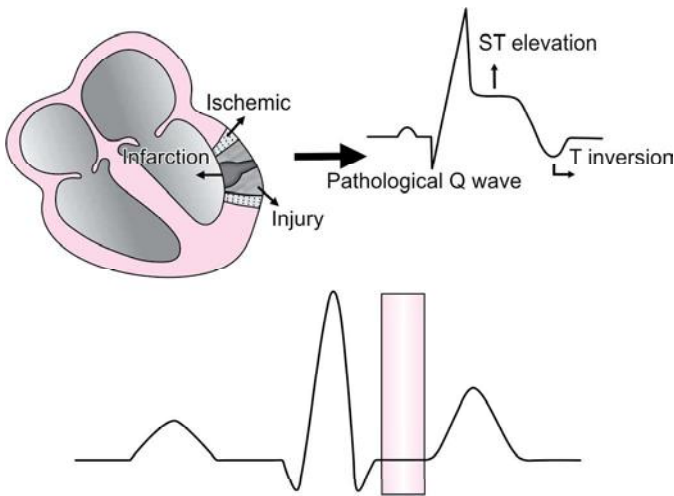
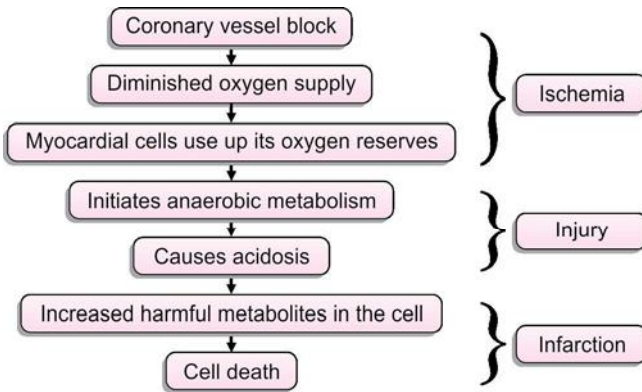


Fig. 7.19: ST segment

“Yesterday is history. Tomorrow is mystery. And today? Today is a gift that’s why they call it the present.”  
—Sin Vye St Tan

### Criteria

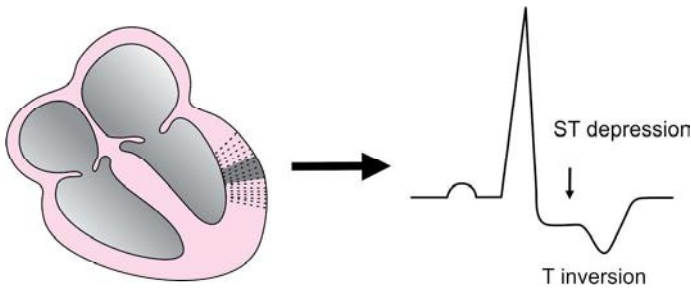
1. Elevation of ST segment indicates zone of injury, diagnosis is supported by reciprocal changes, ST depression in the leads facing the opposite wall.
2. Inverted T wave indicates effect of ischemic surroundings.
3. Pathological Q wave- more than 1/3 the total height of the QRS and width more than 0.03 seconds, indicates zone of infarction or dead muscle.
4. Note: ST elevation of more than 1 mm from the base line in limb leads and more than 2 mm in chest leads in two or more leads facing same area is pathological.

## Concepts Behind Zones of MI

### Ischemia

It affects a wedge shaped section of the heart, the apex facing the epicardium and the base facing the endocardium.

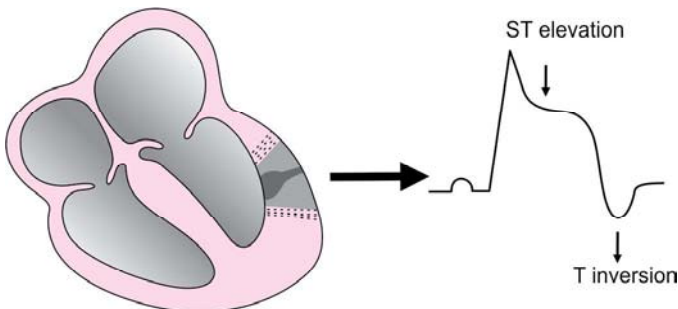
This area is more negative than the surrounding normal tissue leading to ST depression. Inverted T waves are seen in ischemia because repolarization occurs along the abnormal pathway.



**Fig. 7.20:** Ischemia

### Injury

As the zone of injury does not depolarize completely it remains more positive than the surrounding tissue leading to ST segment elevation.



**Fig. 7.21:** Injury

*"It's not the size of the dog in the fight, but the size of the fight in the dog."*

—Mark Twain

Infarction

Indicates dead tissue. As the tissue is dead they do not generate any action potential and so it is electrically neutral. This electrically neutral area acts like a window in the myocardial wall. Through which an electrode can see the opposite wall. The positive vector of the other wall heading away from the electrode produces the pathological Q wave. The formation of the rest of the complex results from the surrounding zone of infarcts and injury.

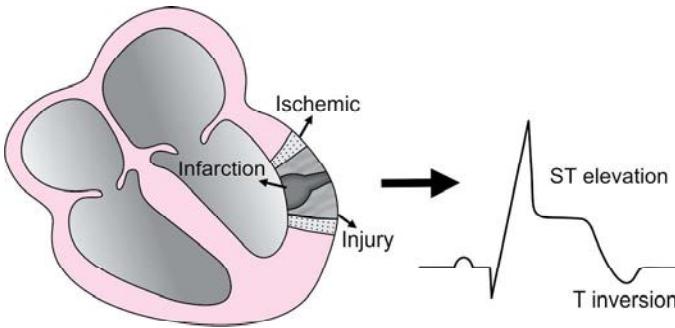
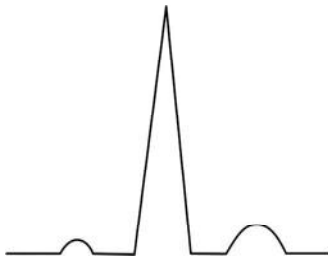


Fig. 7.22: Infarction

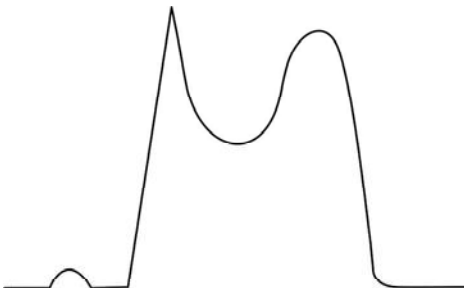
Study of MI events in chronological order:

1. Normal wave tracing



ST segment	Normal
T wave	Normal
Q wave	Normal

2. Acute onset MI (early pattern, hours after infarction)

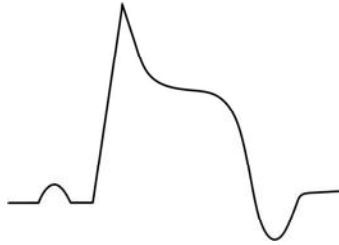


ST segment	Elevated
T wave	Tall
Q wave	Normal

*"It's never too late to be what you might have been."*

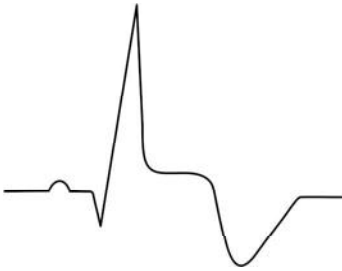—George Eliot

3. Late pattern, may occur hours to few days



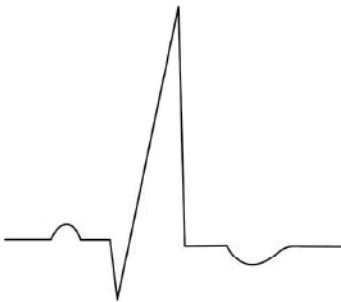
ST segment	Elevated
T wave	Inversion
Q wave	Normal

4. Late established pattern, many days to weeks



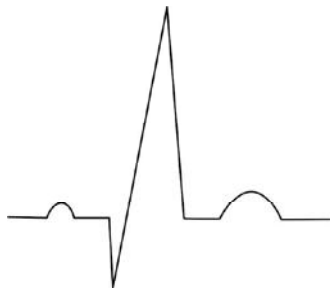ST segment	Elevated
T wave	Deeply inverted
Q wave	Deep and wide Q wave starts appearing

5. Very late pattern



ST segment	Almost becomes normal
T wave	Gradually becomes flat
Q wave	Fully developed

6. May occur many months to years after infarction



ST segment	Normal
T wave	Normal
Q wave	Persists

*“Opportunity... often it comes disguised in the form of misfortune, or temporary defeat.”*  
 —Napoleon Hill

Inferior Wall MI:

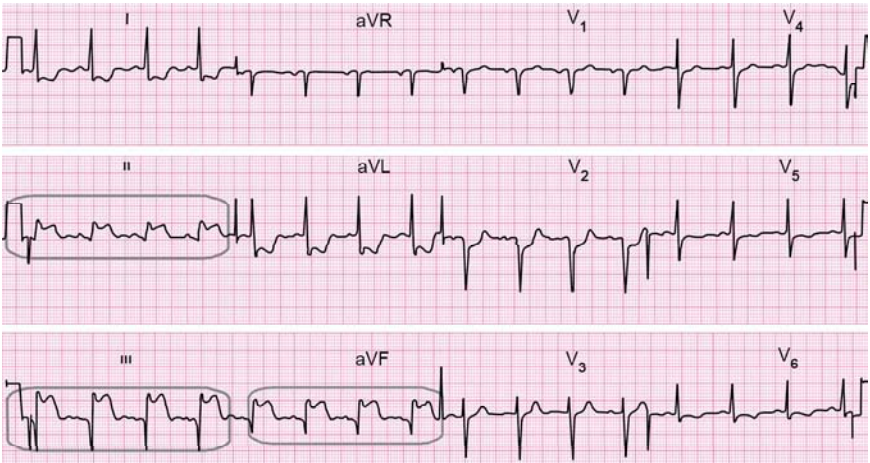


Fig. 7.23: Inferior wall MI

ST elevation is seen in leads II, III, aVF and reciprocal ST depression changes in I, aVL, V5, V6.

Lateral	Posterior	Septal	Anterior
Inferior	Lateral	Septal	Lateral
Inferior	Inferior	Anterior	Lateral

Anterolateral wall MI:

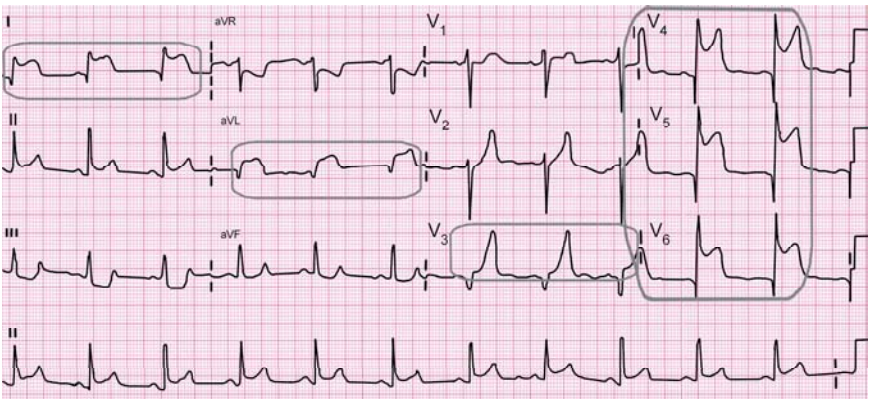


Fig. 7.24: Anterolateral wall MI

ST elevation is seen in leads I, aVL, V3, V4, V5, V6 and reciprocal ST depression in II, III, aVF.

*“Determine that the thing can and shall be done, and then we shall find the way.”*  
—Abraham Lincoln

Lateral	Posterior	Septal	Anterior
Inferior	Lateral	Septal	Lateral
Inferior	Inferior	Anterior	Lateral

In anterolateral MI, ST segment changes are seen in the following leads: I, aVL, V3, V4, V5, V6. In inferior wall MI, ST segment changes are seen in the following lead occurs: II, III, aVF. This also indicates that in anterolateral wall MI leads II, III and aVF will show ST segment depression with tall T wave (these are the reciprocal changes) OR in inferior wall MI, leads I, aVL, V3, V4, V5, V6 will show ST segment depression with tall wave (these are the reciprocal changes). When ischemic changes occur in V1, V2, V3, V4, V5, V6 they indicate extensive anterior wall infarction.

### Concepts Behind Reciprocal Changes in Acute MI

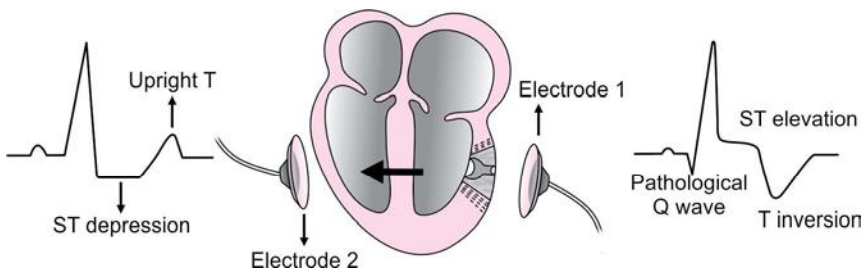
It occurs when two electrodes look at the same acute MI from opposite angles, for example:

#### Electrode 1

1. When this electrode views through window of electrically neutral zone, it records the vector heading away from it, giving rise to pathological Q waves.
2. Then it records other vectors which contribute to the formation of other complexes.
3. The positive zone of injury causes ST elevation.
4. Repolarization abnormality formed by the area of ischemia and injury causes T wave inversion.

#### Electrode 2

1. It originally sees the vector heading towards it, giving rise to tall R waves.
2. Then it records the zone of injury leading to ST segment depression and zone of ischemia leading to upright T wave.



**Fig. 7.25:** Concepts behind reciprocal changes in acute MI

*"There is no self-made man you will reach your goals only with the help of others."*  
—George Shinn



### Non ST-Elevation Myocardial Infarction (NSTEMI)

There will be ST segment depression and flattening of T wave or T wave inversion in a patient without left ventricular hypertrophy which indicates MI.

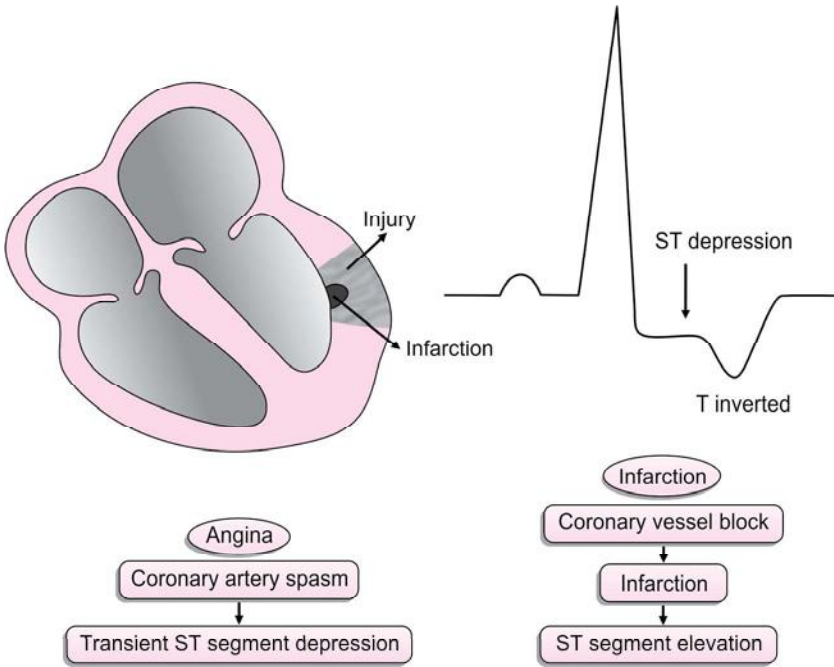


Fig. 7.26: Non-ST elevation myocardial infarction

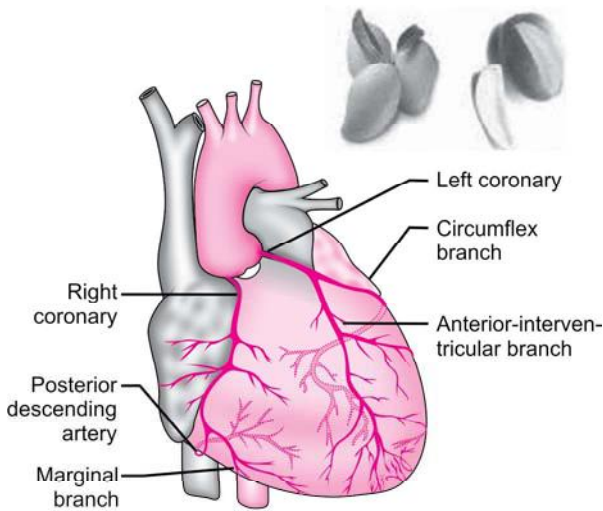
### NICE TO KNOW

#### Localization of infarct in a particular coronary vessel with respect to leads:

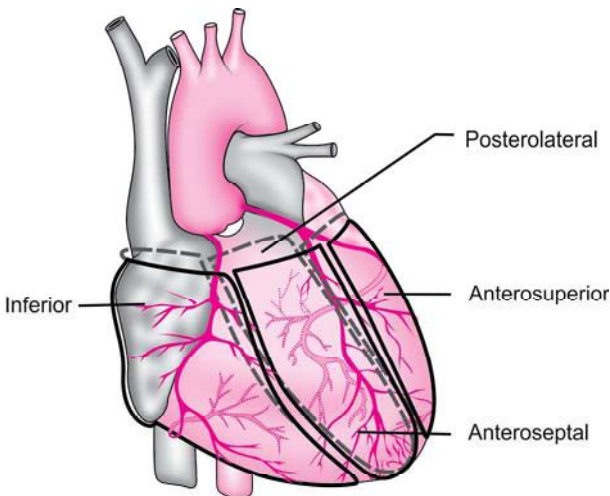
Coronary artery	LV quadrant	Zones	Common terms	Diagnostic lead	ST segment
Left anterior descending artery	Anteroseptal	All	Anterior	V1, V2, V3	Elevated
	Anterosuperior	All	Lateral	I, aVL	
	Inferior	Apical	Lateral	V4, V5, V6	
	Posterolateral	Apical	Lateral	V4, V5, V6	
Posterior descending artery	Inferior	Basal Middle	Inferior	II, III, aVF	Elevated
Left circumflex artery	Posterolateral	Basal Middle	Posterior	V1, V2, V3	Depressed

“A man who dares to waste one hour of life has not discovered the value of life.”  
—Charles Darwin

To locate the infarct let's imagine the heart in a 3D picture. To make it simpler, let us compare heart to a mango. Now cutting the mango into 4 vertical slices, similarly imagine heart to be cut into 4 quadrants. Anatomically these quadrants are named as, anterosuperior, anteroseptal, inferior and posterolateral. Now each quadrant can be again divided into three zones. Each zone is being supplied by specific branch of coronary vessel. Any infarct occurring at these branches will show changes in the leads facing the effected zone.



**Fig. 7.27:** Heart



**Fig. 7.28:** Left ventricle quadrant

*“As a rule, men worry more about what they can't see than about what they can.”*

*—Julius Caesar*

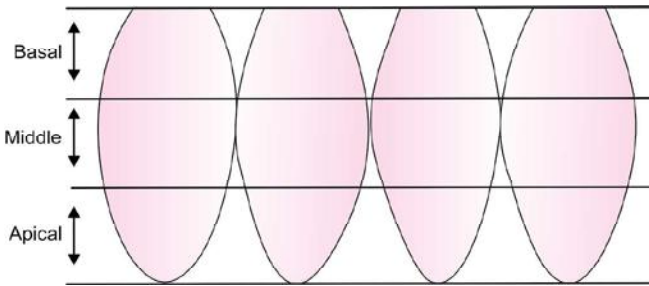


Fig. 7.29: Zones of left ventricle

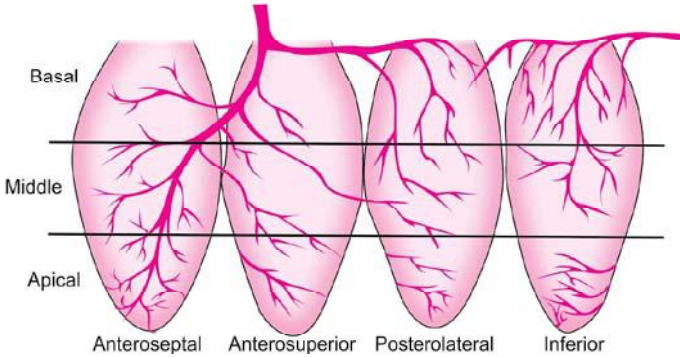


Fig. 7.30: Quadrant and zones of left ventricle

1. *ST* elevation in *V1*, *V2* and *V3*: Anteroseptal quadrant infarction involving all zones.

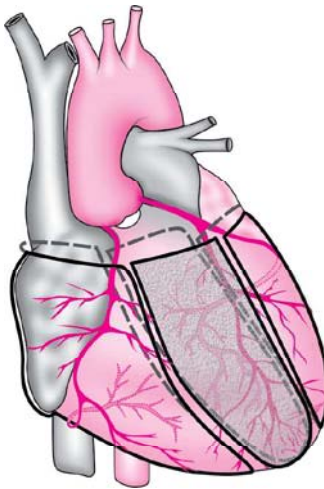
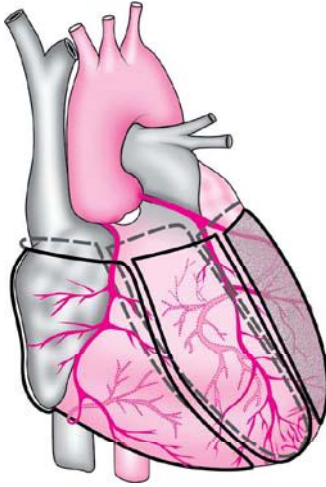


Fig. 7.31: Left anterior descending artery infarction

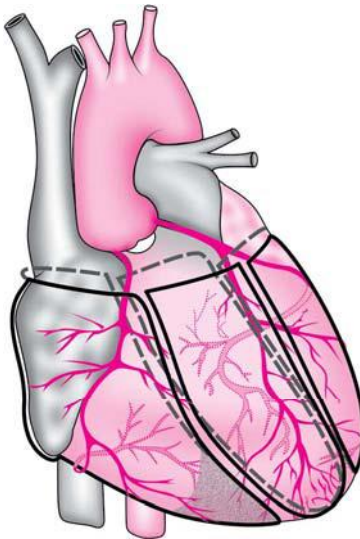
*“Never bend your head. Always hold it high. Look the world straight in the face.”*  
—Helen Keller

2. *ST elevation in lead I and aVL*: Anterosuperior quadrant infarction involving all zones.



**Fig. 7.32:** Left anterior descending artery infarction

3. *ST elevation in V4, V5 and V6*: Inferior quadrant infarction involving apical zone.

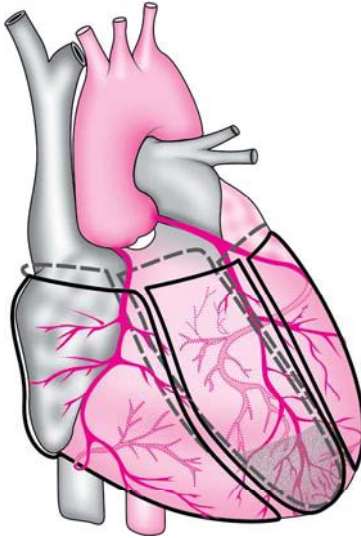


**Fig. 7.33:** Left anterior descending artery infarction

“A great man is he who has not lost the heart of a child.”

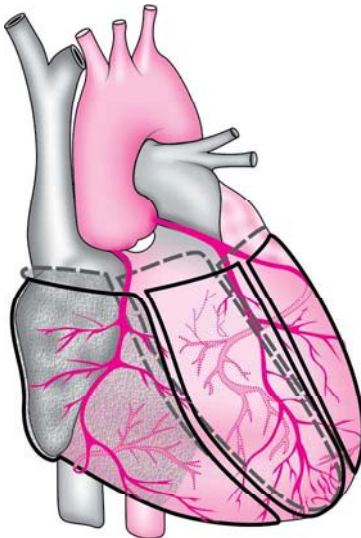
—Mencius

4. *ST elevation in V4, V5 and V6*: Posterolateral quadrant infarction involving apical zone.



**Fig. 7.34:** Left anterior descending artery infarction

5. *ST elevation in leads II, III and aVF*: Inferior quadrant involving basal and middle zone.



**Fig. 7.35:** Posterior descending artery involvement

*“The tree laden with fruits always bends low. If you wish to be great, be lowly and meek.”*

*—Sri Ramakrishna Paramahansa*

6. ST depression in V1, V2 and V3: Posterolateral quadrant infarction involving basal and middle zone.

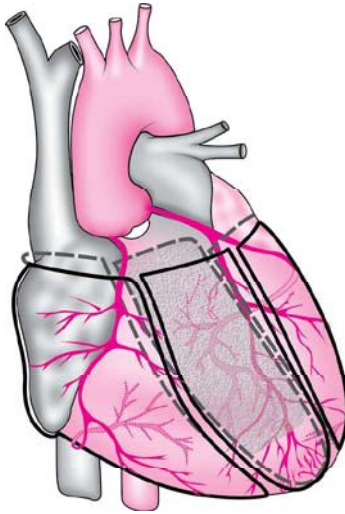
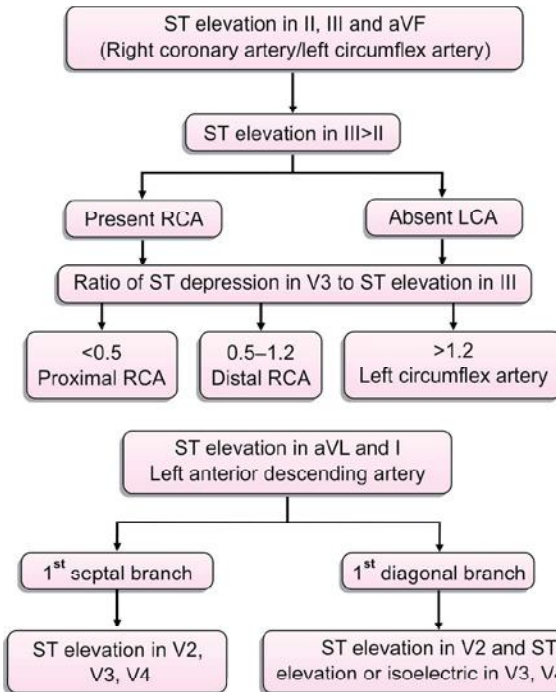


Fig. 7.36: Left circumflex artery

### Detection of Culprit Coronary Vessel



“Arise, Awake and Stop not until the goal is reached.”

—Swami Vivekananda

## HYPERTROPHY

### Left Ventricular Hypertrophy

#### Criteria

- I. Sokolow-Lyon criteria: Sum of depth of S wave in V1 and height of R wave in lead V5 or V6 = 35 mm/ or R wave in V5 or V6 > 26 mm (more sensitive)
- II. Any precordial lead > 45 mm.
- III. The R wave in aVL > 11 mm.
- IV. The R wave in lead I > 12 mm.
- V. The R wave in aVF > 20 mm.

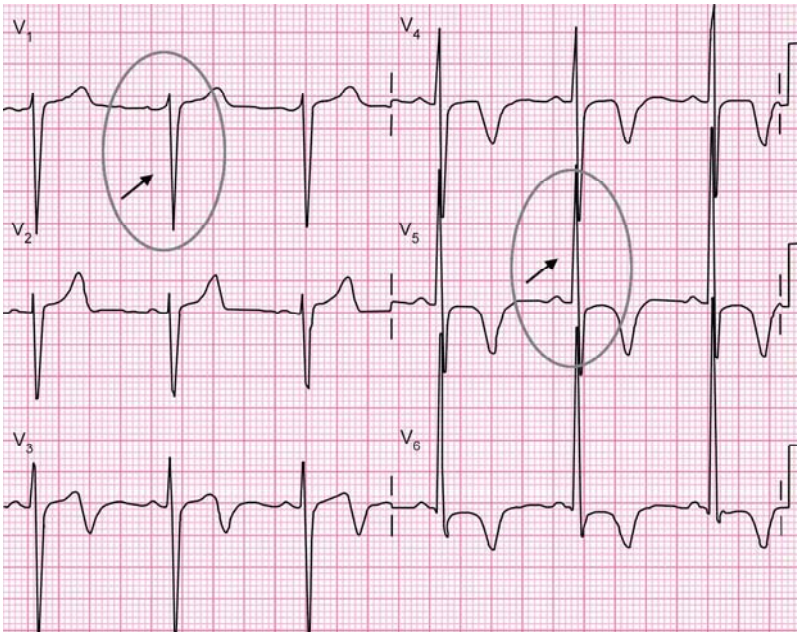


Fig. 7.37: ECG of left ventricular hypertrophy

#### Concept

LVH indicates large or hypertrophied left ventricle suggesting that there is more mass and cells present in the left ventricle, therefore, more action potentials are generated this, in turn, causes a large vector and increased amplitude on the ECG. This is especially seen in precordial leads because they are close to the chest wall electrodes.

*“Do not say, ‘It is morning,’ and dismiss it with a name of yesterday. See it for the first time as a newborn child that has no name.”*

—Rabindranath Tagore

### Causes

1. Systemic hypertension.
2. Hypertrophic cardiomyopathy.
3. Coarctation of aorta.
4. Aortic stenosis.

### Clinical Features

1. Heaving apex beat.

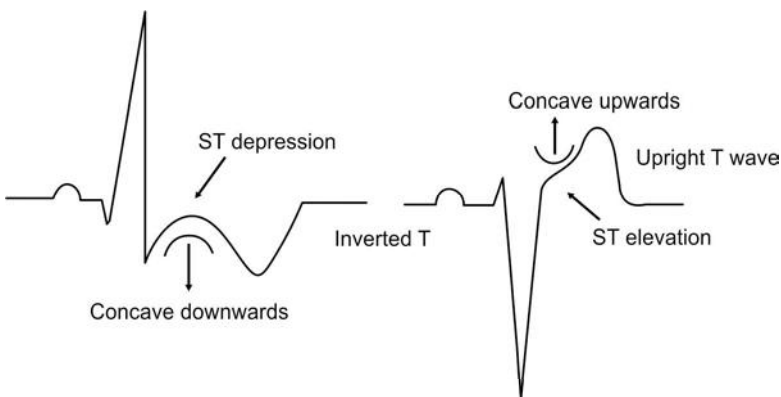
## STRAIN PATTERN

Strain pattern refers to the ST and T wave configurations that arise from repolarization abnormalities found in either RVH or LVH.

### Left Ventricular Strain Pattern

#### Criteria

1. In leads V4, V5 and V6, ST depression with downward concavity and inverted asymmetric T wave.
2. In V1, V2 and V3, there are reciprocal changes like ST elevation with upward concavity and an upright asymmetric T wave.



**Fig. 7.38:** Left ventricular strain pattern

#### Note

The ST elevation can be 1–3 mm in leads V2 and V3.

The taller or deeper the wave, bigger the strain.

*“To succeed in your mission, you must have single-minded devotion to you goal.”*

*—Abdul Kalam*



## Right Ventricular Hypertrophy

### Criteria

1. R V1 divided by S V1 should be  $> 1$  (more sensitive)
2. R wave in V1 plus S wave in V5 or V6 = 11 mm (Sokolow-Lyon criteria)
3. R in aVR should be  $> 5$  mm
4. R wave in V1 = 7 mm
5. S wave in V1 = 2 mm.

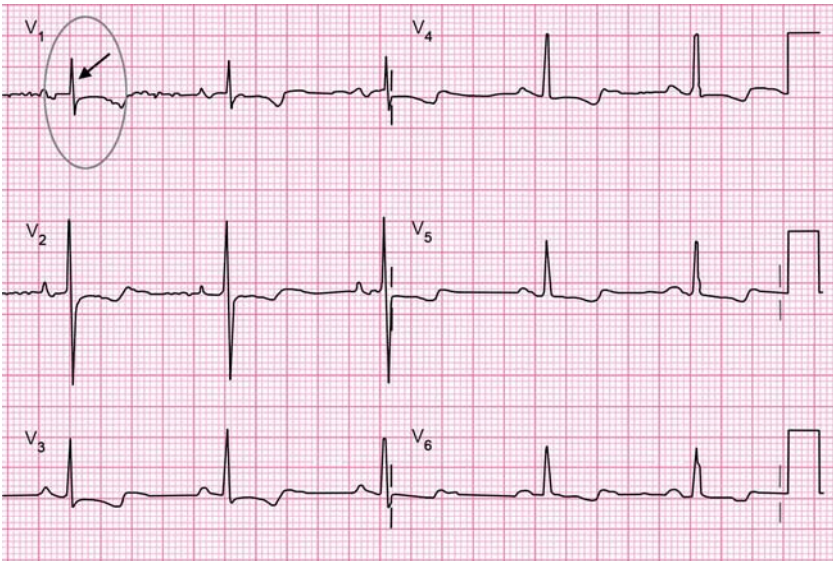


Fig. 7.39: ECG of right ventricular hypertrophy

### Clinical Features

1. Left parasternal heave
2. Epigastric pulsation.

### Causes

1. Chronic cor pulmonale
2. Pulmonary hypertension
3. Pulmonary stenosis
4. Fallot's tetralogy

## Right Ventricular Strain Pattern

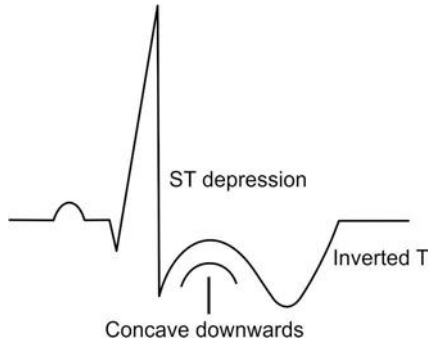
### Criteria

In leads V1 and V2:

*"Winners don't do different things, they do things differently."*

—Shiv Khera

1. Concave downward ST segment which is depressed.
2. Inverted asymmetric T wave




**Fig. 7.40:** Right ventricular strain pattern

## BUNDLE BRANCH BLOCK

### Right Bundle Branch Block

#### Criteria

- i. Wide QRS complex
  - ii. RSR pattern or rabbit ear pattern in V1
  - iii. Broad and slurred S wave in leads I and V6
  - iv. Right axis deviation may be present
- Slurred S wave in leads I and V6 are the major criteria that have to be looked.



*"Courage is the discovery that you may not win, and trying when you know you can lose."*

—Tom Krause

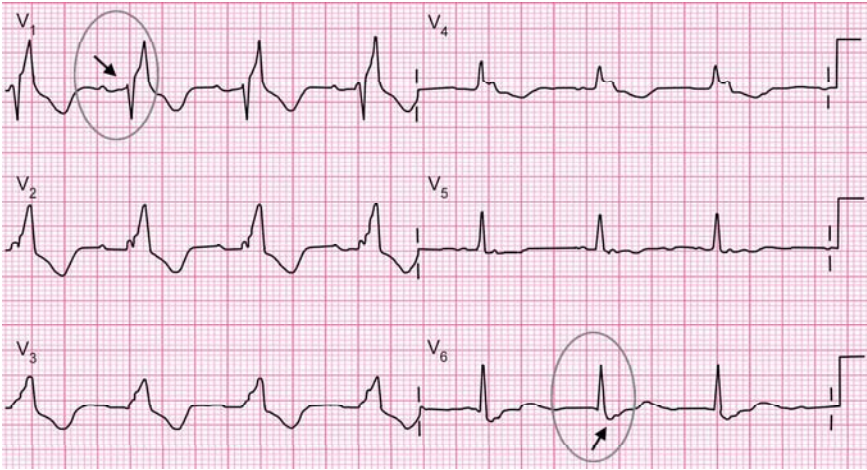


Fig. 7.41: ECG of right bundle branch block

Various morphological slurred S waves are seen as below.



Fig. 7.42: Various morphological slurred S waves

### Concept

When there is a block in the right bundle, the impulses are not transmitted through the normal conduction pathway but transmitted through cell to cell depolarization to the part of interventricular septum and right ventricle. This slow impulse causes a slower depolarization time, which is manifested on the ECG by prolonged QRS interval.

*“The greatest barrier to success is the fear of failure.”*

—Seven Goran Eriksson

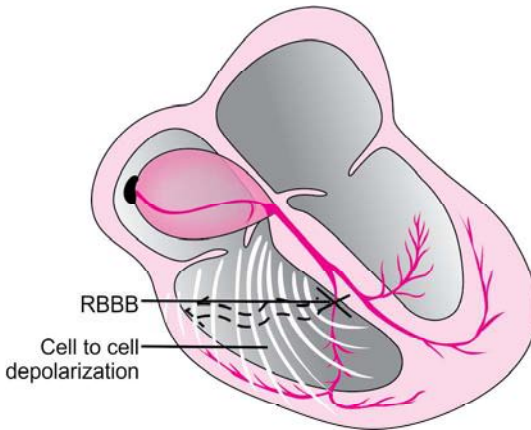


Fig. 7.43: Right bundle branch block

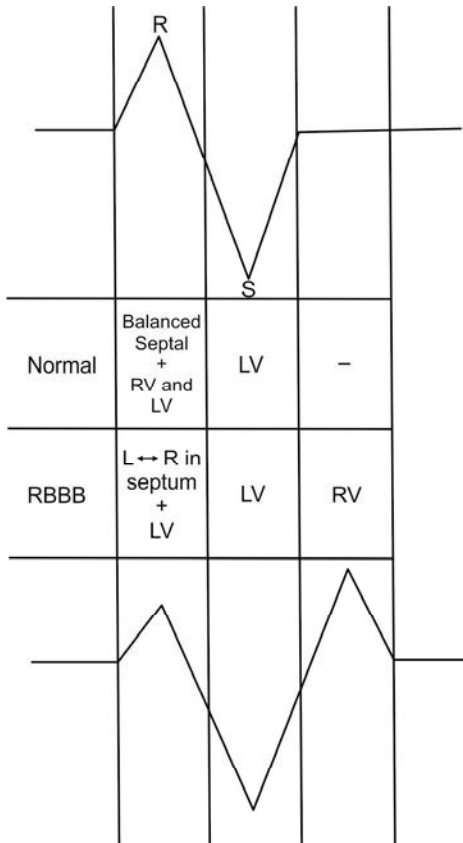


Fig. 7.44: Conduction of impulse in right bundle branch block

*“Success is simple. Do what’s right, the right way, at the right time.”*

—Arnold H Glasgow

### Causes

1. Acute myocardial infarction
2. Right ventricular hypertrophy
3. Chronic cor pulmonale
4. Pulmonary embolism.

### Left Bundle Branch Block

#### Criteria

- i. Wide QRS complex with duration of  $> 0.12$  s ( $> 3$  mm)
- ii. Deep and broad S wave in V1 with no R wave.
- iii. Broad slurred R wave or RR' pattern without a Q wave in leads I and V6.
- iv. Always associated with left axis deviation.

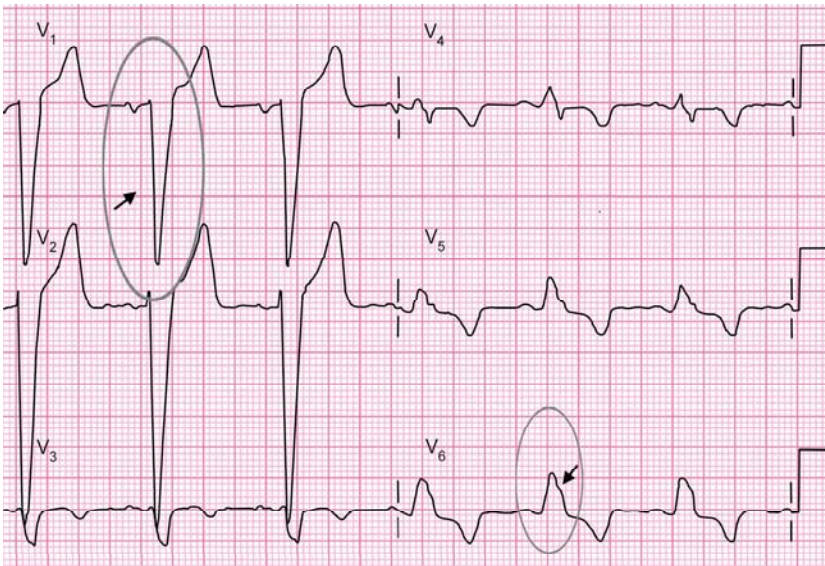


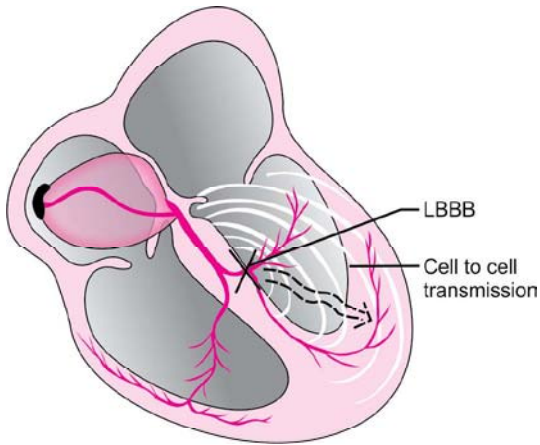
Fig. 7.45: ECG of left bundle branch block

#### Concept

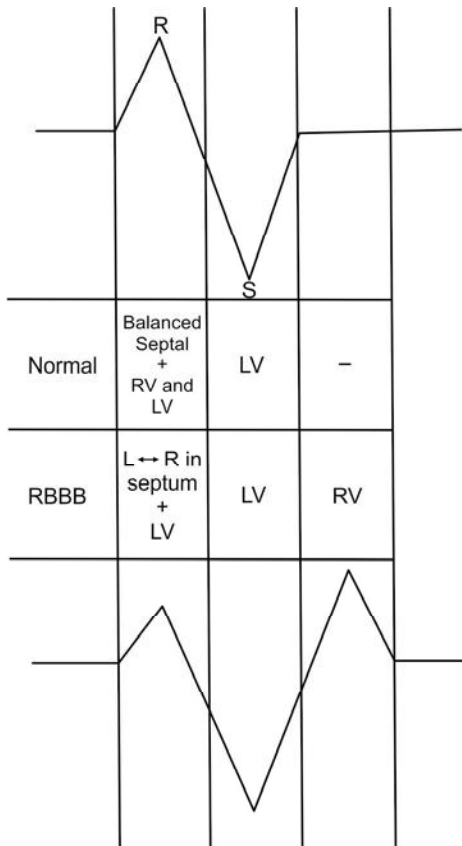
The block in the left bundle branch causes an electrical potential to travel down first in the right bundle. Then ventricular depolarization occurs from right to left by cell to cell transmission. Because the vector is moving from right to left, the complexes will be negative in V1-V2 and positive in lead I, V5 and V6.

*“A great leader’s courage to fulfill his vision comes from passion, not position.”*

*—John Maxwell*



**Fig. 7.46:** Left bundle branch block



**Fig. 7.47:** Conduction of impulse in left bundle branch block

*“Victory is sweetest when you’ve known defeat.”*

*—Malcolm S Forbes*

## NICE TO KNOW

### CRITERIA FOR DIAGNOSIS

#### Left Anterior Hemiblock

1. Left axis deviation ( $-30^\circ$  to  $-90^\circ$ )
2. In lead I, QR complex or an R wave.
3. rS complex in lead III and may be in lead II and aVF

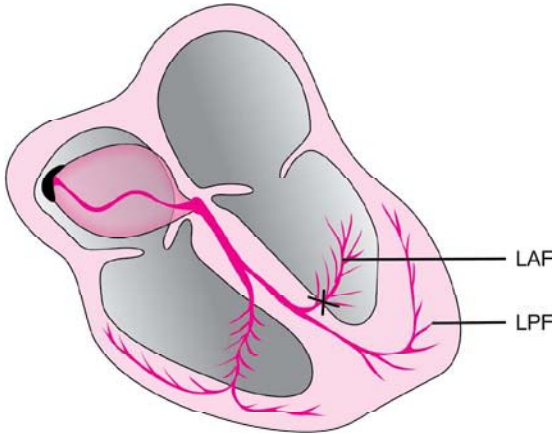


Fig. 7.48: Left anterior hemiblock

#### Left Posterior Hemiblock

##### Criteria for Diagnosis

1. Right axis deviation ( $90^\circ$  to  $180^\circ$ )
2. In lead I, S wave and in lead III, Q wave.
3. Exclusion of RAE and/or RVH.

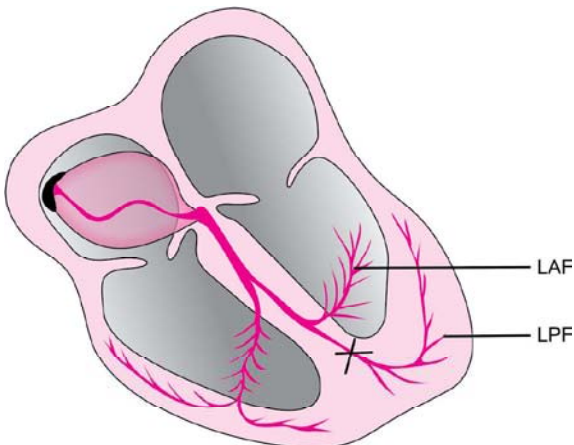


Fig. 7.49: Left posterior hemiblock

“Success is not the key to happiness. Happiness is the key to success. If you love what you are doing, you will be successful.”  
—Herman Cain

### LBBB with Acute MI

3 points meet criteria for acute MI

- ST elevation > 1 mm in leads with a positive QRS complex (concordance in ST deviation) (score 5).
- ST depression > 1 mm in V1-V3 (concordance in ST deviation) (score 3).
- ST elevation > 5 mm in leads with a negative QRS complex (inappropriate discordance in ST deviation) (score 2).

Concordant: T wave travels in the same direction as the last part of the QRS.

Discordant: T wave moves in the opposite direction as the last part of the QRS.

*“If you want to live a happy life, tie it to a goal, not to people or things.”*

*—Albert Einstein*



The term arrhythmia can be defined as disturbance in the rhythmic contraction of atria and ventricles due to disorder in impulse production or impulse conduction.

## DISORDERS OF IMPULSE FORMATION

- I. Disturbances of sinus mechanism
  - i. Sinus tachycardia
  - ii. Sinus bradycardia
  - iii. Sinus arrhythmia
- II. Disturbance of atria
  - i. Atrial premature contraction
  - ii. Atrial fibrillation
  - iii. Atrial flutter
  - iv. Paroxysmal supraventricular tachycardia
- III. Disturbance of atrioventricular node
  - i. Junctional ectopics
  - ii. Junctional rhythm
  - iii. Junctional tachycardia
- IV. Disturbance of ventricles
  - i. Ventricular ectopics
  - ii. Ventricular tachycardia
  - iii. Ventricular fibrillation

## DISORDERS OF IMPULSE CONDUCTION

- I. Sinoatrial blocks**
- II. AN nodal blocks**
  - i. First degree block
  - ii. Second degree block
    - a. Wenckebach (Mobitz type I) block
    - b. Mobitz type II block
  - iii. Complete or third degree block

*“To succeed in life, you need two things: ignorance and confidence.”*

*—Mark Twain*

### III. Bundle blocks

- i. Right bundle branch block
- ii. Left bundle branch block
  - a. Left anterior hemiblock
  - a. Left posterior hemiblock

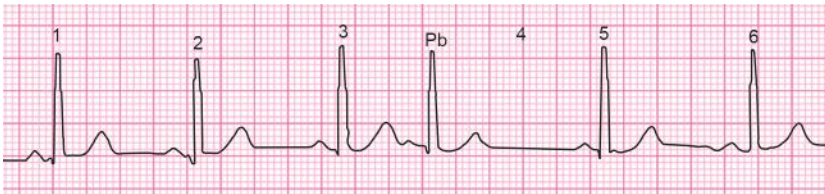
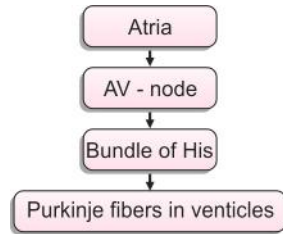
### Premature Beats/Ectopic Beats/Extrasystole

It is the beat that is arising from an ectopic focus outside the SA node and occurring before the next sinus beat.

It may arise from:

- I. Atria
- II. Nodal
- III. Ventricular

It can arise from either of the ones mentioned above because pace maker are located in the following order:



**Fig. 8.1:** Premature beats

In this case premature beat is after beat no 3. As a result, expected sinus beat 4 is missed and after a small pause the next sinus beat, i.e. beat no: 5 appears and then the sinus rhythm starts again.

#### Compensatory pause

It is defined as the pause between the premature beat and the next sinus beat. Compensatory pause can be of two types they are:

1. Complete compensatory pause
  2. Incomplete compensatory pause.
1. *Complete compensatory pause:* If the compensation occurs exactly for the missed beat and the third sinus beat occurs exactly where it would otherwise occur, then it is a complete compensatory pause.

“Don’t wait. The time will never be just right.”

—Napoleon Hill

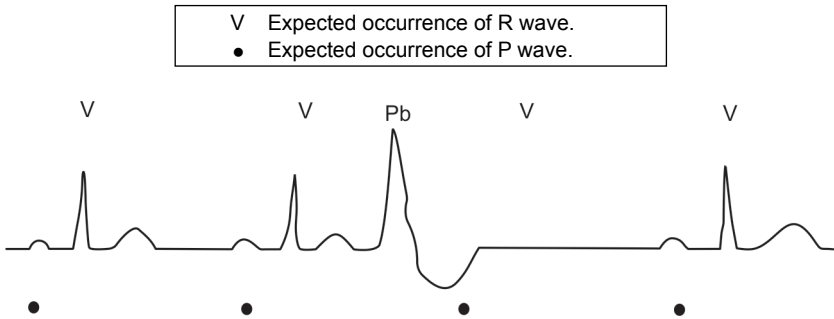


Fig. 8.2: Complete compensatory pause

2. *Incomplete compensatory pause*: If the beat following the premature beat occurs before the next expected beat, then it is incomplete compensatory pause.

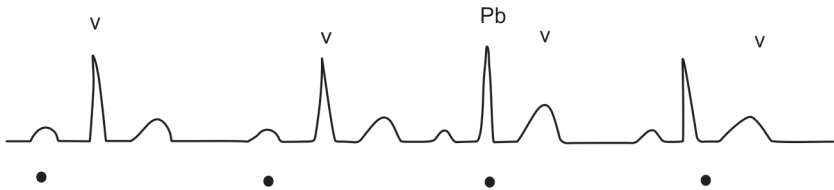


Fig. 8.3: Incomplete compensatory pause

Depending upon the site of origin of premature beat it is classified as—

- I. Supraventricular premature beat
- II. Ventricular premature beat.

### Supraventricular Premature Beat/Extrasystol

#### Criteria

*Rate*: Underlying rhythm.

*Rhythm*: Irregular with premature atrial complexes.

*Pacemaker*: Ectopic atrial pacemaker outside SA node.

*P wave*: Ectopic P wave present, generally different from normal SA node P wave.

*PR*: General normal range 120–200 msec, but differ from underlying rhythm.

*QRS*: Same as underlying rhythm.

Impulse reaches the ventricle via the normal conduction pathway so the QRS complex in the ECG has the normal configuration.

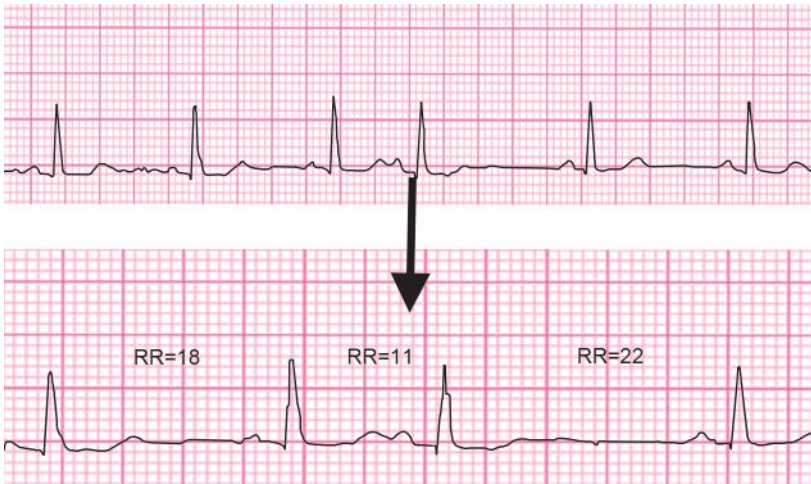
In this ECG previous normal R-R interval is 18.

Premature beat RR interval is 11 and compensatory pause RR interval is 22.

$$11 + 22 = 33$$

$$2 \times \text{normal R-R interval} = 2 \times 18, \text{ which is } 36.$$

“Most great people have attained their greatest success just one step beyond their greatest failure.”  
—Napolean Hill



**Fig. 8.4:** ECG of supraventricular premature beat

Since the sum of premature beat and compensatory pause is not twice the normal R-R interval this is an incomplete compensatory pause which is seen in atrial premature beat.

### Concept

In atrial premature beat, incomplete compensatory pause occurs because atrial impulse causes early depolarization of SA node leading to disturbance in the rhythm. Therefore next impulse from SA node will certainly come earlier than the expected next beat. Premature beat always arises outside the SA node hence it has got its names like ectopic beat, extrasystole.

## Ventricular Premature Beat/Ventricular Extrasystole

### Criteria

**Rhythm:** Irregular

**QRS:** Is not normal looking. Broadened, greater than 0.12 seconds. P waves are usually obscured by the QRS.

In this, impulse arises below the division of bundle of His in one of the bundle branches or ventricles. Both ventricles will not be activated at the same time. This leads to a wide slurred and bizarre QRS complex with T wave direct opposite to main QRS complex.

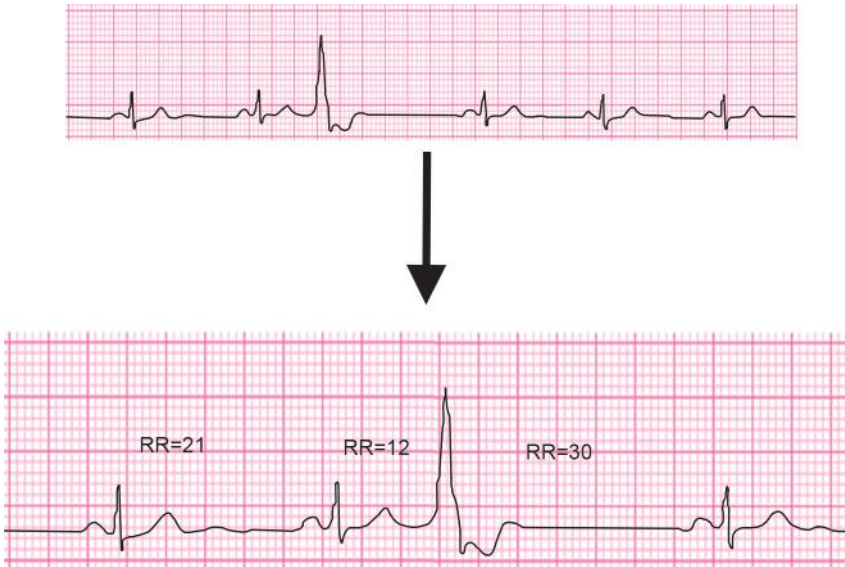
In this ECG previous normal R-R interval is 21, premature beat RR interval is 12 and compensatory pause RR interval is 30.

$$12 + 30 = 42$$

$$2 \times \text{normal R-R interval} = 2 \times 21 = 42$$

*“If you do not hope, you will not find what is beyond your hopes.”*

—St. Clement of Alexandria



**Fig. 8.5:** ECG of ventricular premature beat

Sum of premature beat and compensatory pause is twice the normal R-R interval; this is a complete compensatory pause which is seen in ventricular premature beat.

*Concept*

In case of ventricular premature beat, as the impulses are arising in the ventricles it does not affect the rhythm of SA node. So it always has complete compensatory pause.

*Types*

1. *Unifocal ectopics:* Similar QRS configuration of ectopic is seen in all leads and originates from a single ectopic ventricular focus.
2. *Multifocal ectopics:* Variable QRS configuration of ectopic in same lead, because ectopic originates from different focus of ventricle.
3. *Interpolated ventricular ectopics:* Ventricular ectopic occurs between two normal sinus beats without compensatory pause (seen with sinus bradycardia).
4. *Ventricular bigeminy:* Every alternate beat is ventricular ectopic.

Supraventricular premature beat (SVPB)	Ventricular premature beat (VPB)
Normal QRS configuration complex	Has a wide and bizarre QRS
Incomplete compensatory pause occurs May have a preceding P wave P wave may not be visible always P wave might merge with premature T wave	Complete compensatory pause occurs It has no P wave

*“Most great people have attained their greatest success just one step beyond their greatest failure.”*  
—Napoleon Hill

If the QRS complex has normal configuration, then it is known that the beat is supraventricular beat, now to study the site of origin study P wave.

Atrial	Nodal
Upright P wave	Inverted P wave with short P - R
P-R interval is normal	Interval impulse arises from lower part of AV node

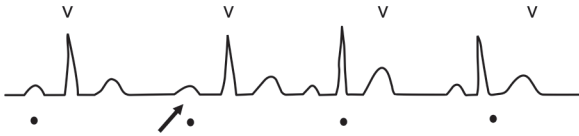


Fig. 8.6: Atrial origin of premature beat

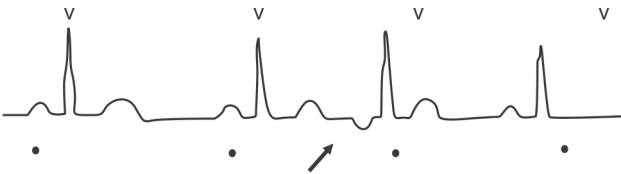


Fig. 8.7: Nodal origin of premature beat

### Nodal Rhythm or Junctional Rhythm

#### Criteria

1. Heart rate 40–60 per minute
2. Inverted P wave just before, within or after QRS complex.

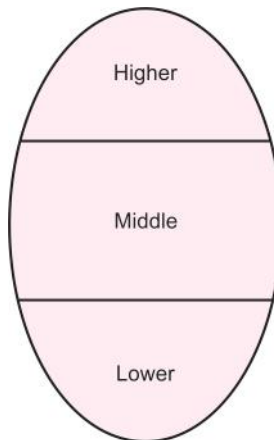


Fig. 8.8: SA nodal parts

*“It is literally true that you can succeed best and quickest by helping others to succeed.”*  
 —Napoleon Hill

Types

1. High nodal rhythm: Inverted P wave before QRS

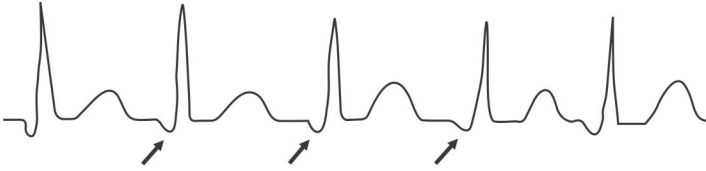


Fig. 8.9: High nodal rhythm

2. Mid nodal rhythm: P wave is not seen, it is buried in QRS

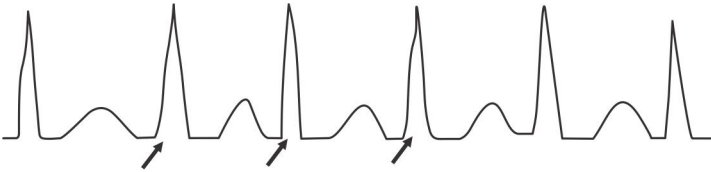


Fig. 8.10: Mid nodal rhythm

3. Low nodal rhythm: P wave appears just after QRS

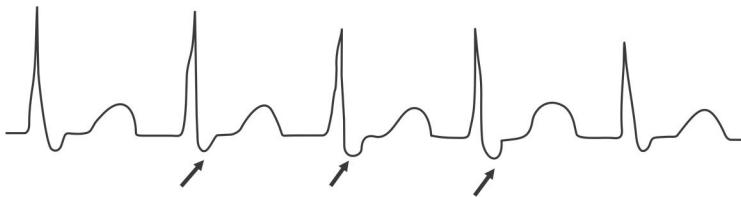


Fig. 8.11: Low nodal rhythm

## SA NODE BLOCK

1. Sinus pause
2. Sinus arrest
  - Sinus arrest with atrial escape beat
  - Sinus arrest with nodal or junctional escape beat
  - Sinus arrest with ventricular escape beat

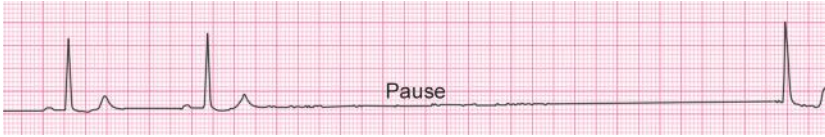### Sinus Pause

In a sinus pause there is a pause in between beats but the preceding is not premature which implies that the SA node itself has paused for a while and started beating again.

*“The best way to predict the future is to invent it.”*

—Alan Kay

In the picture given above see after the pause normal sinus rhythm has started again hence it is a sinus pause.



**Fig. 8.12:** Sinus pause

#### Note

- Compensatory pause is preceded by premature beat.
- Sinus pause is preceded by a normal beat.
- If the sinus pause is more than 1.5 sec, then it is called as sinus arrest.
- When a sinus arrest occurs, the SA node may recover and resume the function again after 1.5 sec or if it doesn't happen some lower ectopics will fire an impulse and stimulate the heart.

*Pacemakers are present in the following areas:*

- SA node
- AV node
- Bundle of His
- Purkinje fibers

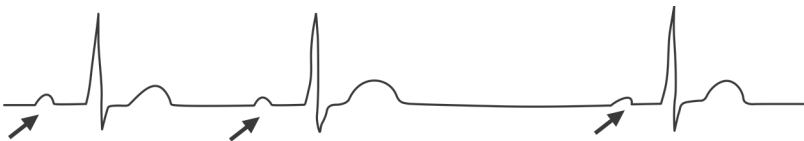
#### SA Node

It is the fastest and the most dominating pacemaker. It normally does not allow any other cell to fire the impulses but when the sinus arrest occurs the lower center temporarily escapes the depolarizing impulse of SA node and one of them fires impulses till SA node takes over again.

Therefore, the beat arising following a sinus arrest comes from one of the lower pacemakers and it is called as an escape beat which indicates an escape of the inhibition from a SA node.

The careful study of the beat after sinus pause will tell you the origin of escape beat.

The Figure 8.13 shows slightly altered P wave with normal QRS complex.



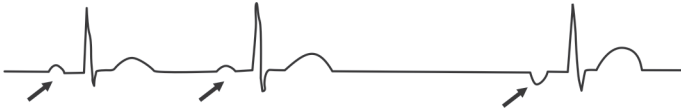
**Fig. 8.13:** Sinus arrest with atrial escape beat

*"Talk doesn't cook rice."*

*—Chinese Proverb*

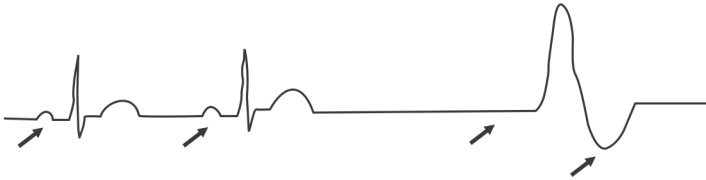


The Figure 8.14 shows inverted P wave with normal QRS complex. Absent P wave may occur after a pause of 1.2–1.6 secs.



**Fig. 8.14:** Nodal or junctional escape beat

The Figure 8.15 shows broad QRS complex and T wave inversion. It occurs after 1.8–2.2 seconds.



**Fig. 8.15:** Ventricular escape beat

Whenever you see a pause, first study the preceding beat.

<i>Premature beat</i>	<i>Sinus pause</i>
If it occurs early it is premature beat with compensatory pause	If R-R interval is normal, then it is a sinus pause with escape beat
Study QRS complex, compensatory pause and P wave to detect the origin of premature beat.	Study the succeeding beat to know the type of escape beat.

## ABNORMALITIES OF RHYTHM

Rhythm may arise from SA node, atria, ventricles.

Abnormalities of SA node rhythm:

- I. Sinus arrhythmia
- II. Sinus bradycardia
- III. Sinus tachycardia

### Sinus Arrhythmia

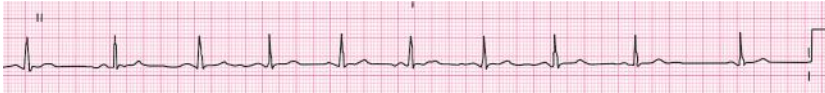Normally heart rate increases during inspiration and decreases during expiration this variation is termed as sinus arrhythmia.

*“Life is about making the right decisions and moving on.”*

—Josh

**Criteria**

- Rate : 60–100 bpm.  
 Rhythm : Regular. Sinus arrhythmia changes rhythm in response to respiration. This is seen most often in young healthy people.  
 Pacemaker : Each beat originates in the SA node.  
 P wave : Look the same, all originate from the same locus (SA node)  
 PRI : 120–200 msec  
 QRS : 80–120 msec, narrow unless effected by underlying anomaly.

**Fig. 8.16:** ECG of sinus arrhythmia**Causes**

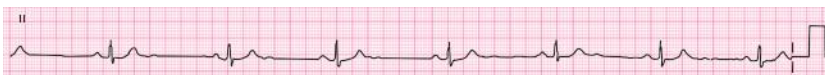1. Children.
2. Young adults.

**Concept**

During inspiration parasympathetic activity diminishes, leading to increase in heart rate. It reverses during expiration.

**Sinus Bradycardia****Criteria**

- Rate : < 60 bpm.  
 Rhythm : Regular generally  
 Pacemaker : SA node  
 P wave : Present, all originating from SA node, all look the same.  
 PRI : < 200 msec, and constant  
 QRS : Normal, 80–120 msec

**Fig. 8.17:** ECG of sinus bradycardia**Causes**

1. Physiological (due to increased vagal tone)  
 During sleep, athletes.

*“Imagination is more important than knowledge. For while knowledge defines all we currently know and understand, imagination points to all we might yet discover and create.”*

*—Albert Einstein*

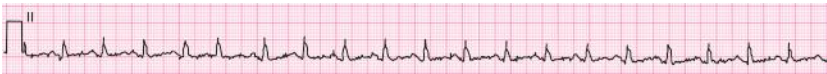2. Pathological:

- Hypothyroidism
- Raised intracranial pressure
- Acute inferior wall MI
- Drugs like digoxin,  $\beta$ -blockers, verapamil
- Obstructive jaundice due to deposition of bilirubin in conduction system
- Hypothermia.

## Sinus Tachycardia

### Criteria

- Rate : > 100 bpm  
Rhythm : Regular, generally  
Pacemaker : SA node  
P wave : Present and normal, may be buried in T waves in rapid tracings  
PRI : 120–200 msec., generally closer to 120 msec.  
QRS : Normal.



**Fig. 8.18:** ECG of sinus tachycardia

### Causes

#### *Physiological:*

- Anxiety
- Exercise
- Pregnancy

#### *Pathological:*

- Anemia
- Fever
- Thyrotoxicosis
- Shock
- Sick sinus syndrome
- Acute anterior MI

## ATRIAL RHYTHMS

---

They are:

- SV tachycardia
- Atrial flutter
- Atrial fibrillation.

*“Do not follow where the path may lead. Go instead where there is no path and leave a trail.”*  
—Harold R McAlindon

## Paroxysmal Supraventricular Tachycardia (PSVT)

Here the heart beats at a rate of 140–220 beats per minute.

### Criteria

Rate	: 140–220 bpm
Rhythm	: Regular
Pacemaker	: Re-entry circuit
Accessory pathway	: Normal or short (if down accessory pathway)
A-V nodal reentry	: Hidden in or at end of QRS
PRI	: Depends on location of circuit
QRS	: Normal if accessory pathway used - prolonged (>120 msec) with delta wave

## Pathology

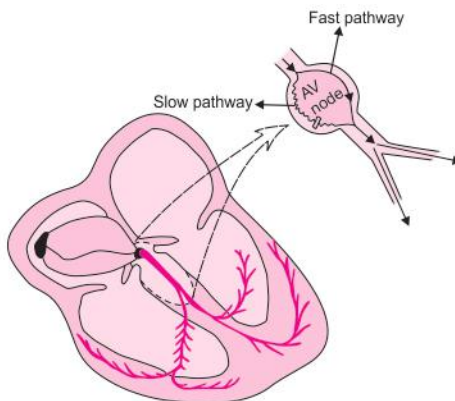
### Concept of Dual AV Nodal Pathway

*Fast pathway:* In fast pathway there is rapid conduction and a long refractory period.

*Slow pathway:* In this type of pathway there is slow conduction and the refractory period is also short.

### During a sinus rhythm

Only conduction in the fast pathway is manifested, this results in normal PR interval. Extra stimuli generated in the atria are blocked in a fast pathway because of longer refractory period. So the impulses are conducted through the slow pathway, if the conduction in the slow pathway is slow enough to allow the previously refractory



**Fig. 8.19:** Conduction in sinus rhythm

“Once you start working on something, don’t be afraid of failure and don’t abandon it. People who work sincerely are the happiest.”  
—Chanakya

fast pathway to recover, the impulse which has been conducted in the slow pathway causes ventricular contraction.

PSVT can result from:

- Increase in the atrial automaticity
- Conduction of impulse in the anterograde direction via AV node
- Retrograde through AV accessory tract

1. Atrial tachycardia:

Rate 200 beats per minute (100–200)

A focus outside the sino-atrial node fires impulses automatically at a rapid pace.

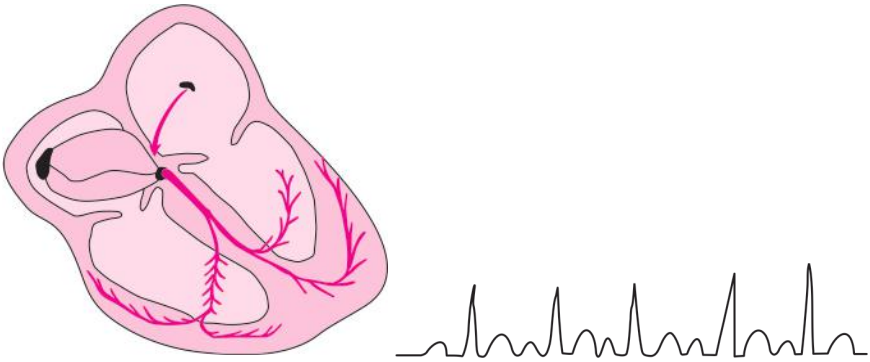


Fig. 8.20: Atrial tachycardia

2. AV nodal re-entry tachycardia:

Rate 140–200 beats per minute.

It is initiated by an atrial premature beat. Re-entry rhythm originates in the AV nodal area and spreads simultaneously up to the atria and down to the ventricles, as a result the P waves are usually hidden in the QRS complex because the atria and the ventricles are activated simultaneously.

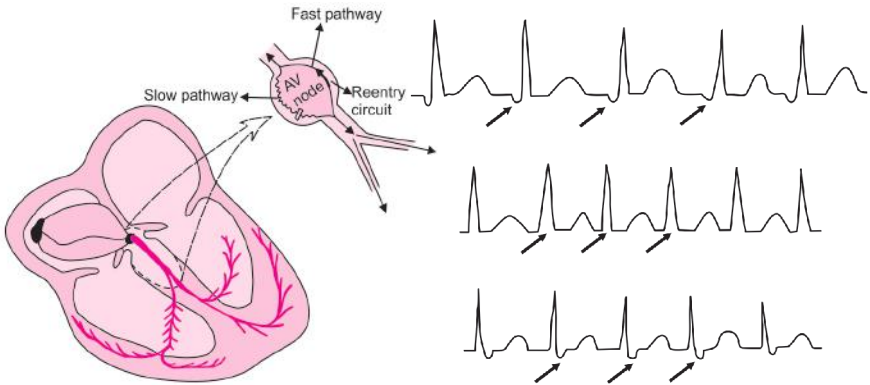


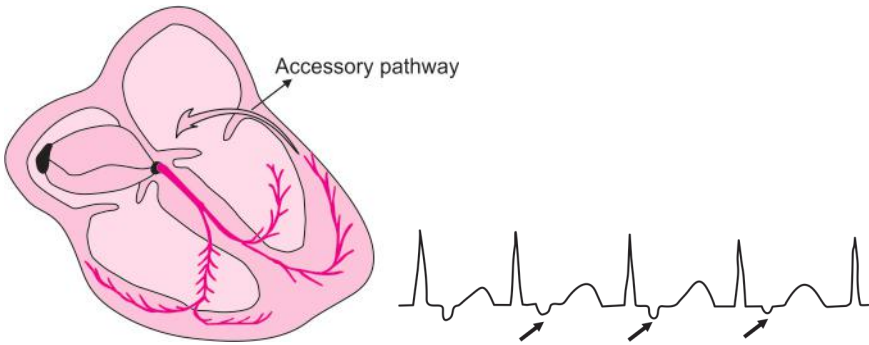
Fig. 8.21: AV nodal re-entry tachycardia

*“As soon as the fear approaches near, attack and destroy it.”*

—Chanakya

### 3. AV re-entry tachycardia:

It is because of bypass tract (accessory pathway), i.e. an abnormal cardiac muscle connects the atria and the ventricles bypassing the AV node. From here the impulse passes down through normal conducting system (i.e. AV node bundle of His) into the ventricles, recycles rapidly by the bypass tract to the atria.



**Fig. 8.22:** AV re-entry tachycardia

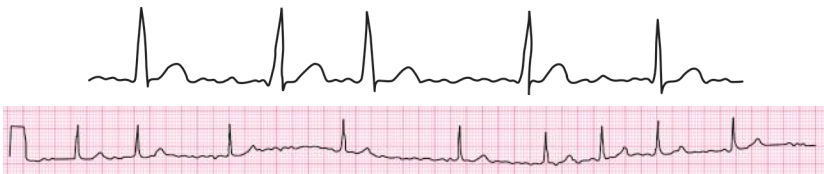Points	Sinus tachycardia	Supraventricular tachycardia
Onset	Gradual	Sudden
Heart rate	< 160 per minute	> 160 per minute (140–220)
		Responds abruptly
Carotid sinus massage	No or little response	Sudden palpitation, dizziness
Symptoms	Palpitation	Syncope and breathlessness

## Atrial Fibrillation

It is an arrhythmia where atrium beats rapidly and ineffectively whereas the ventricle responds at irregular intervals, producing the characteristic irregular pulse.

### Criteria

- Irregularly irregular rhythm
- Absent P waves (replaced by fibrillating f wave)
- Baseline vibration



**Fig. 8.23:** Atrial fibrillation

*“Education is the best friend. An educated person is respected everywhere.  
Education beats the beauty and the youth.”*

—Chanakya

### Clinical Features

1. History of rheumatic fever, IHD, thyrotoxicosis may be present
2. Irregularly irregular pulse
3. High BP
4. Features of underlying pathology is also present.

### Causes

Any condition causing increased atrial muscle mass, raised atrial pressure, atrial fibrosis, inflammation and infiltration of atrium causes atrial fibrillation.

1. Rheumatic heart disease with valvular lesions (mitral stenosis)
2. Acute MI
3. Hypertension
4. Thyrotoxicosis

### Note:

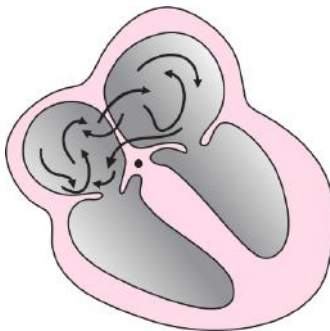
Rate = R wave is 15 large squares  $\times$  20

Fibrillation waves are described as—

- Fine
- Medium
- Coarse
- Sometime coarse fibrillation may resemble atrial flutter.

### Concept

It is due to either multiple re-entrant wavelets and/or because of multiple sites of atrial automaticity.



**Fig. 8.24:** Multiple re-entrant wavelets

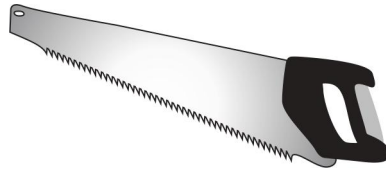
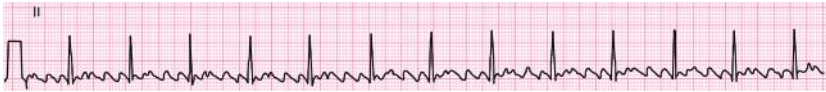*“When a man gives way to anger, he only harms himself.”*

—Chanakya

## Atrial Flutter

### Criteria

- Rate : 250–350 bpm (atrium)  
 Rhythm : Atrial rate regular, ventricular conduction 2:1 to 8:1  
 Pacemaker : Re-entrant circuit rhythm located in the right atrium  
 P wave : Saw-tooth or picket fence  
 PRI : Constant onset



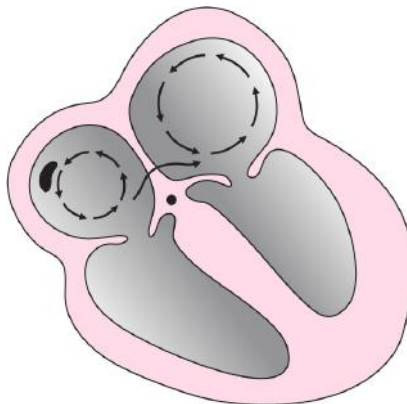
**Fig. 8.25:** Atrial flutter

### Causes

1. Rheumatic heart disease with valvular lesions (mitral stenosis)
2. Acute MI
3. Hypertension
4. Thyrotoxicosis

### Concept

The flutter waves are originated in the right atrium and travel in a counter-clock direction from top to bottom to top, chasing its own tail. Thus causing the



**Fig. 8.26:** Impulse traveling in a circular course

“Ability is not always gauged by examination.”

—Indira Gandhi



impulse to travel in a circular course in the atria giving rise to rapid regular and undulating flutter waves. Since AV node is not tuned to conduct impulses rapidly, atrial flutter is always accompanied by AV block and ventricular rate is much slower.

## NICE TO KNOW

In atrial flutter, atrial rate is 300 beats per minute. The AV junction is refractory to most of the impulses and allows only a fraction to reach the ventricles. If ventricles respond at the rate of 150 beats per minute, it is called 2:1 flutter, because the ratio of atrial rate (300) to ventricular rate (150) is 2 to 1. Atrial flutter with a ventricular rate of about 100 beats per minute is 3:1 flutter; with 75 beats per minutes, it is 4:1 flutter.

### Differences between atrial tachycardia, flutter and fibrillation

	<i>Atrial tachycardia</i>	<i>Atrial flutter</i>	<i>Atrial fibrillation</i>
1. Rate	Up to 200 bpm	200–300 pm	350–500 pm
2. Type of atrial contraction	Atria responds regularly with contractions of uniform size	Atria responds irregularly with production alternate large and small atrial contractions	Atrial beats rapidly and ineffectively whereas ventricles respond at irregular intervals producing irregular pulse
3. EGG findings	PR and TP intervals shortened T wave merges with P wave of next cardiac cycle	Features of tachycardia Saw-tooth appearance of T wave (flutter or F wave) Regular rhythm (irregular when there is a block) 2nd degree heart block.	Appearance of fibrillation wave (f) which shows constant change in height and width Irregularly irregular rhythm Vibrating baseline

## VENTRICULAR RHYTHMS


### Ventricular Tachycardia

#### Criteria

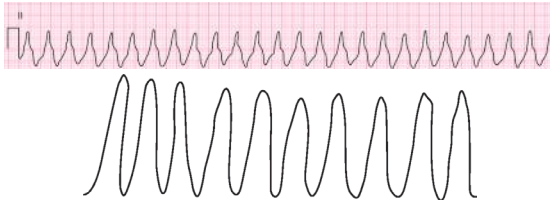
- Rate : Generally 100 to 220 bpm
- Rhythm : Generally regular, on occasions, can be modestly irregular.
- P wave : Absent
- QRS complex : Broad and bizarre indicating that QRS complexes are arising from ventricles
- Capture beat : Appearance of normal QRS complex in the middle of ventricular tachycardia
- Fusion beat : This type of complex is caused by two pacemakers, SA node and ventricular pacer. The result is hybrid of fusion complex, which is a complex with some features of both.

*“The greatest danger for most of us is not that our aim is too high and we miss it, but that it is too low and we reach it.”*

—Michelangelo



**Fig. 8.27:** Ventricular tachycardia with capture beat and fusion beat



**Fig. 8.28:** Ventricular tachycardia

### Causes

1. Acute MI
2. Myocarditis
3. Chronic IHD with poor left ventricular function
4. Ventricular aneurism
5. Electrolyte imbalance mainly hypokalemia and hypomagnesemia.

### Note

- QRS complex broad and bizarre indicating that QRS complex arising from ventricles
- Common after MI due to formation of circular course around the ischemic area.
- It is an alarming sign which may progress to ventricular fibrillation and death.

### Torsades De Pointes

In French, it literally means “twisting of the points.” It is a distinct type of polymorphic VT. Here the direction of the QRS complex appears to rotate cyclically, pointing downwards for several beats and then twisting and pointing upwards in the same leads.

### Ventricular Fibrillation

#### Criteria

- |               |   |
|---------------|---|
| Rate          | : Very rapid, too disorganized to count. Around 350–500 bpm |
| Rhythm        | : Irregular, waveform varies in size and shape              |
| QRS complexes | : QRS complexes are wide, bizarre and irregular             |
|               | Absent ST segments, P waves, T waves.                       |

*“The steeper the mountain the harder the climb the better the view from the finishing line.”*  
—Walt Emerson




Fig. 8.29: Torsades de pointes



Fig. 8.30: Ventricular fibrillation

### Clinical Features

1. Unconscious patient
2. Absent pulse
3. Unrecordable BP
4. Respiration is ceased
5. Absent heart sound.

### Causes

1. Acute MI
2. Electrolyte imbalance mainly hypokalemia and hypomagnesemia.
3. Electrocution
4. Drug over dosage like digitalis, isoprenaline and adrenaline
5. Drowning

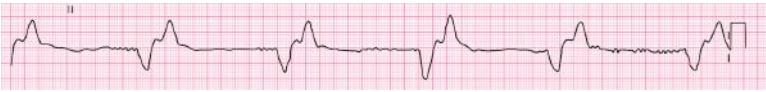### Idioventricular Rhythm

It means slow ventricular tachycardia.

### Criteria

1. *Rate*: 20–40 bpm
2. *Rhythm*: Regular
3. *P wave*: Absence P wave
4. *PRI*: If present, varies (no relationship to QRS complex [AV dissociation])
5. *QRS*: QRS interval >120 msec wide and bizarre

“We do not quit playing because we grow old, we grow old because we quit playing.”  
—Aristotle



**Fig. 8.31:** Idioventricular rhythm

### Clinical Features

1. Asymptomatic, transient, self-limiting and does not require treatment.

### Causes

Within first 48–72 hours of acute MI

## Differences Between Ventricular Tachycardia and Ventricular Fibrillation

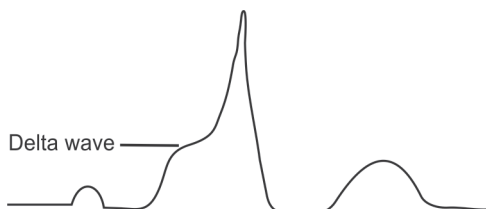
	<i>Ventricular tachycardia</i>	<i>Ventricular fibrillation</i>
1. Rate	Up to 200 bpm	350–500 pm
3. EGG findings	QRS complex are polymorphic	Irregular extremely fast small potential fluctuating in rate, rhythm and amplitude <i>Note:</i> It is a fatal condition because fibrillating ventricles cannot pump blood effectively. Thus circulation of blood stops causing sudden death.

## Wolf-Parkinson-White (WPW) Syndrome

### Criteria

WPW produces the following characteristic triad of finding on ECG:

- Short P-R interval ( less than 0.12 seconds)
- Wide QRS (more than 0.10 seconds)
- Delta waves



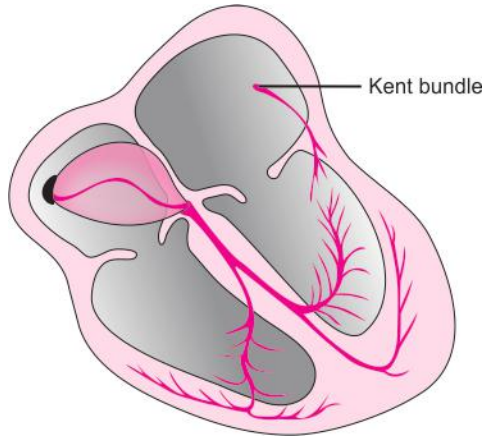
**Fig. 8.32:** Delta waves

“What you see depends on what you’re looking for.”

—Bob Marley

### Pathology

Patient with WPW have a tract that bypasses AV node which is known as Kent bundle. In this condition, when impulse travels down through the atria it reaches the Kent bundle and AV node simultaneously. The impulse travels down the AV node and is met by normal physiological block. The impulse also travels down the Kent bundle, does not meet any block and so begins to spread through the ventricular myocardium. This progression is slow and gives a wide pattern on the ECG.



**Fig. 8.33:** WPW have a tract that bypasses AV node (Kent bundle)

### Clinical Features

1. Asymptomatic
2. Palpitations
3. Supraventricular tachycardia (most common) due to re-entry circuit.
4. Atrial fibrillation.
5. Syncope.
6. Sudden death.

### Concept

1. Short PR interval is due to rapid conduction of impulse from the atria to the ventricles through the accessory pathway causing early ventricular depolarization of a part of ventricle.
2. This early ventricular depolarization gives rise to slow upstroke called delta wave. Rest of the QRS complex is formed due to depolarization of the remaining ventricular depolarization.

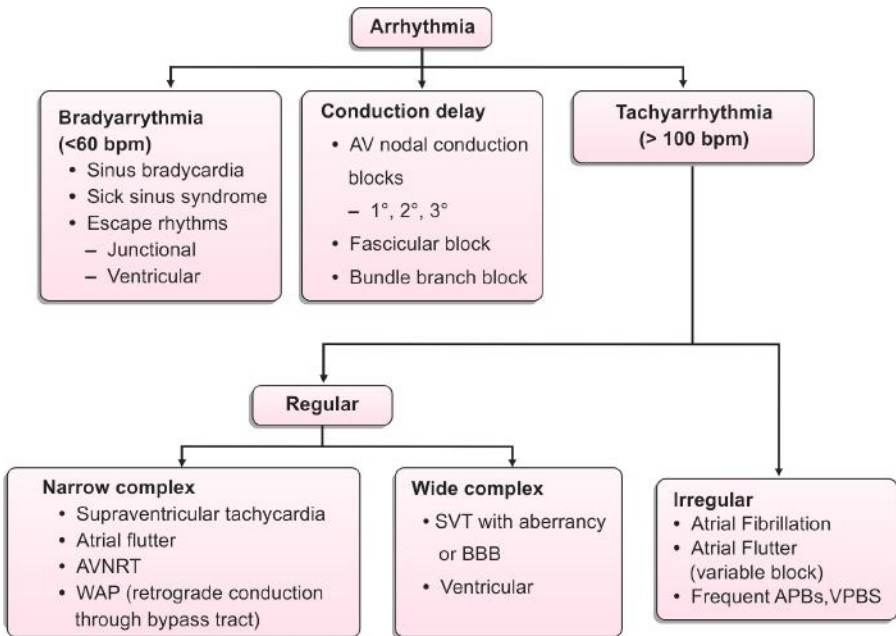
*“Victory belongs to the most persevering.”*

*—Napoleon Bonaparte*



# Systematic Interpretation of Arrhythmias

**Flow Chart 9.1:** Systematic approach to arrhythmia



*“Better to light one small candle than to curse the darkness.”*

—Chinese Proverb

## P WAVE

Wide P wave:

1. Left atrial hypertrophy or enlargement

Tall P wave:

1. Right atrial hypertrophy or enlargement

Small P wave:

1. High nodal rhythm
2. High nodal ectopic
3. Atrial tachycardia
4. Atrial ectopics

Inverted P wave:

1. Nodal rhythm with retrograde conduction
2. Low atrial and high nodal ectopic beats
3. Dextrocardia

Variable P wave morphology:

1. Wandering pacemaker

Multiple P waves:

1. Third degree heart block

Absent P wave:

1. Atrial fibrillation
2. Atrial flutter
3. Mid nodal rhythm
4. Ventricular ectopic
5. Ventricular tachycardia
6. Supraventricular tachycardia
7. Idoventricular rhythm
8. Hyperkalemia

## P-R INTERVAL

Prolonged P-R interval:

1. First degree heart block

*“You have to learn the rules of the game. And then you have to play better than anyone else.”*

*—Albert Einstein*



Short P-R interval:

1. WPW syndrome. Here delta wave is present.
2. Lown-Ganong-Levin (LGL) syndrome. Here delta wave is absent.
3. Nodal rhythm
4. High nodal ectopic

Variable P-R interval:

1. Mobitz type I heart block (Wenckebach's phenomenon)

## Q WAVE

---

Pathological Q wave:

1. MI
2. Left ventricular hypertrophy (in V1, V2 and V3)
3. LBBB
4. Pulmonary embolism (only in lead III)
5. WPW syndrome (in lead III and aVF)

## R WAVE

---

Tall R wave in V1:

1. Right ventricular hypertrophy
2. True posterior MI
3. WPW syndrome
4. RBBB
5. Dextrocardia

Small R wave:

1. Improper ECG standardization
2. Obesity
3. Emphysema
4. Pericardial effusion
5. Hypothyroidism
6. Hypothermia

Poor progression of R wave:

1. Anterior or anteroseptal MI
2. LBBB
3. Dextrocardia
4. Left sided massive pleural effusion
5. COPD
6. Left sided pneumothorax
7. Marked clockwise rotation of heart

## QRS COMPLEX

---

High voltage QRS:

1. Improper standardization

*"Learn from yesterday, live for today, hope for tomorrow. The important thing is not to stop questioning."*  
—Albert Einstein

2. Thin chest wall
3. Ventricular hypertrophy
4. WPW syndrome

Low voltage QRS (less than 5 mm in leads I, II, III and <10 mm in chest leads):

1. Improper standardization
2. Obesity or thick chest wall
3. Pericardial effusion
4. Emphysema
5. Chronic constrictive pericarditis
6. Hypothyroidism
7. Hypothermia

Wide QRS:

1. LBBB and RBBB
2. Ventricular ectopic
3. Ventricular tachycardia
4. Idioventricular rhythm
5. WPW syndrome
6. Hyperkalemia

Change in shape of QRS:

1. RBBB
2. LBBB
3. Ventricular tachycardia
4. Ventricular fibrillation
5. WPW syndrome

Variable QRS:

1. Torsades de pointes
2. Multifocal ventricular ectopics
3. Ventricular fibrillation

## ST SEGMENT

ST elevation:

1. Acute myocardial infarction
2. Acute pericarditis
3. Prinzmetal's angina (Non-infarction transmural ischemia)
4. Normal variant (Early repolarization pattern)
5. Ventricular aneurysm

ST depression:

1. Acute MI
2. Angina pectoris
3. Ventricular hypertrophy with strain
4. Acute true posterior MI (in V1 and V2)
5. Digoxin toxicity

*"Patience, persistence and perspiration make an unbeatable combination for success."*  
—Napoleon Hill

## T WAVE

Tall T wave:

1. Hyperkalemia
2. Acute MI
3. Acute true posterior MI (in V1 and V2)

Small T wave:

1. Hypokalemia
2. Hypothyroidism
3. Pericardial effusion

T inversion:

1. MI
2. Myocardial ischemia
3. Subendocardial MI
4. Ventricular ectopic
5. Ventricular hypertrophy with strain
6. Acute pericarditis

## U WAVE

Prominent U wave:

1. Normally present
2. Hyperkalemia
3. Bradycardia
4. Ventricular hypertrophy
5. Hypercalcemia
6. Hyperthyroidism

## Q-T INTERVAL

Short QT interval:

1. Tachycardia
2. Hyperthermia
3. Hypercalcemia
4. Digoxin effect
5. Vagal stimulation

Long QT interval:

1. Bradycardia
2. Hypocalcemia
3. Acute MI
4. Acute myocarditis
5. Cerebrovascular accident
6. Hypertrophic cardiomyopathy
7. Hypothermia
8. Hereditary syndrome
  - a. Jervell, Lange-Nielsen syndrome (congenital deafness, syncope and sudden death)
  - b. Romano-Ward syndrome (syncope and sudden death)

*"You were not born a winner, and you were not born a loser. You are what you make yourself be."*

*—Lou Holtz*





# Bibliography

1. Abid R Assali, et al. ECG criteria for predicting the culprit artery in inferior wall acute myocardial infarction. *American Journal of Cardiology*. 1999;84:87-9.
2. ABM Abdhullah. ECG in medical practice. 3rd edition, 2010.
3. Agustin Castellanos, Alberto Interian, Robert J Myerburg. *Hursts. The Heart*. 11th edition, 2004;(1):Chapters 27 to 34.
4. Baber, Nikdic, O'Connon. *Practical cardiology*. 2nd edition, 2008.
5. Braunwald's heart disease: A textbook of cardiovascular medicine. 7th edition, Philadelphia, WB Saunders, 2004.
6. *Clinical cardiac electrophysiology, techniques and interpretation*. 3rd edition, Philadelphia, 2002.
7. David M Mirris, Ary L Gold Berger. Braunwald's heart disease: A textbook of cardiovascular medicine. 8th edition, Philadelphia. Chapter 12, *Electrocardiography*. 2008;149-90.
8. Diagnosis of acute myocardial infarction in angiographically documented occluded infarct vessel limitations of ST segment elevation in standard and extended ECG leads. *Chest* 2001;120(5):1540-5.
9. DJ Rowlands. *Oxford textbook of medicine*. *Electrocardiography*. Chapter 15.3.2, 4th edition, 2003(2),859-78.
10. Domein J Engelen, et al. Value of ECG in localization of occlusion site in LAD coronary artery in acute anterior MI. *J Am Coll Cardiol*. 1999;34:389-5.
11. Ganong's review of medical physiology. *Cardiovascular physiology*. 23rd edition, 2010;(6):489-569.
12. Gold Berger, Ary L Gold Berger: *Clinical electrocardiography (a simplified approach)*, 7th edition, 2008.
13. *Harrison's principles of internal medicine*. Disorders of CVS. 17th edition, 2008;1(9):1365-442.
14. Itzak Herz, et al. New ECG criteria for prediction of right and left coronary artery as culprit in IWMI. *AMJ Cardiol*. 1997;80:1343-5.
15. John R Hampton. *150 ECG Problems*. 3rd edition. Elsevier, 2008.
16. Leo Schamroth. *An introduction to electrocardiography*. 7th edition, 1990.
17. Malika Arbane, et al. Prediction of site of total occlusion in the left anterior descending coronary artery using admission ECG in anterior wall acute myocardial infarction. *American Journal of Cardiology*. 2000;85:487-91.
18. Mariotts. *Practical electrocardiography*. Galen S Wagree.10th edition, 2001.
19. Mark E Josephon. *Mayo clinic cardiology review*. 2nd edition, Philadelphia, 2000.
20. Peter J Zimebaum, et al. Use of ECG in acute myocardial infarction. *NEJM*. 2003;348:933-40.
21. Radhakrishnan Nair, D Luke, et al. ECG discrimination between right and left circumflex coronary artery occlusion in patients with acute IWMI. *Chest*. July 2002:122.
22. Raghavendra R Baliga, Bim A Eagle. *Practical cardiology*. 2nd edition, 2008.
23. Tomas B Garcia, Neil E Holtz. *12-lead ECG: The art of interpretation*.
24. *Web based ECG Resources*.
25. Y Birnbaeum, et al. ECG in ST elevation acute myocardial infarction correlation with coronary anatomy and prognosis. *Postgrad Medical Journal*. 2003;79:490-504.

*"Action is the real measure of intelligence."*

*—Napoleon Hill*



# Index

Page numbers followed by *f* refer to figure

## A

- Abnormalities of rhythm 56
- Acute
  - anterior MI 58
  - inferior wall MI 58
  - myocardial infarction 26, 44, 62, 73, 74
  - myocarditis 74
  - onset MI 28
  - pericarditis 73, 74
  - true posterior MI 73, 74
- Anemia 58
- Angina pectoris 73
- Anterolateral wall MI 30, 30*f*
- Anteroseptal MI 72
- Aortic stenosis 23, 39
- Arrhythmias 48
- Atrial
  - cells 3
  - depolarization 4
  - ectopics 71
  - fibrillation 48, 58, 61, 61*f*, 64, 71
  - flutter 48, 58, 63, 63*f*, 64, 71
  - origin of premature beat 53*f*
  - premature contraction 48
  - rhythm 58, 64
  - septal defect 23
  - tachycardia 60*f*, 64, 71
- Atrioventricular node 3
- AV
  - nodal re-entry tachycardia 60*f*
  - node 3, 55
  - re-entry tachycardia 61*f*

## B

- Baseline vibration 61
- Basics of ECG 6
- Bradycardia 74
- Bronchial asthma 23
- Bundle
  - blocks 49
  - branch block 41
  - of His 3, 4, 55

## C

- Causes of irregular rhythm 19
- Cerebrovascular accident 74
- Chronic
  - constrictive pericarditis 73
  - cor pulmonale 40, 44
- Coarctation of aorta 39
- Conduction
  - in sinus rhythm 59*f*
  - of impulse in left bundle branch block 45*f*
- Congenital deafness 74

## D

- Delta waves 67*f*
- Depolarization of
  - antero-septal region of ventricular myocardium 4
  - major portion of ventricular myocardium 4
- Detection of culprit coronary vessel 37
- Dextrocardia 71, 72
- Digoxin toxicity 73
- Disorders of impulse
  - conduction 48
  - formation 48
- Disturbance of
  - atria 48
  - atrioventricular node 48
  - sinus mechanism 48
  - ventricles 48

## E

- ECG of
  - left
    - bundle branch block 44*f*
    - ventricular hypertrophy 38*f*
  - right
    - bundle branch block 42*f*
    - ventricular hypertrophy 40*f*
  - sinus
    - arrhythmia 57*f*



bradycardia 57*f*  
tachycardia 58*f*  
supraventricular premature beat 51*f*  
ventricular premature beat 52*f*  
Ectopic beats 49  
Electrocardiography 6  
Emphysema 23, 72, 73  
Epigastric pulsation 40

## **F**

Fallot's tetralogy 40  
Fever 58  
First degree  
  AV block 24*f*  
  heart block 17, 71

## **H**

Heaving apex beat 39  
Hereditary syndrome 74  
High nodal  
  ectopic 71  
  rhythm 54*f*, 71  
Hypercalcemia 74  
Hyperkalemia 71, 73, 74  
Hypertension 62, 63  
Hyperthermia 74  
Hyperthyroidism 74  
Hypertrophic cardiomyopathy 39, 74  
Hypertrophy 38  
Hypocalcemia 74  
Hypokalemia 74  
Hypothermia 58, 72, 73, 74  
Hypothyroidism 58, 72, 73, 74

## **I**

Idioventricular rhythm 66, 67*f*, 71, 73  
Infarction 28, 28*f*  
Inferior wall MI 30, 30*f*  
Interpolated ventricular ectopics 52  
Intra-atrial conduction delay 23  
Irregular R-R interval 19*f*  
Irregularly irregular rhythm 61

## **J**

Junctional  
  ectopics 48  
  escape beat 56*f*  
  rhythm 48, 53  
  tachycardia 48

## **K**

Kent bundle 68*f*

## **L**

Labeled normal ECG patterns 16*f*  
Leads 8*f*, 9  
Left  
  anterior  
    descending artery infarction 34*f*-36*f*  
    hemiblock 46, 46*f*, 49  
  atrial  
    enlargement 21  
    hypertrophy 71  
  axis deviation 17, 20*f*, 46  
  bundle branch 3  
    block 17, 44, 45*f*, 49  
  circumflex artery 37*f*  
  posterior hemiblock 46, 46*f*, 49  
  sided pneumothorax 72  
  ventricle quadrant 33*f*  
  ventricular  
    hypertrophy 17, 38  
    strain pattern 39

## **Low**

atrial and high nodal ectopic beats 71  
nodal rhythm 54*f*

## **M**

Mid nodal rhythm 54*f*, 71

## **Mitral**

regurgitation 23  
stenosis 23

Mobitz type II block 25, 25*f*, 48

## **Multifocal**

ectopics 52  
ventricular ectopics 73

Multiple re-entrant wavelets 62*f*

## **Myocardial**

cells 4  
ischemia 74

## **N**

### **Nodal**

blocks 48  
origin of premature beat 53*f*  
rhythm 53, 71

Non-infarction transmural ischemia 73

Non-ST elevation myocardial infarction  
32, 32*f*

**Normal**

## ECG

morphology 13

pattern 15, 15*f*

QRS configuration complex 52

R wave progression in chest leads 16, 16*f*spread of electrical activity in heart 4  
wave tracing 28**O**

Obesity 72, 73

**P****P**mitrale 21, 22*f*pulmonale 22*f*wave morphology 20, 21*f*

Paroxysmal supraventricular tachycardia 48, 59

Parts of ECG strip 14*f*

Pathology of acute myocardial infarction 26

Physiology of conduction system of heart 3

Placement of

chest leads 12, 12*f*

leads 11

limb leads 12, 12*f*Posterior descending artery involvement 36*f*Premature beats 49, 49*f*

Prinzmetal's angina 73

Pulmonary

embolism 23, 44

hypertension 40

stenosis 40

Pulmonic valve stenosis 23

Purkinje

cells 4

fibers 3, 55

**Q**

Q wave 72

## QRS

complex 15, 72

wave morphology 26

Quadrant and zones of left ventricle 34*f***R**

Raised intracranial pressure 58

Rates of pacemakers 3

**Right**

atrial hypertrophy 71

axis deviation 17, 20*f*, 46

bundle branch 3

block 17, 41, 43*f*, 49

ventricular

hypertrophy 17, 40, 44, 72

strain pattern 40

Romano-Ward syndrome 74

R-R interval 18*f*, 19*f***S**

## SA

nodal parts 53*f*

node block 54

Second degree

AV block 25

block 48

heart block 17

Shock 58

Sick sinus syndrome 58

Sinoatrial

blocks 48

node 3

Sinus

arrest with atrial escape beat 55*f*

arrhythmia 48, 56

bradycardia 48, 56, 57

tachycardia 48, 56, 58

ST segment 26*f*

Subendocardial MI 74

Supraventricular

premature beat 50, 52

tachycardia 71

SV tachycardia 58

Systematic

interpretation of

arrhythmias 70

ECG 17

hypertension 39

**T**

Tachycardia 74

Tetralogy of Fallot 23

Thick chest wall 73

Thin chest wall 73

Third degree

AV block 25, 25*f*

block 48

heart block 17, 71

Thyrotoxicosis 58, 62, 63

Torsades de pointes 65, 66*f*, 73

## U

Unifocal ectopics 52

## V

Vagal stimulation 74

Ventricular

aneurysm 73

bigeminy 52

ectopic 48, 71, 73, 74

escape beat 56*f*

fibrillation 48, 65, 66*f*, 67, 73

hypertrophy 73, 74

premature beat 51

rhythm 64

tachycardia 48, 64, 65*f*, 67, 71, 73

## W

Wandering pacemaker 71

Wenckebach

block 48

phenomena 25

Wolf-Parkinson-White syndrome 67, 72, 73

## Z

Zones of left ventricle 34*f*